RD
651
U58
fasc.7
1973

NIH LIBRARY

TUMORS of the ESOPHAGUS and STOMACH

by

SI-CHUN MING, M.D.

AFIP

TUMORS of the ESOPHAGUS and STOMACH

ATLAS OF TUMOR PATHOLOGY

Second Series

Fascicle 7

TUMORS OF THE ESOPHAGUS AND STOMACH

by

SI-CHUN MING, M.D.
Associate Professor of Pathology
University of Maryland School of Medicine
Baltimore, Maryland 21201

Present Address
Professor of Pathology
Temple University Medical School
Philadelphia, Pennsylvania 19140

Published by the
ARMED FORCES INSTITUTE OF PATHOLOGY
Washington, D.C.

Under the Auspices of
UNIVERSITIES ASSOCIATED FOR RESEARCH AND EDUCATION IN PATHOLOGY, INC.
Bethesda, Maryland
1973

Accepted for Publication
1971

For sale by the American Registry of Pathology
Armed Forces Institute of Pathology
Washington, D C 20306

ATLAS OF TUMOR PATHOLOGY

Sponsored and Supported by

AMERICAN CANCER SOCIETY

NATIONAL CANCER INSTITUTE, NATIONAL INSTITUTES OF HEALTH

U. S. PUBLIC HEALTH SERVICE

and

ARMED FORCES INSTITUTE OF PATHOLOGY

EDITOR

HARLAN I. FIRMINGER, M.D.

Professor, Department of Pathology

University of Maryland School of Medicine

Baltimore, Maryland 21201

and

Scientist Associate, Universities Associated for

Research and Education in Pathology, Inc.

9650 Rockville Pike

Bethesda, Maryland 20014

EDITORIAL ADVISORY COMMITTEE

Lauren V. Ackerman, M.D.	Washington University School of Medicine St. Louis, Missouri
David G. Freiman, M.D.	Harvard Medical School Boston, Massachusetts
John K. Frost, M.D.	The Johns Hopkins School of Medicine Baltimore, Maryland
James C. Harkin, M.D.	Tulane University School of Medicine New Orleans, Louisiana
Dante G. Scarpelli, M.D.	University of Kansas Medical Center Kansas City, Kansas
Robert E. Scully, M.D.	The Massachusetts General Hospital Boston, Massachusetts
Philippe Shubik, M.D.	University of Nebraska College of Medicine Omaha, Nebraska
Harlan J. Spjut, M.D.	Baylor University College of Medicine Houston, Texas

EDITOR'S NOTE

The Atlas of Tumor Pathology was originated by the Committee on Pathology of the National Academy of Sciences—National Research Council in 1947. The form of the Atlas became the brainchild of the Subcommittee on Oncology and was shepherded by a succession of editors. It was supported by a long list of agencies; many of the illustrations were made by the Medical Illustration Service of the Armed Forces Institute of Pathology; the type was set by the Government Printing Office; and the final printing was made by the press at the Armed Forces Institute of Pathology. The American Registry of Pathology purchased the fascicles from the Government Printing Office and sold them at cost, plus a small handling and shipping charge. Over a period of 20 years, 15,000 copies each of 40 fascicles were produced. They provided a system of nomenclature and set standards for histologic diagnosis which received worldwide acclaim. Private contributions by almost 600 pathologists helped to finance the compilation of an index by The Williams & Wilkins Company to complete the original Atlas.

Following the preparation of the final fascicle of the first Atlas, the National Academy of Sciences—National Research Council handed over the task of further pursuit of the project to Universities Associated for Research and Education in Pathology, Inc. Grant support for a second series was generously made available by both the National Cancer Institute and the American Cancer Society. The Armed Forces Institute of Pathology has expanded and improved its press facilities to provide for a more rapid and efficient production of the new series. A new Editor and Editorial Advisory Committee were appointed, and the solicitation and preparation of manuscripts continues.

This second series of the Atlas of Tumor Pathology is not intended as a second edition of the first Atlas and, in general, there will be variation in authorship. The basic purpose remains unchanged in providing an Atlas setting standards of diagnosis and terminology. Throughout this new series, the term chosen by the Committee on Tumor Nomenclature of the International Union Against Cancer is shown by an asterisk if it corresponds to the author's choice, or as a synonym in bold print if it differs from the author's heading. Hematoxylin and eosin stained sections still represent the keystone of histologic diagnosis; therefore, most of the photomicrographs will be of sections stained by this technic, and only sections prepared by other technics will be specifically designated in the legends. It is hoped that in many of the new series a broader perspective of tumors may be offered by the inclusion of special stains, histochemical illustrations, electron micrographs, data on biologic behavior, and other pertinent information for better understanding of the disease.

The format of the new series is changed in order to allow better correlation of the illustrations with the text, and a more substantial cover is provided. An index will be included in each fascicle.

It is the hope of the Editor, the Editorial Advisory Committee, and the Sponsors that these changes will be welcomed by the readers. Constructive criticisms and suggestions will be appreciated.

Harlan I. Firminger, M D.

ACKNOWLEDGMENTS

The author is indebted to Dr. Harlan I. Firminger, Editor of the Atlas of Tumor Pathology, whose encouragement and critical comments have been instrumental for the completion of this fascicle.

Most of the materials included in the fascicle are from the files of the Department of Pathology, University of Maryland Hospital, Baltimore, Maryland. The cytologic and radiologic illustrations were provided respectively by Dr. Genovefa Hendrickson and Dr. Robert H. Armstrong, Jr. of the University of Maryland Hospital, to whom the author is grateful.

Gratitude is also due to Dr. David G. Freiman and Dr. Harvey Goldman of Beth Israel Hospital, Boston, Massachusetts, and Dr. Benjamin Castleman, Dr. Austin L. Vickery, Jr., and Dr. Robert E. Scully of The Massachusetts General Hospital, Boston, Massachusetts for contribution of many materials from their respective hospitals.

The photographs are mostly the efforts of Mr. Thomas M. Stevenson, Director of Illustrative Services, University of Maryland Hospital.

The author wishes to thank Dr. Raffaele Lattes of Columbia University College of Physicians and Surgeons, New York, New York and members of the Editorial Advisory Committee for their many valuable critical comments and suggestions, and the staff of the Editorial Office of the Atlas of Tumor Pathology for their beneficial assistance.

Grateful acknowledgment is due to the following other contributors of materials and illustrations:

Dr. D. L. Alcott
Los Gatos, California

Dr. R. C. Boylan
San Jose, California

Dr. H. T. Enterline
Philadelphia, Pennsylvania

Dr. R. J. Furie
Frederick, Maryland

Dr. I. W. Grossman
Brattleboro, Vermont

Dr. G. H. Humphreys, II
New York, New York

Dr. Saul Kay
Richmond, Virginia

Dr. J. M. Kissane
St. Louis, Missouri

Dr. B. W. Lyne
St. Paul, Minnesota

Dr. J. A. Lyon
Baltimore, Maryland

Dr. A. F. McBride, Jr.
Paterson, New Jersey

Dr. A. T. Meyer
New Orleans, Louisiana

Dr. A. P. Monaco
Boston, Massachusetts

Dr. J. F. Perry
St. Paul, Minnesota

Dr. Melvin Reuber
Baltimore, Maryland

Dr. K. C. Snell
Bethesda, Maryland

Dr. Takashi Sugimura
Tokyo, Japan

Dr. R. J. Thomas
Frederick, Maryland

Dr. R. A. Welsh
New Orleans, Louisiana

Dr. R. B. Wright
Baltimore, Maryland

Permission to use copyrighted material has been granted by:

American Cancer Society, Inc.:

Cancer

4:726–736, 1951. For our figure 238

15:456–467, 1962. For our figure 107

18:721–726, 1965. For our figure 115

American Medical Association:

Arch. Path. 87:71–81, 1969. For our figure 205

Charles C Thomas, Publisher:

Amer. J. Roentgen. 61:461–469, 1949. For our figure 64

Harper & Row, Publishers, Inc.–Hoeber Medical Division:

Amer. J. Dig. Dis. 8:439–443, 1963. For our figure 37

Lab. Invest. 18:203–210, 1968. For our figures 178, 179, 182

Japanese Cancer Association and Maruzen Co., Ltd.

Gann Monograph 8:157–196, 1969. For our figures 133, 134.

J. F. Bergmann Verlagsbuchhandlung:

Z. Krebsforsch. 49:86–108, 1939. For our figure 54

The Massachusetts Medical Society:

New Eng. J. Med. 270:736–742, 1964. For our figure 104

World Health Organization:

WHO Epidem. Vital Statist. Rep. 18:261–288, 1965. For our figures 11, 55, 129, 130

SI-CHUN MING, M.D.

TUMORS OF THE ESOPHAGUS AND STOMACH

CONTENTS

Page No

TUMORS OF THE ESOPHAGUS . . . 11
INTRODUCTION . . . 11
Embryology, Congenital and Acquired Abnormalities . . . 11
Anatomy . . . 12
General Remarks on Benign Tumors . . . 16
Intraluminal Tumors . . . 16
Intramural Tumors . . . 16
Extramural Tumors . . . 16
TUMORS AND TUMOR-LIKE LESIONS OF ENTODERMAL ORIGIN . . . 19
Cysts . . . 19
Inclusion Cyst . . . 19
Retention Cyst (Mucocele) . . . 19
Cyst of Developmental Origin . . . 20
Benign Epithelial Tumors . . . 22
Squamous Cell Papilloma . . . 22
Adenoma . . . 22
Malignant Epithelial Tumors . . . 23
Associated Conditions . . . 26
Hiatus Hernia . . . 26
Esophagus Lined by Columnar Epithelium . . . 26
Benign Stricture . . . 27
Achalasia . . . 27
Pulsion Diverticulum . . . 27
Tylosis and Plummer-Vinson Syndrome . . . 27
Squamous Cell Carcinoma . . . 30
Fungating Carcinoma – Verrucous Type . . . 30
Ulcerative Carcinoma . . . 34
Infiltrating Carcinoma . . . 34
Adenocarcinoma . . . 44
Adenoacanthoma or Mucoepidermoid Carcinoma . . . 45
Cylindroma or Adenoid-Cystic Carcinoma . . . 47
Choriocarcinoma . . . 47
Carcinoma at the Esophagogastric Junction . . . 47
Multiple Carcinomas . . . 51
Carcinoid . . . 62
Malignant Melanoma . . . 63
Carcinoma Involving the Esophagus Secondarily . . . 63
TUMORS AND TUMOR-LIKE LESIONS OF MESODERMAL ORIGIN . . . 65
Tumors of Muscular Tissue . . . 65

Page No.
Leiomyoma 65
Leiomyosarcoma 67
Rhabdomyosarcoma 67
Tumors of Fibrous and Adipose Tissue 68
Fibrous Polyp 68
Fibroma and Lipoma 68
Fibrosarcoma 72
Tumors of Vascular Tissue 72
Hemangioma 72
Lymphangioma 72
Glomus Tumor 73
Kaposi's Disease 73
Tumors of Nervous Tissue 73
Neurofibroma 73
Granular Cell Tumor 73
Tumors of Osteocartilaginous Tissue 75
Osteochondroma 75
Lymphoma 75
Concomitant Mesodermal Tumor and Carcinoma 75
Carcinosarcoma and Pseudosarcoma 76
Plate I, p. 71
TUMORS OF THE STOMACH 81
INTRODUCTION 81
Chronic Atrophic Gastritis 81
Chronic Hypertrophic Gastritis 81
Embryology 83
Anatomy 83
Surface and Foveolar Cells 87
Intestinal Metaplasia 90
General Remarks on Benign Tumors 99
Plate II, p. 97
Inflammatory Lesions Simulating Tumors 102
Specific Infections 102
Syphilis 102
Tuberculosis 102
Eosinophilic Gastritis (Eosinophilic Granuloma) 102
Allergic Granulomatosis 104
Inflammatory Fibroid Polyp 105
Granulomatous Gastritis 109
Benign Lymphoid Hyperplasia (Pseudolymphoma) 110
TUMORS AND TUMOR-LIKE LESIONS OF ENTODERMAL ORIGIN 115
Hyperplastic Gastropathy 115
Zollinger-Ellison Syndrome 116

Page No.
Tumor-like Lesions and Cysts of Developmental Origin . . . 120
Heterotopic Tissue . . . 120
Heterotopic Pancreatic Tissue . . . 120
Brunner's Glands . . . 120
Adenomyoma . . . 122
Duplication Cyst . . . 123
Benign Epithelial Polyps . . . 124
Hyperplastic Adenomatous Polyp . . . 125
Papillary Adenoma (Villous Adenoma) . . . 131
Familial Polyposis . . . 138
Hamartomatous Polyp . . . 139
Peutz-Jeghers Syndrome . . . 139
Heterotopic Adenomatous Polyp . . . 141
Heterotopic Pancreas . . . 141
Adenoma of Brunner's Glands . . . 141
Mucosal Nodule . . . 142
Relationship of Epithelial Polyps to Carcinoma . . . 142
Malignant Epithelial Tumors . . . 144
Adenocarcinoma . . . 144
Associated Lesions . . . 151
Mucosal Atrophy and Intestinal Metaplasia . . . 151
Mucosal Hyperplasia . . . 153
Gastric Ulcer . . . 155
Superficial Carcinoma . . . 162
Polypoid Carcinoma . . . 164
Ulcerated Infiltrative Carcinoma . . . 167
Fungating Carcinoma . . . 172
Diffusely Infiltrative Carcinoma . . . 174
Plate III, p. 189
Plate IV, p. 195
Adenoacanthoma and Squamous Cell Carcinoma . . . 206
Chorionepithelioma . . . 207
Multiple and Recurrent Carcinomas . . . 208
Carcinoid . . . 209
TUMORS AND TUMOR-LIKE LESIONS OF MESODERMAL ORIGIN . . . 215
Tumors of Muscular Tissue . . . 215
Leiomyoma . . . 215
Leiomyoblastoma . . . 219
Leiomyosarcoma . . . 224
Rhabdomyoma and Rhabdomyosarcoma . . . 229
Tumors of Lymphoid Tissue . . . 231
Malignant Lymphoma . . . 231
Plate V, p. 230

Page No

Plasmacytoma 239
Tumors of Vascular Tissue 240
Hemangioma 240
Lymphangioma 240
Glomus Tumor 241
Plate VI, p. 244
Hemangiopericytoma 245
Kaposi's Disease 245
Tumors and Tumor-like Lesions of Adipose Tissue 246
Lipoma 246
Lipoblastoma 246
Liposarcoma 248
Xanthoma 248
Histiocytoma or Reticuloma 248
Tumors of Nervous Tissue 248
Neuromas 248
Neurofibromatosis 248
Neurilemomas or Schwannomas 248
Ganglioneuroma and Paraganglioma 248
Ganglioneuroblastoma 248
Granular Cell Tumor (Myoblastoma or Schwannoma) 248
Tumors of Fibrous Tissue 249
Myxofibroma 249
Fibroma 249
Fibrosarcoma 249
TUMORS OF MIXED TISSUE ORIGIN 251
Teratoma 251
Carcinosarcoma and Collision Tumor 252
METASTATIC TUMORS IN THE STOMACH 253
INDEX 257

TUMORS OF THE ESOPHAGUS

INTRODUCTION

Carcinoma is the most frequent, as well as the most important, tumor in the esophagus. In an organ lined almost entirely with squamous epithelium, it is not surprising that squamous cell carcinoma is the principal type. Adenocarcinoma also occurs in the esophagus, particularly at its lower end where, on occasion, it may be difficult to determine whether the carcinoma originated in the esophagus or the stomach. The problem of its origin is compounded when a hiatus hernia or an esophagus lined with columnar epithelium is part of the abnormality. In order to more easily understand the origin of carcinoma cells, the embryologic development of esophageal epithelium is reviewed.

EMBRYOLOGY, CONGENITAL AND ACQUIRED ABNORMALITIES

During the fourth week of embryonic life, the esophagus is recognizable as a short tubular structure located between the pharynx and the more dilated caudal part of the foregut which latter is destined to become the stomach. The esophageal epithelium is composed of stratified columnar cells, among which vacuoles begin to appear during the sixth week. From the fourth to the seventh week, the esophagus lengthens rapidly due to the development of the neck organs, lung buds, and caudal movement of the stomach. At the same time, the esophagus becomes increasingly narrow, especially in the middle portion. An old contention that the lumen is occluded at this time has been disproved. The intraepithelial vacuoles are most prominent during the eighth week of development and communicate with each other and with the lumen. Their increasing coalescence is partly responsible for enlarging the lumen. The vacuoles disappear in the next two to three weeks. Ciliated cells make their appearance in the middle third of the esophagus during the tenth week and line the entire organ during the eleventh week. During the fourteenth week of embryonic life, squamous cells appear, also beginning in the middle third of the esophagus, and spread to line the entire esophagus during the seventh month. Small patches of ciliated cells may remain after birth, however, especially in the upper portion of the esophagus. Small islands of superficial glands are present in the mucosa at both the upper and the lower ends of the esophagus by the end of the third month of fetal life. They are mucus-secreting and resemble the cardiac glands of the stomach; hence, they are often referred to as cardiac or gastric glands. Parietal or chief cells are rare or absent, but they may occasionally persist after birth at both ends of the esophagus. The deep submucosal esophageal glands do not appear until the seventh month of fetal life and develop mainly during the postnatal period. During the sixth week, independent of the development of the epithelium, the mesoderm surrounding the entodermal tube differentiates into the connective tissue and muscularis layers which are continuous with those of the stomach without distinct demarcation. The lower limit of the esophagus is, therefore, generally determined by its squamocolumnar junction which is evident grossly. This junction, however, is an irregular line and its position is variable. In man it is situated above the diaphragm in 5 percent of cases and at the level of the diaphragm in 27 percent (Botha).

In most people, the squamocolumnar junction coincides with the cardiac orifice of the stomach.

In some it may extend a few millimeters below the cardiac opening. In those instances in which the columnar cells are present in a long segment of the gullet, as distinguished from the esophagus lined with squamous epithelium, the nature of the tube comes into question. Under these circumstances, four conditions have been recognized:

1. **Congenital short esophagus** due to insufficient caudal migration of the stomach. In these cases, the stomach is situated partially in the thoracic cavity, but its upper dome is covered by an attenuated diaphragm and peritoneum. The thoracic stomach may extend to the level of the tracheal bifurcation and it may be conical or even tubular in shape, resembling the esophagus. The mucosa is of the gastric type containing parietal and chief cells.

2. **Acquired short esophagus** associated with a sliding hiatus hernia. The contractile esophagus is occasionally fixed at a high level by fibrosis as a result of a hernia causing recurrent esophagitis.

3. **Retention of congenital columnar and glandular epithelium** lining the esophagus. Inadequate formation of squamous epithelium during fetal life leaves a long segment of esophagus lined with a glandular epithelium. The glands are of superficial esophageal or cardiac type.

4. **Acquired columnar or glandular epithelial lining of the esophagus resulting from overgrowth of cardiac mucosa** of the stomach into the esophagus following esophagitis. This condition usually accompanies a small hiatus hernia.

Congenital conditions are found mainly in infants and are easily recognizable during infancy. In adults, however, it is often impossible to differentiate the congenital from acquired nature of these conditions, because the neighboring landmarks such as the attenuated diaphragm and peritoneal covering are usually obliterated by chronic inflammation and fibrosis. Generally in adults, gastric tissue at the lower segment of gullet is considered to be acquired, either as a part of herniated stomach or as an overgrowth of gastric epithelium into the esophagus, because islands of squamous epithelium or submucosal esophageal glands are often found in these cases.

ANATOMY

The upper esophagus begins in the midline just below the cricoid cartilage. As it descends, it curves slightly to the left in the lower neck, but returns to its midline position as it enters the posterior mediastinum. Then it deviates again to the left and rotates, following the direction of movement of the stomach during embryonic life, so that its initial dorsal aspect turns to the left and its ventral aspect to the right. The vagus nerves rotate with the esophagus; at the lower end, the left vagus lies in front and the right vagus in back of the esophagus. The leftward shift of the esophagus that begins in the upper mediastinum places it to the left and posterior to the lower trachea, behind the left main bronchus and distal end of the aortic arch and to the right and anterior to the descending aorta. The close relationship between the esophagus and these organs accounts for their frequent involvement in esophageal disease.

Ordinarily, the esophagus is covered with stratified, nonkeratinizing, glycogenated squamous epithelium. Its undulating basal layer forms a tight junction with the papillae of the lamina propria in which few lymphatic vessels are present (fig. 1). Remnants of columnar epithelium, some ciliated, may be found in the upper or lower portions of the esophagus (fig. 2), where foci of superficial glands are often present. These glands are indistinguishable in their appearance from the cardiac glands of the stomach; their secretion enters the lumen through channels lined by a single layer of mucous cells identical with the surface epithelial cells of the stomach (fig. 3).

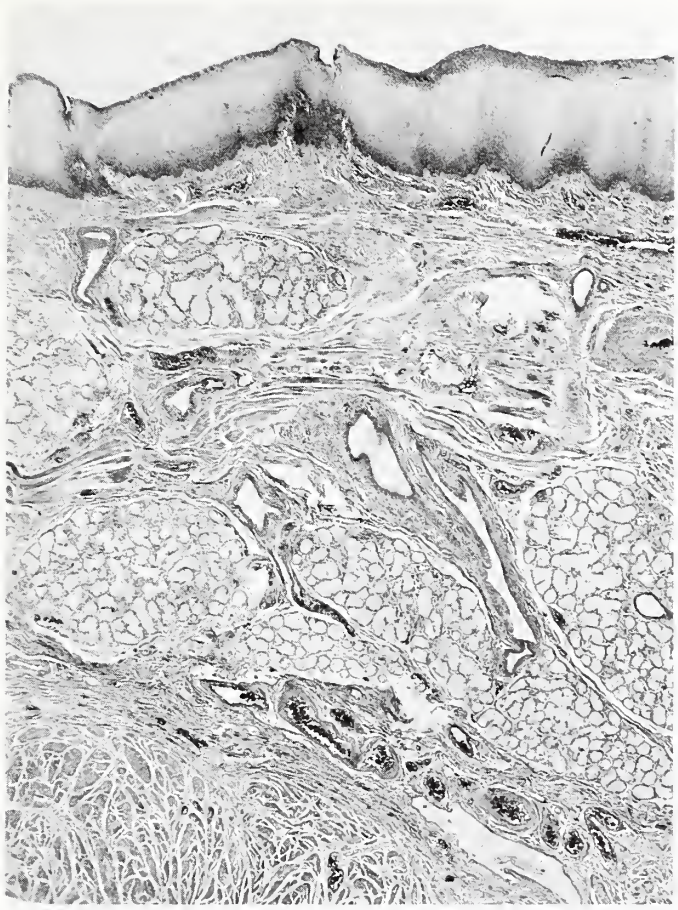

Fig 1

Fig 1

NORMAL ESOPHAGUS

The histologic appearance of normal esophagus shows stratified squamous epithelium and deep mucous glands in the submucosa × 23

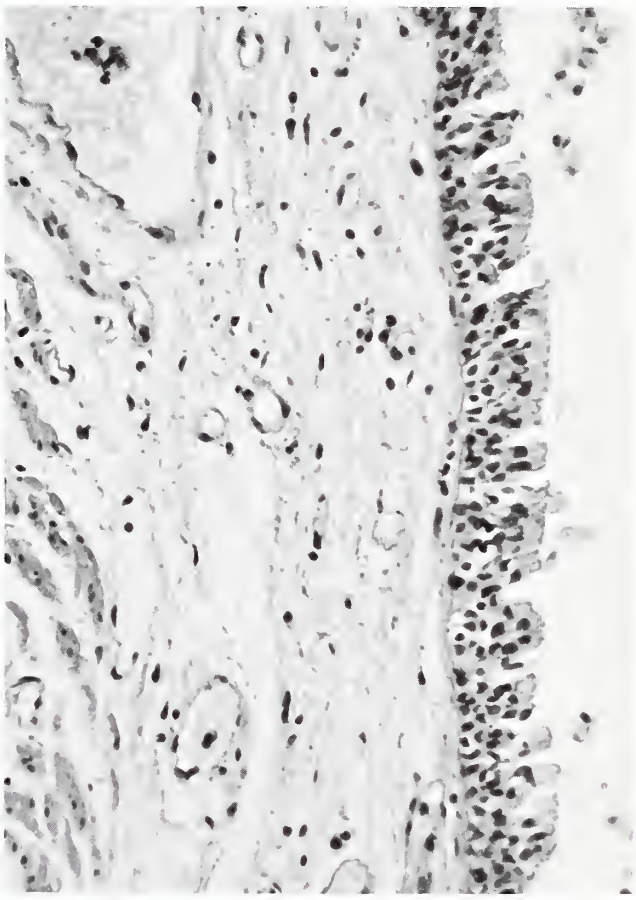

Fig 2

ESOPHAGUS WITH COLUMNAR EPITHELIUM

The area shown was found in the lower esophagus and reveals stratified columnar epithelium × 245

Fig. 3

Fig 3

ESOPHAGEAL CARDIAC GLANDS

(Figures 3 and 5 from same case)

This section is from the lower esophagus of a 46-year-old man who had squamous cell carcinoma in the adjacent area It shows mucus-secreting surface epithelium and superficial cardiac glands partly covered by squamous epithelium. Chronic inflammation is present. × 70.

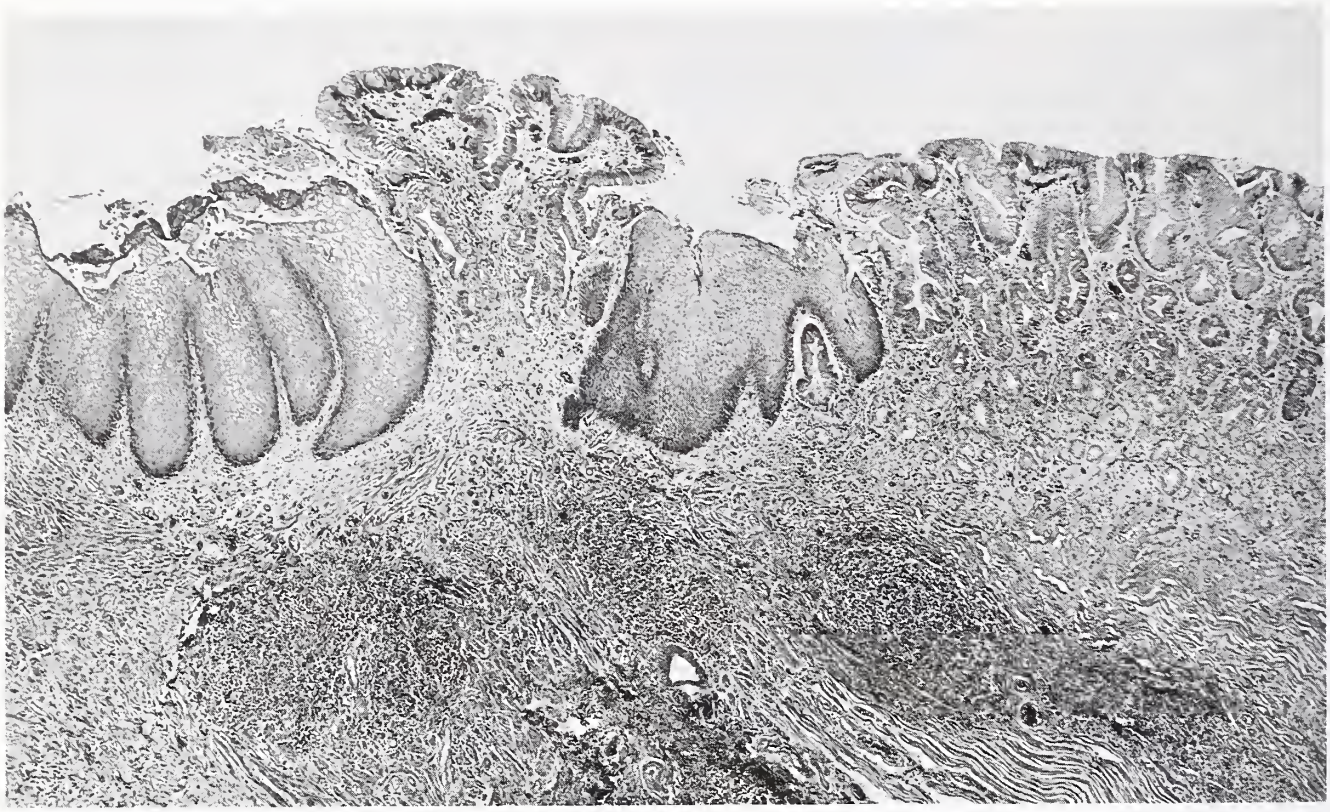

Fig 4

ESOPHAGEAL CARDIAC GLANDS WITH INTESTINAL METAPLASIA

This area in the lower esophagus shows groups of cardiac glands with intestinal metaplasia alternating with patches of squamous epithelium There is marked chronic inflammation in the submucosa × 34

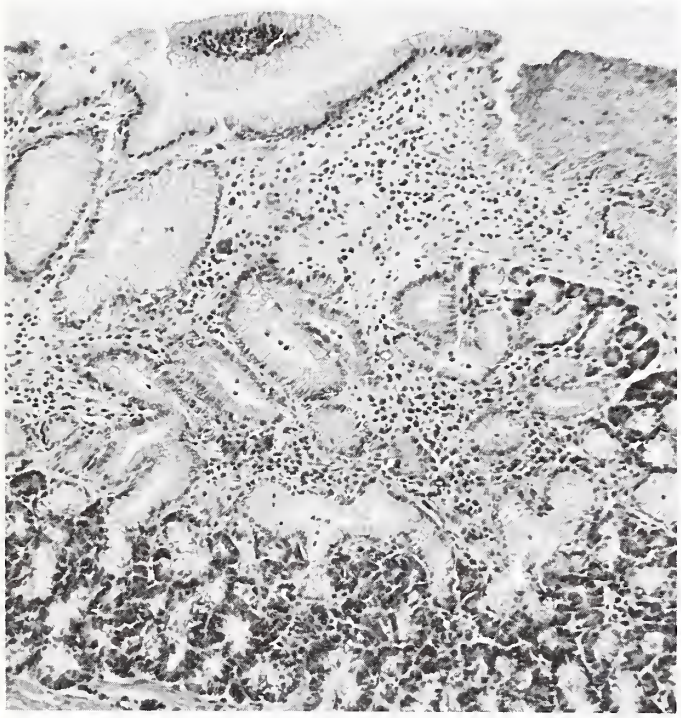

Fig 5

Fig 5

ESOPHAGEAL GLANDS WITH SEROUS CELLS

(Figures 3 and 5 from same case)

This illustrates an area near the esophagogastric junction in the same case as figure 3 The superficial glands are composed of both mucous and serous cells × 90

These glands are also capable of undergoing intestinal metaplasia (fig. 4), a common finding in the cardia of the stomach. The deep esophageal glands are located in the submucosa (fig. 1), and scatter randomly throughout the length of the esophagus, including the lower portion. The columnar cells lining the duct end abruptly as the duct reaches the squamous epithelium, and its terminal portion is bordered by squamous cells. Both the superficial and deep glands are mucus-secreting. Occasionally, serous cells may be found giving an appearance identical with minor salivary glands (fig. 5). Rarely, small patches of fundic gastric mucosa are found in the esophagus (fig. 6).

The esophagus receives arterial blood from branches of the major arteries in the neighboring area; similarly venous blood drains into the tributaries of veins of neighboring organs, including the inferior thyroid, azygous, hemiazygous, and gastric veins, thus forming a link between the systemic and portal circulation. The lymphatic vessels, which are relatively few compared with the remainder of the digestive tract, form a plexus around the esophagus and drain into the paraesophageal, deep cervical, posterior mediastinal,

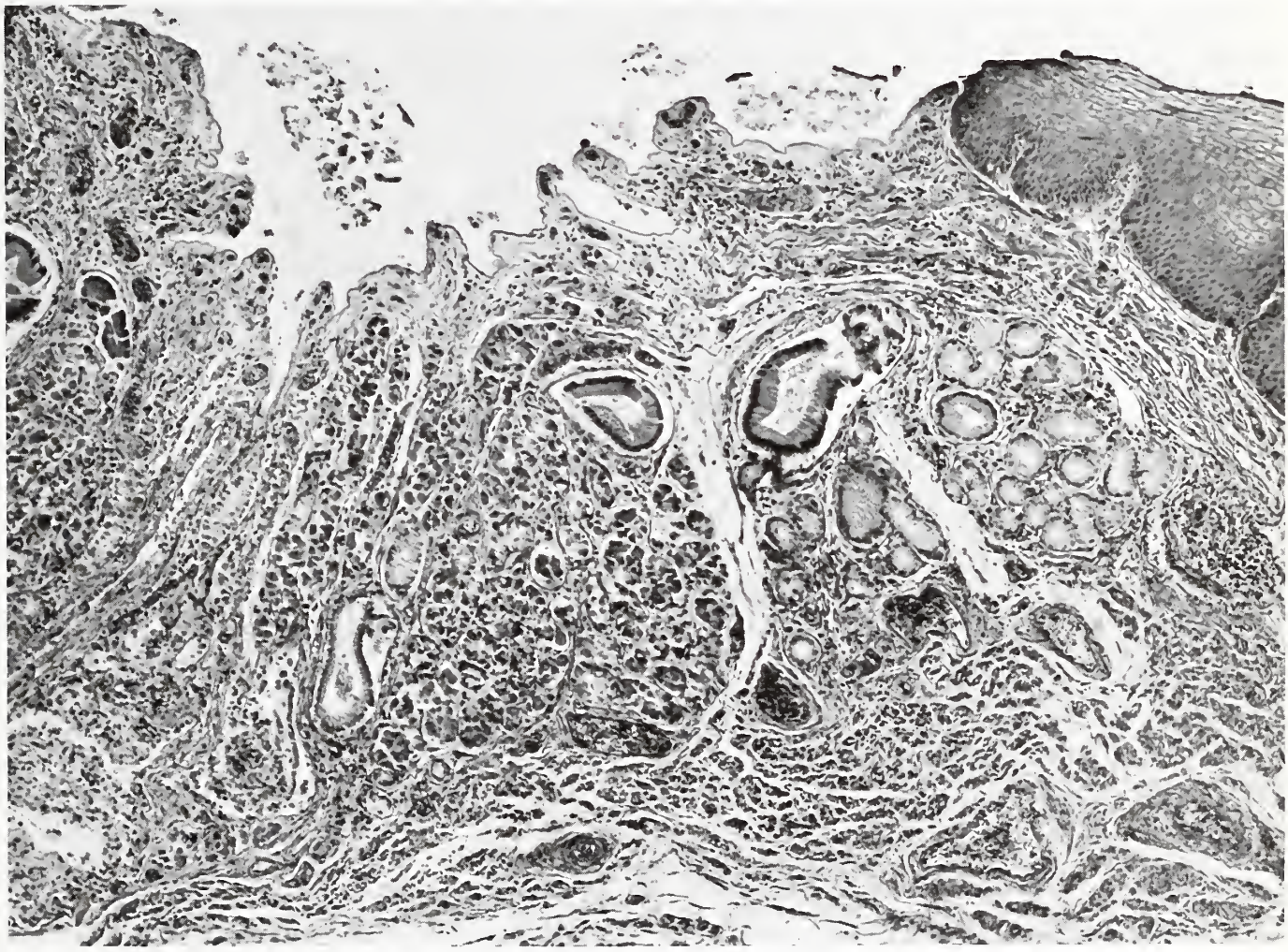

Fig. 6

ABERRANT GASTRIC MUCOSA

This aberrant gastric mucosa was found in the upper esophagus of a child. Most of the glands resemble fundic glands of the stomach with many parietal and chief cells. × 75

and subdiaphragmatic nodes. The direction of lymph flow depends upon the level at which the lymphatic vessels originate in the esophagus; that is, the lymphatics of the upper esophagus drain into the cervical nodes and those of the lower esophagus drain into the subdiaphragmatic lymph nodes.

References

Allison, P. R., and Johnstone, A. S. Oesophagus lined with gastric mucous membrane. Thorax 8:87–101, 1953.

Barrett, N. R. The lower esophagus lined by columnar epithelium. Surgery 41:881–894, 1957.

Botha, G. S. M. The gastro-esophageal region in infants; observations on the anatomy, with special reference to the closing mechanism and partial thoracic stomach. Arch. Dis. Child. 33:78–94, 1958.

——— Organogenesis and growth of the gastroesophageal region in man. Anat. Record 133:219–239, 1959.

Johns, B. A. E. Developmental changes in the oesophageal epithelium in man. J. Anat. 86:431–442, 1952.

Peters, P. M. The congenital short esophagus. Thorax 13:1–11, 1958.

Rector, L. E., and Connerley, M. L. Aberrent mucosa in the esophagus in infants and in children. Arch. Path. 31: 285–294, 1941.

GENERAL REMARKS ON BENIGN TUMORS

Benign tumors of the esophagus, including the nonneoplastic tumor-like lesions, are generally small and asymptomatic. The clinically manifest lesions are rare. Their incidence at autopsy is around 0.5 percent and they constitute about 20 percent of all esophageal tumors (Attah and Hajdu; Plachta). Among patients with dysphagia, Moersch and Harrington found benign tumors of the esophagus in only 15 of 11,000 patients. Among surgically resected esophageal tumors, less than 10 percent were benign; only 3 percent were found in the files at the University of Maryland Hospital.

Regardless of their cellular composition, these benign tumors can be classified according to their gross location and appearance into three groups: intraluminal, intramural, and extramural. The **intraluminal** tumors are polypoid; their free movement up and down the lumen causes dysphagia and rarely asphyxiation occurs if the tumor is located high enough in the esophagus. The most dramatic clinical picture results from a polypoid lesion with such a long stalk that the patient regurgitates the mass and it hangs out of his mouth. Erosion and ulceration at the tip of polypoid lesions are common and sometimes result in massive hemorrhage. **Intramural** tumors are the most frequent. Small lesions are usually asymptomatic and found only incidentally at autopsy. Dysphagia accompanies a large tumor, but hemorrhage is exceptional since the mucosa overlying the tumor generally remains intact. **Extramural** or paraesophageal tumors cause not only esophageal symptoms, consisting mainly of dysphagia, but also symptoms of compression on the neighboring organs, especially the respiratory tract.

Plachta reviewed 432 cases of benign tumor of the esophagus, including 99 of his cases. Schmidt and associates presented 90 cases from the Mayo Clinic in 1961. The various histologic types of these benign tumors of the esophagus are listed in Table I.

Table I
BENIGN TUMORS OF ESOPHAGUS*

Type	Number
Leiomyoma	283
Polyp	110
Cyst	59
Fibroma	17
Papilloma	14
Lipoma	11
Angioma	10
Adenoma	5
Neurofibroma	4
Miscellaneous	9
Total	522

*Data from Plachta and Schmidt et al

It should be noted that the polyps are predominantly intraluminal; some of the myomas are extramural, but the majority of the tumors are intramural. Table II shows that the lower esophagus is the most frequent site for the majority of these lesions.

Table II

REPORTED LOCATIONS OF BENIGN TUMORS OF ESOPHAGUS*

Type	Upper	Middle	Lower	Total
Leiomyoma	37	61	97	195
Polyp	5	9	18	32
Cyst	2	3	7	12
Lipoma	3	2	2	7
Hemangioma	2	4	1	7
Fibroma	3	1	2	6
Papilloma	1	1	1	3
Adenoma	0	1	2	3
Neurofibroma	0	1	2	3
Others	0	2	4	6
Total	53	85	136	274

*Data from Attah and Hadju. Boyd and Hill. Johnston et al. Moersch and Harrington. Nese; and Plachta

Esophagography outlines these tumors as sharply delineated, oval, round, or lobulated filling defects. They may also be easily visualized by esophagoscopy, but the excessive mobility of the pedunculated lesions may sometimes make them more difficult to demonstrate because of their changing position and the ease with which they may be pushed aside by the advancing esophagoscope. The esophagoscope also serves as an instrument of treatment through which the intraluminal polypoid tumors may be removed. Most of the tumors, however, require thoracotomy. Since the esophageal epithelium covering intramural and paraesophageal lesions is usually intact, often it is not necessary to enter the esophageal lumen. Segmental resection of the esophagus is necessary only if the tumor is large or annular. It is important to realize, however, that carcinoma may be present on rare occasions in the overlying or adjacent mucosa (p. 68; fig. 61).

References

Attah, E. B., and Hajdu, S. I. Benign and malignant tumors of the esophagus at autopsy. J. Thorac. Cardiovasc. Surg 55:396–404, 1968.

Boyd, D. P., and Hill, L. D., III. Benign tumors and cysts of the esophagus. Amer J. Surg. 93:252–258, 1957.

Burge, J. P., and Ochsner, J. L. Management of esophageal tumors. Surg. Clin. N. Amer. 46:1457–1467, 1966.

Johansson, L., and Silander, T. Benign oesophageal tumours. Acta Chir. Scand. 126:573–578, 1963.

Johnston, J. B., Clagett, O. T., and McDonald, J. R. Smooth-muscle tumours of the oesophagus. Thorax 8:251–265, 1953.

Moersch, H. J., and Harrington, S. W. Benign tumor of the esophagus. Ann. Otol. 53:800–817, 1944.

Nese, G. Benign tumors and cysts of the esophagus. Acta Chir. Scand. 114:165–171, 1958.

Plachta, A. Benign tumors of the esophagus. Review of literature and report of 99 cases. Amer. J. Gastroent. 38:639–652, 1962.

Schmidt, H. W., Clagett, O. T., and Harrison, E. G., Jr. Benign tumors and cysts of the esophagus. J. Thorac. Cardiovasc. Surg 41:717–732, 1961.

Totten, R. S., Stout, A. P., Humphreys, G. H., II, and Moore, R. L. Benign tumors and cysts of the esophagus. J. Thorac. Cardiovasc. Surg 25:606–622, 1953.

TUMORS AND TUMOR-LIKE LESIONS OF ENTODERMAL ORIGIN

CYSTS

INCLUSION CYST

In embryonic life the esophageal epithelium is composed successively of columnar, ciliated columnar, and finally squamous cells. Cysts may be formed by any one of these cells and may, therefore, have a varied or even mixed cell type in the epithelial lining. The cysts are unilocular and smooth. A few short papillary projections may be present (Stout and Lattes). Inclusion cysts are usually found in the lower portion of the esophagus and present mild symptoms of obstruction.

RETENTION CYST (MUCOCELE)

Retention cysts are formed by the dilatation of the excretory duct of the esophageal glands. Since the superficial cardiac glands do not have true ducts, but open into the lumen directly, only a mild cystic dilatation of the glands may occur. The deep esophageal glands, on the other hand, have long ducts which pass through the muscularis mucosae and communicate with the lumen through a small opening surrounded by squamous epithelium. Significant retention cysts originate almost exclusively in the deep glands (fig. 7).

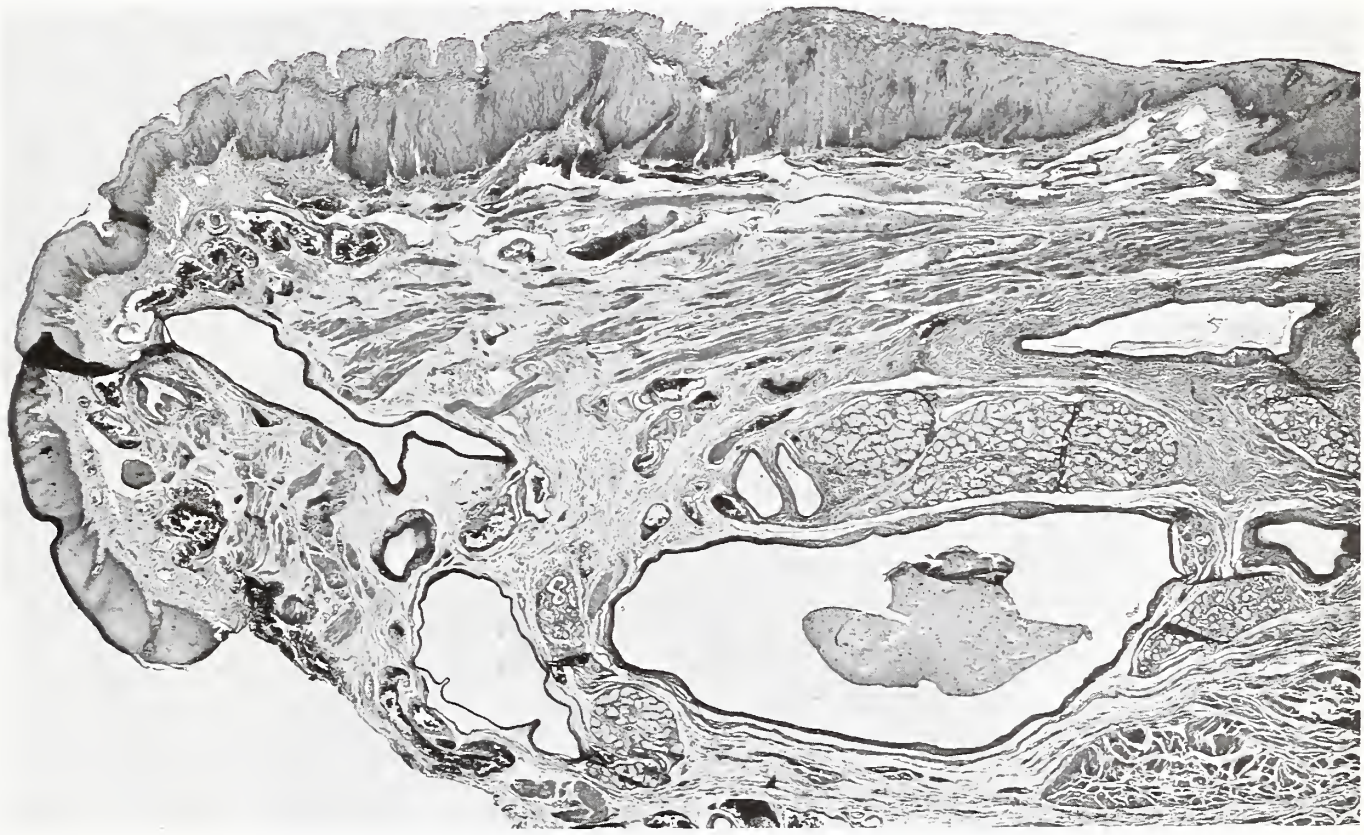

Fig 7

RETENTION CYSTS

Cystic dilatation of the ducts of deep esophageal glands shown here was found incidentally in the upper esophagus of a 52-year-old woman. Mucus is present in some of the ducts. The acini remain normal. The squamous epithelium is hyperplastic. Chronic inflammation of the tunica propria is also present, but difficult to see at this magnification. × 22.

These cysts occur more frequently in the lower esophagus and are generally asymptomatic.

CYST OF DEVELOPMENTAL ORIGIN

Duplication cysts may have an epithelial lining resembling that of the esophagus, bronchus, or stomach and are, therefore, designated as esophageal, bronchial, or gastric cysts, respectively (figs. 8, 9, 10). They are formed either by incomplete separations of the organs, as in bronchial cysts, or as a result of separate entodermal centers in the mesoderm surrounding the foregut, as in esophageal and gastric cysts. Occasionally, squamous as well as gastric mucosa may be present in the same cyst (Cassel et al.; Dickson et al.). It has also been postulated that a duplication cyst represents a pinched-off diverticulum of the foregut, similar to the mechanism suggested by Lewis and Thyng for intestinal diverticulum. Although intestinal diverticula are common in the embryo, the esophageal counterpart has not been observed.

Duplication cysts are usually extramural and connect only partially or not at all with the esophageal wall. Symptoms are those of a posterior mediastinal mass, often occurring during infancy or childhood. The mesoderm around these cysts is often poorly retained; the outer lining may consist of only a thin fibrous layer devoid of other elements, such as muscle or cartilage. In many instances, however, there is a distinct muscularis propria, sometimes double-layered, which when present serves to differentiate the duplication cyst from an inclusion cyst.

The bronchial cyst is generally located in the upper mediastinum. The gastric or enteric duplication cyst usually occurs along the right side in the posterior mediastinum. The latter

Fig 8
BRONCHIAL CYST

(Figures 8 and 9 from same case)

This illustrates the exterior view of a bronchial cyst found in the upper mediastinum. (Courtesy of The Massachusetts General Hospital, Boston, Mass.)

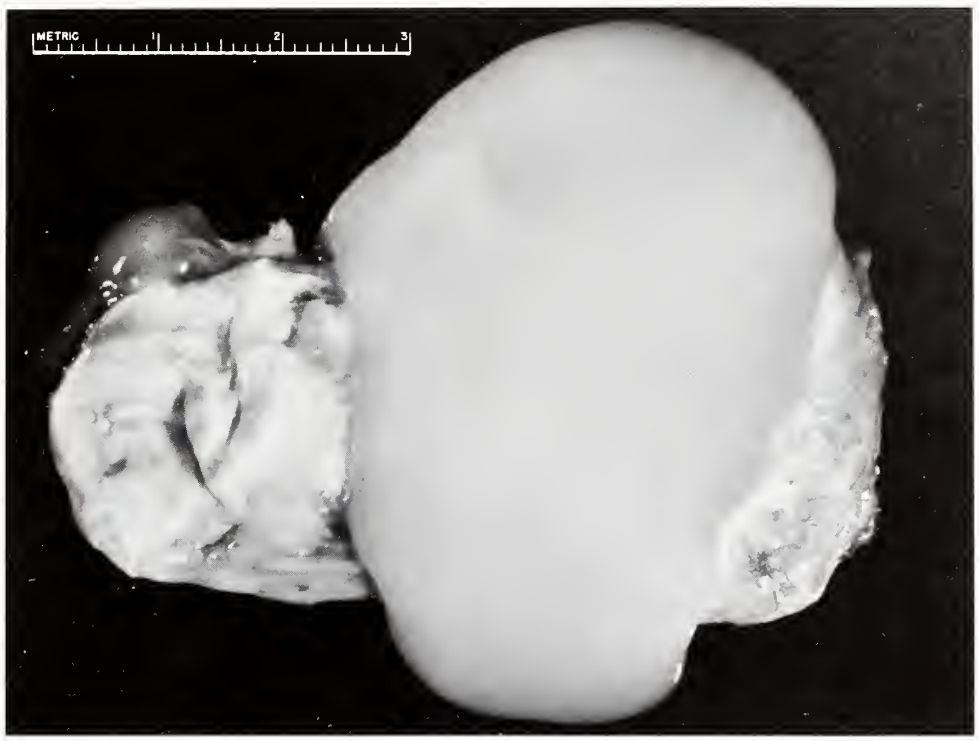

Fig 9

BRONCHIAL CYST

(Figures 8 and 9 from same case)

The interior of the same cyst as figure 8 reveals the mucus content and a smooth lining (Courtesy of The Massachusetts General Hospital, Boston, Mass)

consists of either an enclosed cystic mass or a long tubular structure which extends most of the length of the esophagus and communicates with the esophagus or stomach. Part of the cyst may be intraabdominal, and may penetrate a diaphragmatic hiatus separate from that of the esophagus. The mucosal lining is composed entirely, or in part, of fundic mucosa of the stomach. Squamous or intestinal epithelium may also occur. Peptic ulceration has been encountered within such cysts. A solid mass of ectopic tissue, such as pancreas or thyroid, is a rarity in the esophagus. Gans and Potts reported one anomalous lobe of lung connecting with the esophagus by a fistula.

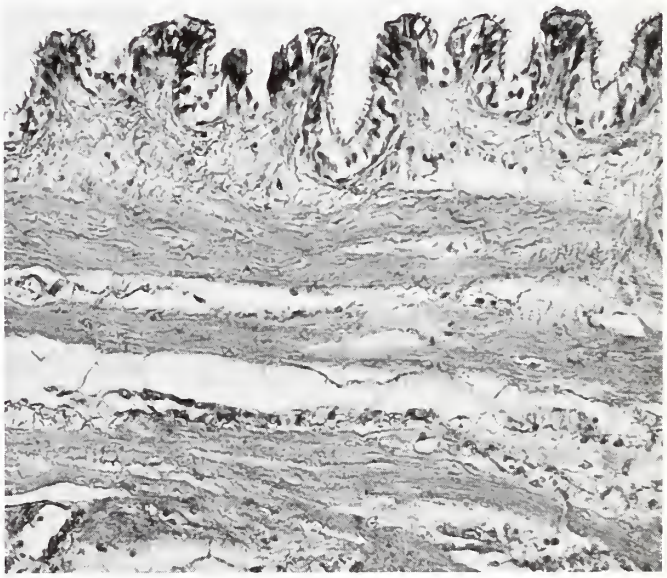

Fig. 10

BRONCHIAL CYST

This bronchial cyst is lined by ciliated epithelium with underlying muscularis. The cyst was located in the outer aspect of the upper portion of the esophagus in a 33-year-old woman and measured 1.4 cm. in diameter. × 150 (Courtesy of Beth Israel Hospital, Boston, Mass.)

References

Attah, E. B., and Hajdu, S. I. Benign and malignant tumors of the esophagus at autopsy. J. Thorac. Cardiovasc. Surg. 55 396–404, 1968

Boyd, D. P., and Hill, L. D., III. Benign tumors and cysts of the esophagus. Amer. J. Surg. 93:252–258, 1957.

Burge, J. P., and Ochsner, J. L. Management of esophageal tumors. Surg. Clin. N. Amer. 46:1457–1467, 1966.

Cassel, M. A., Cunningham, R. T., and Weisel, W. A foregut cyst of the mediastinum. J. Thorac. Cardiovasc. Surg. 19:138–144, 1950.

Dickson, J. A., Clagett, O. T., and McDonald, J. R. Intrathoracic gastric cyst. J. Thorac. Cardiovasc. Surg. 15:318–323, 1946.

Gans, S. L., and Potts, W. J. Anomalous lobe of lung arising from the esophagus. J. Thorac. Cardiovasc. Surg. 21:313–318, 1951.

Johansson, L., and Silander, T. Benign oesophageal tumours. Acta Chir. Scand. 126:573–578, 1963.

Ladd, W. E., and Scott, H. W., Jr. Esophageal duplications or mediastinal cysts of enteric origin. Surgery 16:815–835, 1944.

Langston, H. T., Tuttle, W. M., and Patton, T. B. Esophageal duplications. Arch. Surg. 61:949–956, 1950.

Lewis, F. T., and Thyng, F. W. The regular occurrence of intestinal diverticula in embryos of pig, rabbit, and man. Amer. J. Anat. 7:505–519, 1907.

Moersch, H. J., and Harrington, S. W. Benign tumor of the esophagus. Ann. Otol. 53:800–817, 1944.

Nese, G. Benign tumors and cysts of the esophagus. Acta Chir. Scand. 114:165–171, 1958.

Plachta, A. Benign tumors of the esophagus. Review of literature and report of 99 cases. Amer. J. Gastroent. 38:639–652, 1962.

Razi, M. D. Ectopic pancreatic tissue of esophagus with massive upper gastrointestinal bleeding. Arch. Surg. 92:101–104, 1966.

Schmidt, H. W., Clagett, O. T., and Harrison, E. G., Jr. Benign tumors and cysts of the esophagus. J. Thorac. Cardiovasc. Surg. 41:717–732, 1961.

Stout, A. P., and Lattes, R. Tumors of the Esophagus. Fascicle 20, Atlas of Tumor Pathology. Washington: Armed Forces Institute of Pathology, 1957.

Whale, H. L. Oesophageal tumour of thyroid tissue. Brit. Med. J. 2:987, 1921.

BENIGN EPITHELIAL TUMORS

SQUAMOUS CELL PAPILLOMA*

Early reports diagnosed squamous cell papillomas by their esophagoscopic appearance of sessile papillary excrescences rather than by histologic examination. Descriptions of some of these lesions are more compatible with those of fibrous polyp than papilloma, while others suggest an inflammatory nature. Because the term papilloma was often used without clarification, Stout and Lattes advocated abandoning it.

A true papilloma is a benign neoplastic lesion; it is sessile, with papillary tissue projecting above the mucosal surface, and the papillae are composed of a central core of connective tissue covered with hyperplastic squamous cells. Such lesions are apparently rare. In 1959 Adler and associates recorded one case in the lower esophagus. Another case of papilloma, at the level of the carina of the trachea, was reported by Weitzner and Hentel in 1968.

ADENOMA

Although the esophagus contains both superficial and deep glands, true adenoma of the esophagus is extremely rare. The few reported cases have recorded only slightly elevated mucosal plaques. The mere presence of glandular structure in this type of lesion is not sufficient for the diagnosis of adenoma, since an inflammatory lesion in the area of glandular epithelium may give a similar appearance. The normal appearing glands illustrated in Moersch and Broders' report reaffirms this impression.

On the other hand, there is no reason to exclude the possibility of benign neoplastic proliferation in the glandular epithelium of the esophagus. Barrett presented an adenomatous polyp which was composed of gastric type glands in the lower esophagus lined by columnar epithelium. In view of the relative frequency of cardiac glands in the esophagus, it is surprising that more

of such polyps have not been reported. In this regard, esophageal cardiac glands appear to share the same peculiarity as cardiac glands of the stomach; neither favors the development of a benign neoplasm even though carcinoma is not an infrequent development.

References

Adler, R. H., Carberry, D. M., and Ross, C. A. Papilloma of the esophagus: association with hiatal hernia. J. Thorac. Cardiovasc. Surg. 37: 625–635, 1959.

Barrett, N. R. Benign smooth muscle tumours of the oesophagus. Thorax 19: 185–194, 1964.

Moersch, H. J., and Broders, A. C. Adenoma of the esophagus. Arch. Otolaryng. 21: 168–171, 1935.

Stout, A. P., and Lattes, R. Tumors of the Esophagus. Fascicle 20, Atlas of Tumor Pathology. Washington: Armed Forces Institute of Pathology, 1957.

Weitzner, S., and Hentel, W. Squamous papilloma of esophagus. Case report and review of the literature. Amer. J. Gastroent. 50: 391–396, 1968.

MALIGNANT EPITHELIAL TUMORS

Squamous cell carcinoma is the most common tumor in the esophagus. The much less common adenocarcinoma occurs usually at the lower end of the esophagus in close association with gastric epithelium. The latter has generated much interest recently, after its relationship with hiatus hernia was pointed out (see the section on Associated Conditions, p. 26). Squamous cell carcinoma remains the most important tumor in the esophagus, however, and it is the primary concern in epidemiologic and experimental studies. The simplicity of the organ structure and the infrequent occurrence of other tumors make the diagnosis of squamous cell carcinoma a relatively simple matter in clinically manifest cases. In view of the relatively few lymphatic vessels in the esophageal wall, it is not surprising that lymph node metastases are absent in nearly 40 percent of cases. Prognosis has been poor, however, mainly because of contiguous extension of the carcinoma beyond the esophageal wall and the close relationship with neighboring structures. As a result, it is often difficult to adequately resect the lesion. In recent years, advances in radiotherapy have significantly altered the therapeutic approach toward this tumor. Radiotherapy has provided more symptomatic relief, but has not improved the gloomy prognosis and ultimate fate.

EPIDEMIOLOGY AND GEOGRAPHIC INCIDENCE. Great variations exist among nations in mortality rates due to esophageal carcinoma (fig. 11). On the other hand, the percentages of death due to esophageal cancer among the deaths due to all malignant tumors shows a relative uniformity, averaging 2 to 5 percent in most countries. Thus, the prevalence of esophageal cancer in various countries reflects the general prevalence of malignant tumors. For example, death due to esophageal cancer is about 10 times more frequent in France than in Ceylon, but in both these countries esophageal carcinoma is responsible for about 4 percent of deaths due to malignant tumors. In Puerto Rico and some regions in Africa, where esophageal cancer causes a high number of deaths, it is a leading malignant tumor as well. This is also true among the Alaskan Eskimos and in parts of Northern China. In the United States, variations exist among the States (Gordon et al.). The diverse environment, socioeconomic structure, and habits in the various regions may play an important role in emphasizing these differences. This is not always evident, however, as shown by the studies of Haenszel, who noted the low incidence of esophageal cancer in native-born U. S. males, but found a high incidence in migrants which was greater than the incidence in their country of origin. Esophageal cancer occurs predominantly in men, but the male to female ratio varies greatly in different regions. In some countries or regions where the incidence is high, the ratio tends to be low, suggesting again the role of environmental factors. Recent epidemiologic studies, particularly those undertaken in Africa, have provided some insight into the etiology of this disease. These studies, discussed in further detail in the next section, incrim-

inate the socioeconomic structure or customs as major culprits.

ETIOLOGIC FACTORS. As in other diseases, the causes of esophageal carcinoma probably include both genetic and environmental factors. The prevalence among certain nationalities, among males, and possible association with blood type A are suggestive of a genetic predisposition. After analyzing the incidence of esophageal cancer in Wales, Ashley noted an increased risk of disease with increasing numbers of Welsh forebears, particularly in women, and he suggested the possibility of an X-linked genetic factor. Investigation in North China revealed a higher incidence of esophageal carcinoma among patients with a positive family history than among a control group of similar age and sex distribution (Li et al.). Contrary to these findings, Mosbech and Videbaek found no evidence of increased familial prevalence among Danes. The only definite evidence of a genetic factor was found among members of two Liverpool families who had tylosis. Howel-Evans and associates found 18 cases of esophageal cancer among 152 members of these families in three generations. It seems clear that genetic factors are involved only in particular situations and are of minor importance in most cases compared to environmental factors.

Esophageal carcinoma is said to be more prevalent among people of low economic level. In Puerto Rico, where studies were conducted of afflicted patients and of a control group of similar economic status, no differences in education or

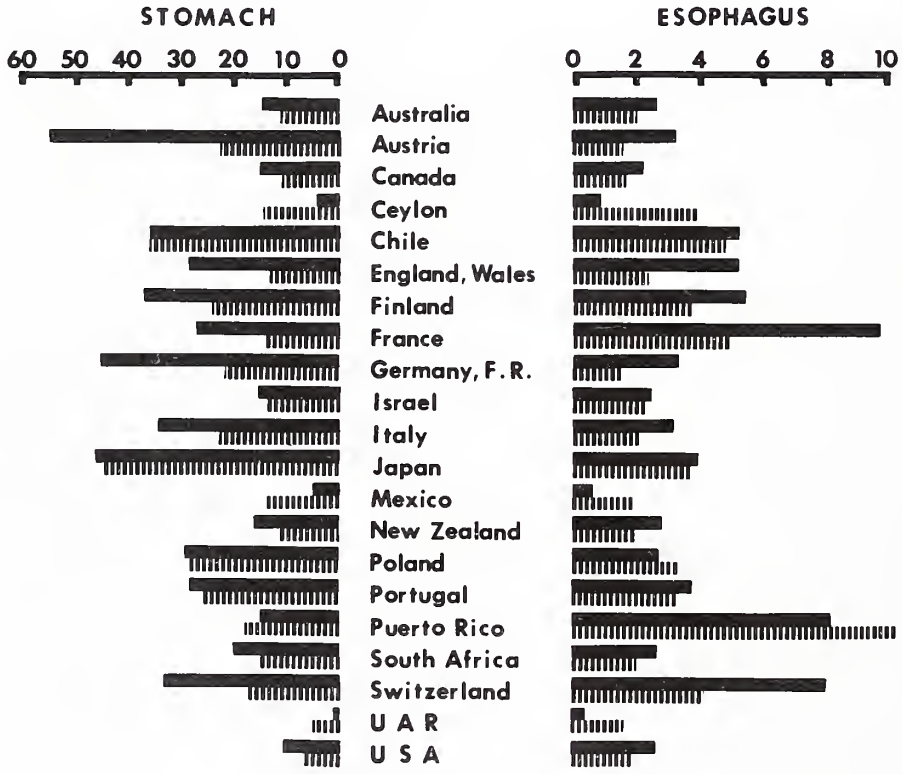

Fig. 11

DEATH RATE DUE TO ESOPHAGEAL AND GASTRIC CARCINOMAS

The solid bar indicates the death rate from carcinomas of the esophagus or stomach per 100,000 population. The broken bar shows percentage of death rate due to esophageal or gastric carcinoma among deaths from all malignant tumors. (World Health Organization. 1962 data: Causes of death. Malignant neoplasms of oesophagus, of stomach, of intestine and of rectum. WHO Epidem. Vital Statist. Rep. 18:261–288, 1965.)

occupation were found (Martinez). A study in Connecticut failed to correlate any variation in disease incidence with population density and magnitude of industrialization (Mason et al.). Thus, socioeconomic status has no direct bearing on the development of esophageal cancer, but it may serve as an indirect factor. Under specific circumstances, the habits and environment could enhance the occurrence of the disease.

Heavy alcoholic intake has long been considered an etiologic factor and recent studies reaffirm this viewpoint (Kamionkowski and Fleshler; Wynder and Bross). On the other hand, in parts of North China where the prevalence of esophageal carcinoma is particularly high, alcohol intake is either low or practically nonexistent. Similarly, no relationship between alcohol and esophageal cancer is found in India. It has been suggested that perhaps it is not the alcohol but contaminants which are more significant. This view is supported by the studies of McGlashan in Zambia where the incidence of esophageal cancer is high in eastern Zambia and Malawi, but rare in northern and western Zambia. This geographic distribution coincides with the use of *Kachasu,* a locally distilled spirit. Unusually high quantities of zinc and copper, as well as nitrosamine-like substances, have been found in many samples of this drink. While the carcinogenic potential of zinc and copper is uncertain, in laboratory animals nitrosamines have been shown to be potent carcinogens for several organs, including the esophagus. Japanese investigators have also found polycyclic aromatic hydrocarbons in some samples of bourbon and whiskey.

Heavy usage of cigarettes, as well as cigars and pipe tobacco, has been reported among patients with esophageal cancer. A 3.4 to 1 mortality ratio was found between the observed and expected cases of esophageal cancer in cigarette smokers (Burdette). Morphologic support for this is found in a study by Auerbach and associates, who noted the common occurrence of basal cell hyperplasia and nuclear atypism of esophageal epithelium in smokers. Boyland and associates suspected that nitroso-compounds may also be present in tobacco smoke.

Hot and spicy foods consumed by the Chinese, Icelanders, and Finns have been considered responsible for the high incidence of carcinoma in the upper alimentary tract of these people although firm evidence is lacking. Malnutrition and the chewing of betel nuts have also been associated with esophageal cancer in Natal of South Africa and India. Recently, the possibility of carcinogens in food has been explored in geographic areas of high risk for esophageal cancer. Investigation by Burrell and associates of the high incidence of esophageal carcinoma in the Transkei Territory of South Africa, where the disease has increased from virtual nonexistence to epidemic proportions during the last 25 years, disclosed poor crops and diseased plant leaves in the area. The abnormal vegetation apparently resulted from deficient molybdenum in the soil. It was postulated that molybdenum deficiency may cause an increase of nitrate formation in plants, resulting possibly in the formation of nitrosamine compounds. Subsequently, dimethylnitrosamine was found in *Solanum incanum;* the juice of this fruit is used to curdle milk by the local inhabitants (Du Plessis et al.). O'Gara found that the extracts of plants grown in Curacao, West Indies, where the incidence of esophageal cancer is also high, were carcinogenic in mice.

It appears that studies on these possible etiologic agents may begin to bear fruit. It is by no means certain, however, that carcinogenic substances uncovered thus far are responsible for esophageal cancers in different parts of the world. Much remains unknown. In addition to factors already mentioned, which may affect the general population, certain local conditions or disease states that appear to promote development of esophageal cancer will be discussed in the following paragraphs.

References

Ashley, D. J. Oesophageal cancer in Wales. J. Med. Genet. 6:70–75, 1969.

Auerbach, O., Stout, A. P., Hammond, E. C., and Garfinkel, L. Histologic changes in esophagus in relation to smoking habits. Arch. Environ. Health 11:4–15, 1965.

Boyland, E., Roe, F. J. C., Gorrod, J. W., and Mitchley, B. C. V. The carcinogenicity of nitrosoanabasine, a possible constituent of tobacco smoke. Brit. J. Cancer 18:265–270, 1964.

Bradshaw, E., and Schonland, M. Oesophageal and lung cancers in Natal African males in relation to certain socio-economic factors. An analysis of 484 interviews. Brit. J. Cancer 23:275–284, 1969.

Burdette, W. J. The Use of Tobacco and Carcinoma of the Esophagus and Stomach, p. 173. In: Carcinoma of the Alimentary Tract. (Ed.) Burdette, W. J. Salt Lake City: University of Utah Press, 1965.

Burrell, R. J. Distribution maps of esophageal cancer among Bantu in the Transkei. J. Nat. Cancer Inst. 43:877–889, 1969.

———, Roach, W. A., and Shadwell, A. Esophageal cancer in the Bantu of the Transkei associated with mineral deficiency in garden plants. J. Nat. Cancer Inst. 36:201–209, 1966.

Du Plessis, L. S., Nunn, J. R., and Roach, W. A. Carcinogen in a Transkeian Bantu food additive. Nature 222:1198–1199, 1969.

Gordon, T., Crittenden, M., and Haenszel, W. Cancer mortality trends in the United States, 1930–1955. Nat. Cancer Inst. Monog. 6:133–350, 1961.

Haenszel, W. Migrant Populations and Alterations in Incidence within Indigenous Populations, p. 35. In: Carcinoma of the Alimentary Tract. (Ed.) Burdette, W. J. Salt Lake City: University of Utah Press, 1965.

Howel-Evans, W., McConnell, R. B., Clarke, C. A., and Sheppard, P. M. Carcinoma of the oesophagus with keratosis palmaris et plantaris (tylosis). A study of two families. Quart. J. Med. 27:413–429, 1958.

Hurst, E. E., Jr. Malignant tumors in Alaskan Eskimos: unique predominance of carcinoma of the esophagus in Alaskan Eskimo women. Cancer 17:1187–1196, 1964.

Kamionkowski, M. D., and Fleshler, B. The role of alcoholic intake in esophageal carcinoma. Amer. J. Med. Sci. 249:696–700, 1965.

Li, K. H., Kao, J. C., and Wu, Y. K. A survey on the prevalence rate of carcinoma of the esophagus in North China. Acta Un. Int. Cancr. 20:629–631, 1964.

Martinez, I. Factors associated with cancer of the esophagus, mouth, and pharynx in Puerto Rico. J. Nat. Cancer Inst. 42:1069–1094, 1969.

Mason, M. J., Bailar, J. C., III, and Eisenberg, H. Geographic variation in the incidence of esophageal cancer. J. Chronic Dis. 17:667–676, 1964.

Masuda, Y., Mori, K., Hirohata, T., and Kuratsune, M. Carcinogenesis in the esophagus. 3. Polycyclic aromatic hydrocarbons and phenols in whisky. Gann 57:549–557, 1966.

McGlashan, N. D. Oesophageal cancer and alcoholic spirits in Central Africa. Gut 10:643–650, 1969.

Mosbech, J., and Videbaek, A. On the etiology of esophageal carcinoma. J. Nat. Cancer Inst. 15:1665–1673, 1955.

O'Gara, R. W. Biologic screening of selected plant material for carcinogens. Cancer Res. 28:2272–2275, 1968.

World Health Organization, 1962 data. Causes of death. Malignant neoplasms of oesophagus, of stomach, of intestine and of rectum. WHO Epidem. Vital Statist. Rep. 18:261–288, 1965.

Wynder, E. L., and Bross, I. J. A study of etiological factors in cancer of the esophagus. Cancer 14:389–413, 1961.

ASSOCIATED CONDITIONS. Smithers brought attention to the increased incidence of carcinoma in the lower esophagus in the presence of a **hiatus hernia.** Tager reported an incidence of 1.6 percent compared with 0.33 percent among patients without such hernias. Of the 109 cases collected by Pattison and associates from the literature, most were adenocarcinoma involving the esophagogastric junction or cardia of the stomach; 16 were squamous cell carcinoma of the esophagus. Smithers pointed out, however, that in many cases the hernia might be a complication secondary to carcinoma at the esophagogastric junction. A similar view was given in a more recent analysis of cases seen at the Mayo Clinic (Michel et al.). The high proportion of adenocarcinoma in such cases coincides with the frequent finding of gastric epithelium in the lower esophagus. This latter condition presumably follows reflux esophagitis commonly associated with hiatus hernia.

An **esophagus lined by columnar epithelium** may be either a developmental or an acquired anomaly. The developmental variety is sometimes known as Barrett esophagus. Rarely, the entire esophagus is shortened and the portion lined by

columnar epithelium is in fact an intrathoracic extension of the stomach. Adenocarcinoma develops in a high proportion of such cases. According to Stemmer and Adams, the incidence of cancer in the congenital cases is 6.9 percent; in contrast, the incidence of cancer arising in acquired columnar epithelium in the esophagus is 1.8 percent and in cases of hiatus hernia, 1.7 percent.

In the esophagus with a **benign stricture** of long duration, carcinoma develops in 3 to 5 percent of cases. Most frequently, the stricture follows the ingestion of lye during early childhood (Benedict). The average interval between lye ingestion and appearance of carcinoma is 31 years, and the average age of the patient with carcinoma is 35 years. The youngest patient reported was a 15-year-old Korean boy (Kinnman et al.). All these carcinomas are squamous cell type and occur at the site of stricture, usually at the level of the tracheal bifurcation.

In **achalasia,** on the other hand, carcinoma usually occurs in the dilated portion rather than at the narrowed distal end of the esophagus. The reported incidence of carcinoma in achalasia varies from 0 to 20 percent (Just-Viera and Haight; Williams); several reports state an incidence of about 3 percent (Akuamoa; Just-Viera and Haight). The average age of the patient is approximately 50 years. Most of these cancers are squamous cell type, but several adenocarcinomas and one carcinosarcoma have also been reported.

Squamous cell carcinoma has also been reported in **pulsion diverticulum,** which is more common at the pharyngoesophageal than epiphrenic location (Pierce and Johnson).

The incidence of esophageal cancer is high in **tylosis** and **Plummer-Vinson** syndrome, although the primary disease process involves other tissues. Its association with familial tylosis *(keratosis palmaris et plantaris)* has been mentioned on page 24. Esophageal cancer has also recently been found in sporadic cases of tylosis (Parnell and Johnson). Plummer-Vinson (Paterson-Kelly) syndrome is frequently associated with mucosal webs and carcinoma in the upper esophagus and postcricoid area (Ahlbom). The high incidence of esophageal cancer in Swedish women has been explained on this basis (Wynder et al.). Histologic study of the postcricoid area in patients with Plummer-Vinson syndrome revealed acanthosis, basal irregularity, carcinoma in situ, and even invasive carcinoma at the site of stricture (Entwistle and Jacobs). In other parts of the world, however, women with esophageal cancer generally do not have a history of Plummer-Vinson syndrome.

References

Ahlbom, H. E. Simple achlorhydric anaemia, Plummer-Vinson syndrome, and carcinoma of the mouth, pharynx, and oesophagus in women; observations at Radiumhemmet, Stockholm. Brit. Med. J. 2:331–333, 1936.

Akuamoa, G. Achalasia oesophagi and associated diseases. Acta Chir. Scand. 135:421–427, 1969.

Benedict, E. B. Carcinoma of the esophagus developing in benign stricture. New Eng. J. Med. 224:408–412, 1941.

Bigelow, N. H. Carcinoma of esophagus developing at site of lye stricture. Cancer 6:1159–1164, 1953.

Entwistle, C. C., and Jacobs, A. Histological findings in the Paterson-Kelly syndrome. J. Clin. Path. 18:408–413, 1965.

Just-Viera, J. O., and Haight, C. Achalasia and carcinoma of the esophagus. Surg. Gynec. Obstet. 128:1081–1095, 1969.

Kinnman, J., Shin, H. I., and Wetteland, P. Carcinoma of the oesophagus after lye corrosion. Report of a case in a 15-year-old Korean male. Acta Chir. Scand. 134:489–493, 1968.

Michel, J. O., Olsen, A. M., and Dockerty, M. B. The association of diaphragmatic hiatal hernia and gastroesophageal carcinoma. Surg. Gynec. Obstet. 124:583–589, 1967.

Parnell, D. D., and Johnson, S. A. M. Tylosis palmaris et plantaris. Its occurrence with internal malignancy. Arch. Derm. 100:7–9, 1969.

Pattison, J. N., Osborne, G., and Morson, B. C. Hiatus hernia with adenocarcinoma arising in the region of the cardia. J. Fac. Radiol. 7:90–101, 1955-6.

Pierce, W. S., and Johnson, J. Squamous cell carcinoma arising in a pharyngoesophageal diverticulum. Cancer 24:1068–1070, 1969.

Smithers, D. W. Achalasia, Hiatus Hernia, Muscular Hypertrophy, Columnar Cell Oesophageal Mucosa and their Association with Oesophageal Tumours, pp. 61–80. In: Tumours of the Oesophagus. (Eds.) Tanner, N. C., and Smithers, D. W. Edinburgh & London. E. & S. Livingstone, Ltd., 1961.

Stemmer, E. A., and Adams, W. E. The incidence of carcinoma at the esophagogastric junction in short esophagus. Arch. Surg. 81:771–780, 1960.

Tager, I. L. Hernia of the oesophageal opening and cardioesophageal cancer. Acta Un. Int. Cancr. 19:1263–1265, 1963.

Williams, J. L. Carcinoma of the oesophagus as a complication of achalasia of the cardia. Thorax 11:268–274, 1956.

Wynder, E. L., Hultberg, S., Jacobsson, F., and Bross, I. J. Environmental factors in cancer of the upper alimentary tract. A Swedish study with special reference to Plummer-Vinson (Paterson-Kelly) syndrome. Cancer 10:470–487, 1957.

EXPERIMENTAL CARCINOGENESIS. Spontaneous esophageal cancer is rare in animals. Schütte found esophageal carcinoma in 8 percent of sheep in a limited area in South Africa. These sheep had been drenched with nicotine sulfate and copper sulfate during a 10-year period to eliminate parasites. When these chemicals were discontinued, esophageal carcinoma also disappeared. The esophagus of laboratory animals appears to be resistant to carcinogen, although squamous cell carcinoma is readily produced in the squamous epithelium of the forestomach. Recently, Long and Jenner produced esophageal tumors in rats by feeding dihydrosafrole in a concentration of 5000 parts per million or more. Gates and Warren reported a high incidence of esophageal carcinoma in mice that received gamma radiation from cobalt-60 placed in the lung. Benzo(a)pyrene and 4-nitroquinoline 1-oxide have proved carcinogenic for the esophagus of animals (Horie et al.). Since the report by Magee in 1956 of hepatic carcinogenesis in rats fed dimethylnitrososamine, many nitroso-compounds have been used to induce a variety of tumors in different organs. Among such tumors, esophageal carcinoma has been induced in rats (fig. 12) and hamsters by feeding of diethyl, diamyl, and dibutylnitrosamines, N-methyl-N-nitrosoaniline, methylnitrosourethane, and other similar compounds (Magee and Schoental; Druckrey and Schmähl). Histologically, esophageal carcinoma is preceded by epithelial hyperplasia and papilloma formation (Napalkov and Pozharisski; Herrold). It has been postulated that the carcinogenicity of nitroso-compounds could be due to the alkylating action of decomposition products, possibly diazomethane or a related diazoalkane (Weisburger and Weisburger).

Fig. 12

EXPERIMENTAL SQUAMOUS CELL CARCINOMA

This illustrates a squamous cell carcinoma of the esophagus in a rat fed diethylnitrosamine. The carcinoma involves half of the circumference and extends into the submucosa, but the muscularis is intact. × 15. (Courtesy of Dr. Melvin Reuber, Baltimore, Md.)

References

Druckrey, H., and Schmähl, D. Quantitative analyse der experimentellen Krebserzeugung. Die Naturwissenschaften 49:217–228, 1962.

Gates, O., and Warren, S. Radiation-induced experimental cancer of the esophagus. Amer. J. Path. 53:667–685, 1968.

Herrold, K. McD. Epidermoid carcinomas of esophagus and forestomach induced in Syrian hamsters by N-nitroso-N-methylurethan. J. Nat. Cancer Inst. 37:389–393, 1966.

Horie, A., Hohchi, S., and Kuratsune, M. Carcinogenesis in the esophagus. II. Experimental production of esophageal cancer by administration of ethanolic solution of carcinogens. Gann 56:429–441, 1965.

Long, E. L., and Jenner, P. M. Esophageal tumors produced in rats by the feeding of dihydrosafrole. Fed. Proc. 22: 275, 1963.

Magee, P. N., and Barnes, J. M. The production of malignant primary hepatic tumours in the rat by feeding dimethylnitrososamine. Brit. J. Cancer 10:114–122, 1956.

———, and Schoental, R. Carcinogenesis by nitroso compounds. Brit. Med. Bull. 20:102–106, 1964.

Napalkov, N. P., and Pozharisski, K. M. Morphogenesis of experimental tumors of the esophagus. J. Nat. Cancer Inst. 42:927–940, 1969.

Schütte, K. H. Esophageal tumors in sheep: some ecological observations. J. Nat. Cancer Inst. 41:821–824, 1968.

Weisburger, J. H., and Weisburger, E. K. Symposium on chemical carcinogenesis. Pharmacodynamics of carcinogenic azo dyes, aromatic amines, and nitrosamines. Clin. Pharmacol. Ther. 4:110–129, 1963.

SITES OF PRIMARY ESOPHAGEAL CARCINOMA. In spite of great geographic variation, the location of carcinoma within the esophagus shows relative uniformity in most countries, as shown by recent reports (Table III). About 50 percent of the tumors are in the middle third of the esophagus, 30 percent in the lower third, and 20 percent in the upper third. This distribution is similar to earlier reports. The cervical esophagus is rarely involved, except for the postcricoid area in women suffering from Plummer-Vinson syndrome. About 94 percent of primary carcinomas of the esophagus are squamous cell type, 3 percent are adenocarcinomas, and 3 percent are unclassified and undifferentiated tumors (Turnbull and Goodner). Carcinomas at the esophagogastric junction, on the other hand, are adenocarcinomas in 86 percent of cases, squamous cell carcinomas in 11 percent, and unclassified tumors in 3 percent of cases (Ellis et al.). The University of Maryland Hospital has on file 268 primary carcinomas of the esophagus: 249 squamous cell carcinomas (93 percent), 9 adenocarcinomas (3 percent), and 10 undifferentiated carcinomas (4 percent). In addition, there were nine adenocarcinomas and one undifferentiated carcinoma at the esophagogastric junction. The site and geographic distribution of several studies of esophageal carcinoma appear in Table III.

Table III

SITES OF PRIMARY ESOPHAGEAL CARCINOMA IN VARIOUS COUNTRIES

Author*	Country	Number of Cases	Esophagus		
			Upper	Middle	Lower
Coetzee	South Africa	244	39%	50%	11%
Gynning	Sweden	250	7%	54%	39%
Leborgne	Uruguay	541	18%	44%	38%
Lu	China	217	9%	63%	28%
Marcial	Puerto Rico	408	17%	55%	27%
University of Maryland Hospital	United States	168	17%	41%	42%
Nealon	United States	316	19%	47%	34%
Voutilainen	Finland	519	9%	58%	33%
Total		2663	16%	52%	32%

*Complete references on page 30.

Note: Carcinomas at the esophagogastric junction or at an unknown site are excluded. Where the tumor involves more than one site, only one has been included.

References

Coetzee, T. Carcinoma of the oesophagus. S. Afr. J. Surg. 4:107–122, 1966.

Ellis, F. H., Jr., Jackson, R. C., Krueger, J. T., Jr., Moersch, H. J., Clagett, O. T., and Gage, R. P. Carcinoma of the esophagus and cardia: Result of treatment, 1946 to 1956. New Eng. J. Med. 260:351–358, 1959.

Gynning, I., and Lindgren, M. Roentgen rotation therapy of oesophageal cancer. Acta Chir. Scand. Suppl. 356: 130–136, 1965.

Leborgne, R., Leborgne, F., and Barlocci, L. Cancer of the oesophagus: Results of radiotherapy. Brit. J. Radiol. 36:806–811, 1963.

Lu, Y. K., Li, Y. M., Ch'en, T. M., and Keng, C. C. An analysis of mortality and postoperative complications of esophageal resection for cancer. Chin. Med. J. 83:39–44, 1964.

Marcial, V. A., Tomé, J. M., Ubinas, J., Bosch, A., and Correa, J. N. The role of radiation therapy in esophageal cancer. Radiology 87:231–239, 1966.

Nealon, T. F., Jr., and Camishion, R. C. Combined radiation and surgery to treat carcinoma of the esophagus. Amer. J. Gastroent. 48:380–391, 1967.

Turnbull, A. D. M., and Goodner, J. T. Primary adenocarcinoma of the esophagus. Cancer 22:915–918, 1968.

Voutilainen, A., and Koulumies, M. Results of radiation therapy of cancer of the oesophagus. Ann. Chir. Gynaec. Fenn. 54:40–51, 1965.

SQUAMOUS CELL CARCINOMA*

SYNONYMS AND RELATED TERMS: Squamous cell epithelioma, epidermoid carcinoma.

GROSS. By the time squamous cell carcinoma is diagnosed, it is often 5 to 7 cm. in length and the tumor has usually ulcerated and penetrated deep into the esophageal wall. The degree of intraluminal growth is variable. The relative prominence of these features makes it possible to divide gross patterns into fungating, ulcerative, and infiltrating types.

Fungating carcinoma, the most common type, is found in about 60 percent of cases. Its main feature is a prominent intraluminal growth, forming a large mass with an ulcerated surface (fig. 13) or multiple polypoid excrescences (fig. 14). The intraluminal portion of the tumor may also present itself as a flat, plaquelike mass with a well defined border (fig. 15) or as irregular nodules (fig. 16). The amount of intramural expansion is variable; when prominent, it adds to compression of the lumen. The intraluminal masses may be seen in the esophagogram as large filling defects (fig. 17) or small nodules suggestive of a papillary pattern (fig. 18). True papillary squamous cell carcinoma is rare. Minielly and associates reported five such cases as **verrucous** type; three occurred in the upper esophagus and two in the lower esophagus. One of the latter tumors was in an epiphrenic diverticulum.

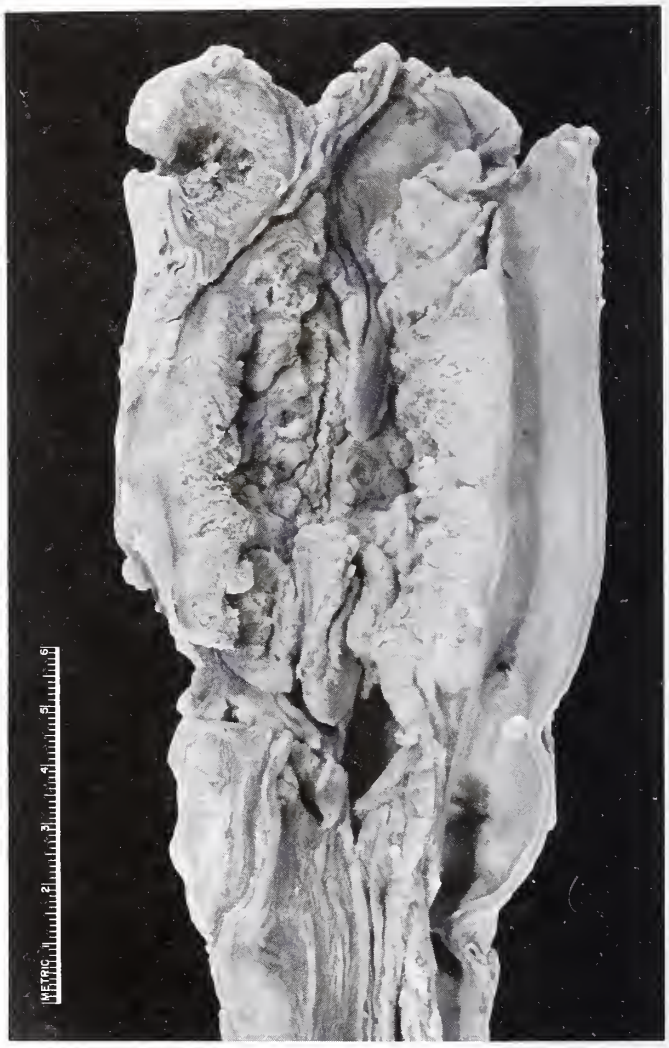

Fig. 13

FUNGATING SQUAMOUS CELL CARCINOMA

This tumor is a well differentiated squamous cell carcinoma found at the midportion of the esophagus in a 46-year-old man. It involved the entire circumference of the esophagus. The surface of the tumor was ulcerated to a variable depth. The tumor penetrated through the esophageal wall and involved the adventitia of the aorta. A large lymph node containing necrotic tumor is seen in the left upper corner.

FUNGATING SQUAMOUS CELL CARCINOMA

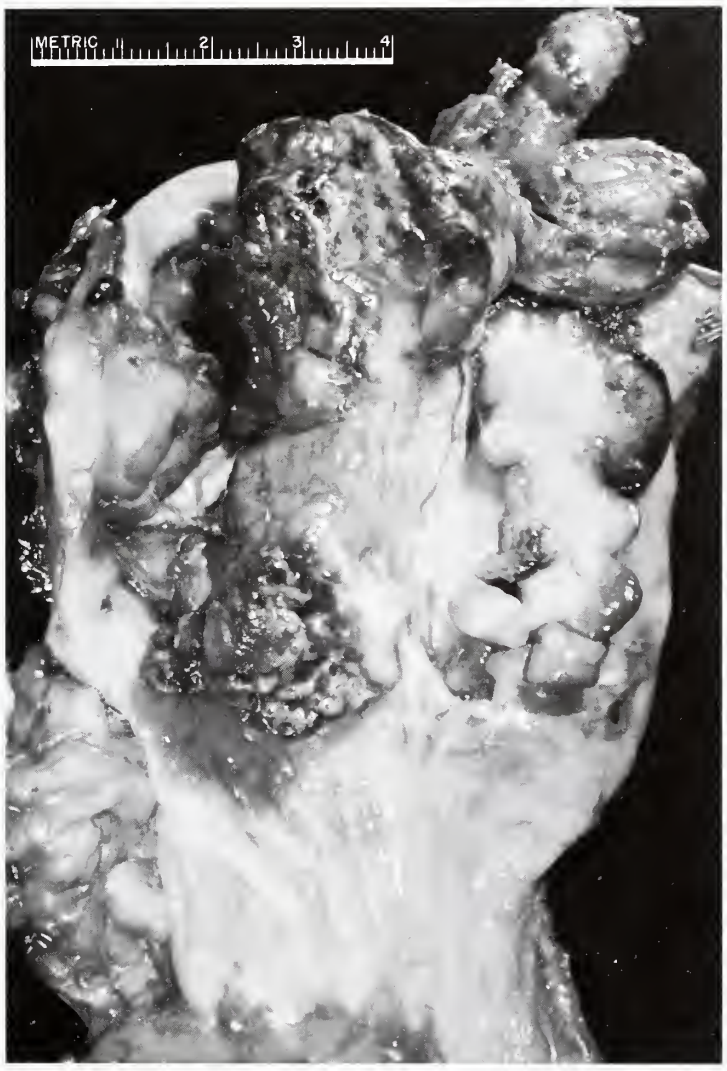

Fig 14

This poorly differentiated carcinoma of the lower esophagus formed polypoid excrescences. The surface of the tumor was hemorrhagic, superficially ulcerated, and necrotic. Normal epithelium surrounded the tumor masses. (Courtesy of The Massachusetts General Hospital, Boston, Mass.)

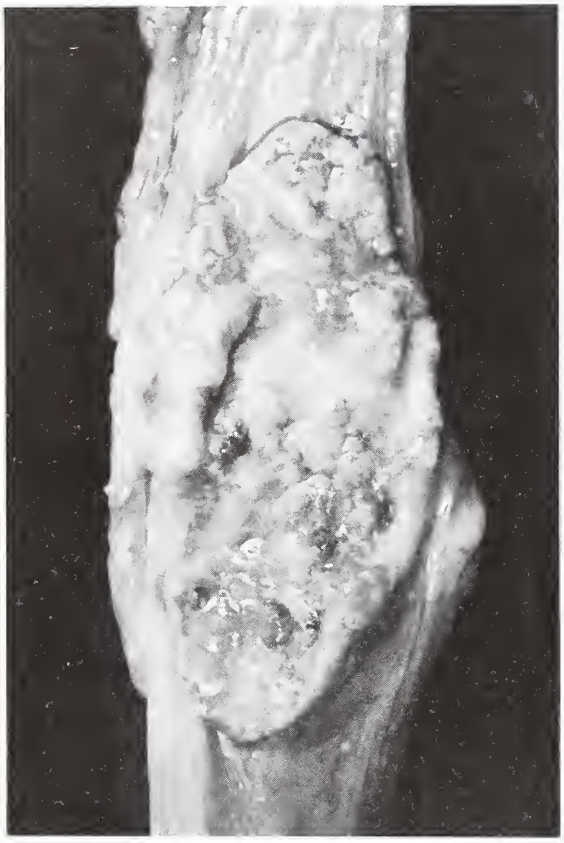

Fig. 15

FUNGATING SQUAMOUS CELL CARCINOMA

This squamous cell carcinoma was found in the mid-esophagus of a 60-year-old man. The tumor was an oval ulcerated plaque of intraluminal growth with everted margins. It had penetrated to the periesophageal connective tissue, and a small nodular mass on the external surface is shown on the right.

Fig. 16

FUNGATING SQUAMOUS CELL CARCINOMA

This carcinoma of the esophagus showed massive intramural extension and invasion. Intraluminal growth was comparatively minor. The esophageal lumen was narrowed due more to the encroachment by intramural growth than the intraluminal mass. (Courtesy of Beth Israel Hospital, Boston, Mass.)

Fig 17

FUNGATING SQUAMOUS CELL CARCINOMA

This esophagogram shows filling defects caused by a fungating carcinoma in the midportion of the esophagus in a 46-year-old man. The radiopaque area within the tumor may represent either a deep ulceration or an area of less tumor involvement.

Fig 18

FUNGATING SQUAMOUS CELL CARCINOMA

This is a radiograph of a carcinoma of the lower esophagus in a 54-year-old woman. The small nodular tumor masses had caused no serious obstruction of the lumen.

The slow growth of verrucous carcinoma was indicated by the case reported by Meyerowitz and Shea; the tumor was demonstrated by radiogram seven years before diagnosis and surgical resection.

Ulcerative carcinoma (pl. I-A) constitutes about 25 percent of cases. The ulcer has a variable depth. It sometimes penetrates through the wall into the mediastinum or the neighboring organs, especially the trachea and bronchus. The ulcer base is shaggy and often hemorrhagic. Its border is irregular and may be slightly overhanging. Expansion of the tumor under the intact, surrounding epithelium results in either a nodular or a raised ulcer margin (figs. 19, 20). The degree of obstruction depends largely upon amount and extent of the intramural growth.

Infiltrating carcinoma is seen in about 15 percent of cases and shows primarily an intramural growth of the tumor (fig. 21), which is usually extensive and burrows under the intact mucosa at its periphery (fig. 22). Less commonly, the tumor spread is superficial. A shallow ulceration is generally present; it is insignificant when compared with the intramural involvement. The rigid tumor-involved segment causes stenosis of the lumen and functional obstruction with dilatation above. The upper border of the stenosed area may either be gradual and funnel-shaped or abrupt and cup-shaped (fig. 23).

Irrespective of the particular form of the tumor, it generally involves a rather long segment of esophagus. The extent of involvement circumferentially, on the other hand, varies from case to case. In fungating and ulcerative carcinoma, the lesion is generally not completely annular and a variable strip of uninvolved esophagus is present in most cases. This feature accounts for the

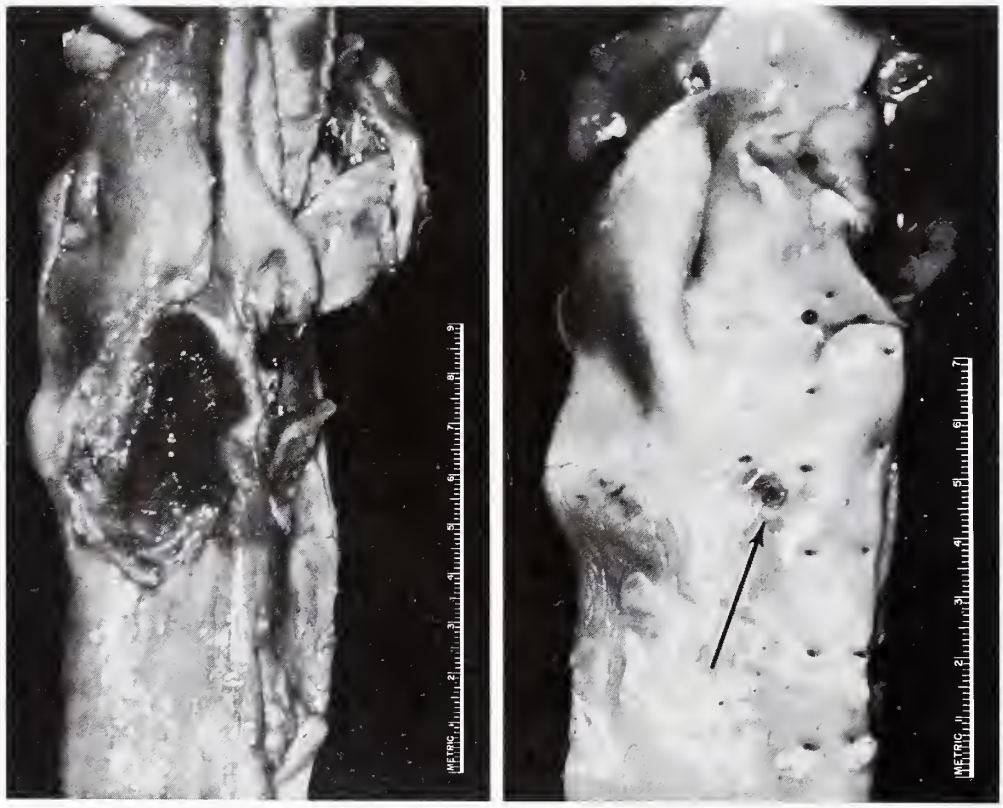

Fig. 19

ULCERATIVE SQUAMOUS CELL CARCINOMA

This ulcerative carcinoma was found in the midesophagus of a 65-year-old woman. The ulcer has a rolled, raised border and a hemorrhagic base. The patient died of massive hemorrhage due to penetration of the ulcer into the aorta, marked by the arrow in the photograph of the aorta shown on the right.

variable radiologic patterns which seemingly may be in discordance with the gross characteristics of the open esophagus. When the infiltrating carcinoma involves the entire circumference of the esophagus, a close correlation is usually possible with the esophagographic configuration.

Fig. 20

ULCERATIVE SQUAMOUS CELL CARCINOMA

This esophagogram of a 56-year-old man shows an ulcerative carcinoma with raised borders. The ulcer crater is indicated by an arrow. The lumen is narrowed by intramural growth, which is not evident in the esophagogram, and the proximal esophagus is dilated.

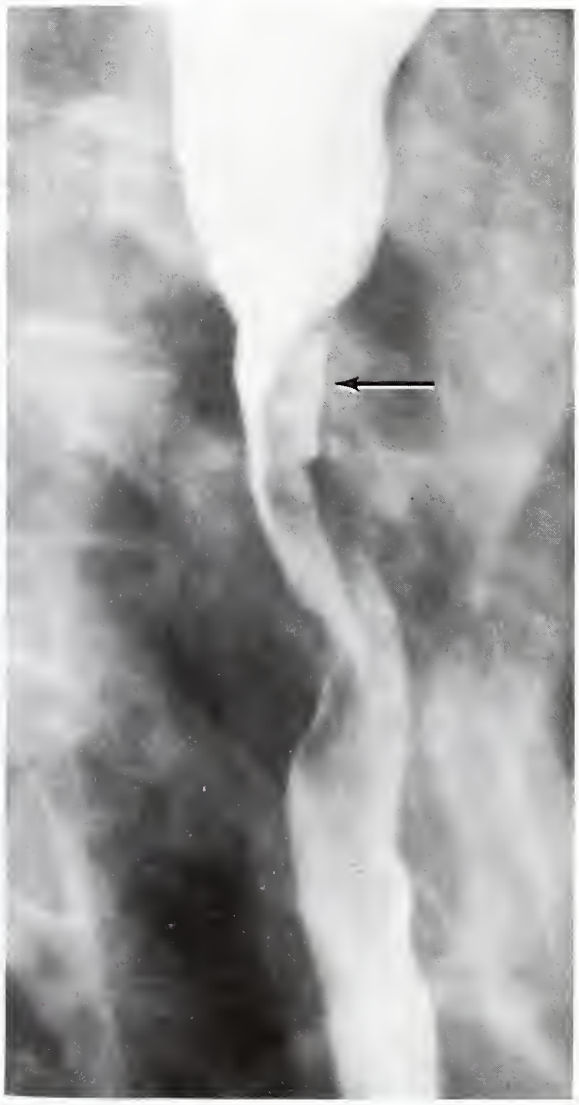

Fig. 20

Fig. 21

Fig. 21

INFILTRATING SQUAMOUS CELL CARCINOMA

An infiltrating carcinoma of the esophagus of a 65-year-old man is illustrated. The tumor is circumferential. The involvement measured 3 cm. in length and the esophageal wall was thickened to 1.5 cm.

Fig 22

INFILTRATING SQUAMOUS CELL CARCINOMA

(Figures 22 and 31 from same case)

This infiltrating carcinoma was found in a 46-year-old man. There was a restricted area of superficial ulceration. The tumor is transmural with a tapering upper limit. It extends under intact mucosa far beyond the ulcerated area, shown best along the cut surfaces. The lumen above the tumor was dilated

Fig 22

Fig 23

Fig 23

INFILTRATING SQUAMOUS CELL CARCINOMA

This esophagogram of a 57-year-old man shows a stenosing infiltrating carcinoma in the lower esophagus with dilatation above the tumor.

HISTOLOGIC FEATURES. Intraepithelial carcinoma is often observed at the border areas of an invasive carcinoma (figs. 24, 25). The histogenetic nature of such a lesion is difficult to ascertain. There is generally further extension of the tumor cells along the basal portion than in the superficial portion of the epithelium, and the junction between the tumor and normal epithelium is abrupt. This gives the impression that it results from tumor growing on the preexisting basement membrane, destroying the normal epithelium in its path. Conversely, a true malignant in situ transformation remains a possibility, especially when it occurs in areas disconnected from the invasive tumor (Suckow et al.). In view of the gross extent of the tumor, it is interesting that in situ carcinoma independent of invasive tumor is a rare phenomenon in the esophagus. In situ carcinoma has been found, only after meticulous sectioning (De la Pava et al.), in patients with Plummer-Vinson syndrome (Entwistle and Jacobs) and in the rare lesions of carcinosarcoma (Stener et al.) and pseudosarcoma (DeMarco et al.). Ushigome and associates reported a case of extensive carcinoma in situ in a totally resected esophagus following biopsy and cytologic diagnosis of squamous cell carcinoma.

In the majority of cases, the invasive tumor is well differentiated (figs. 26, 27), with varying degrees of keratinization within the same tumor. When the focus of keratinization is large, the cells are often degenerated (fig. 26). The nonkeratotic tumor cells may be oval, polyhedral, or spindle-shaped (figs. 28, 29). In some areas, cells adjoining the stroma are arranged in a row, reminiscent of the basal layer of the epidermis (figs. 26, 28).

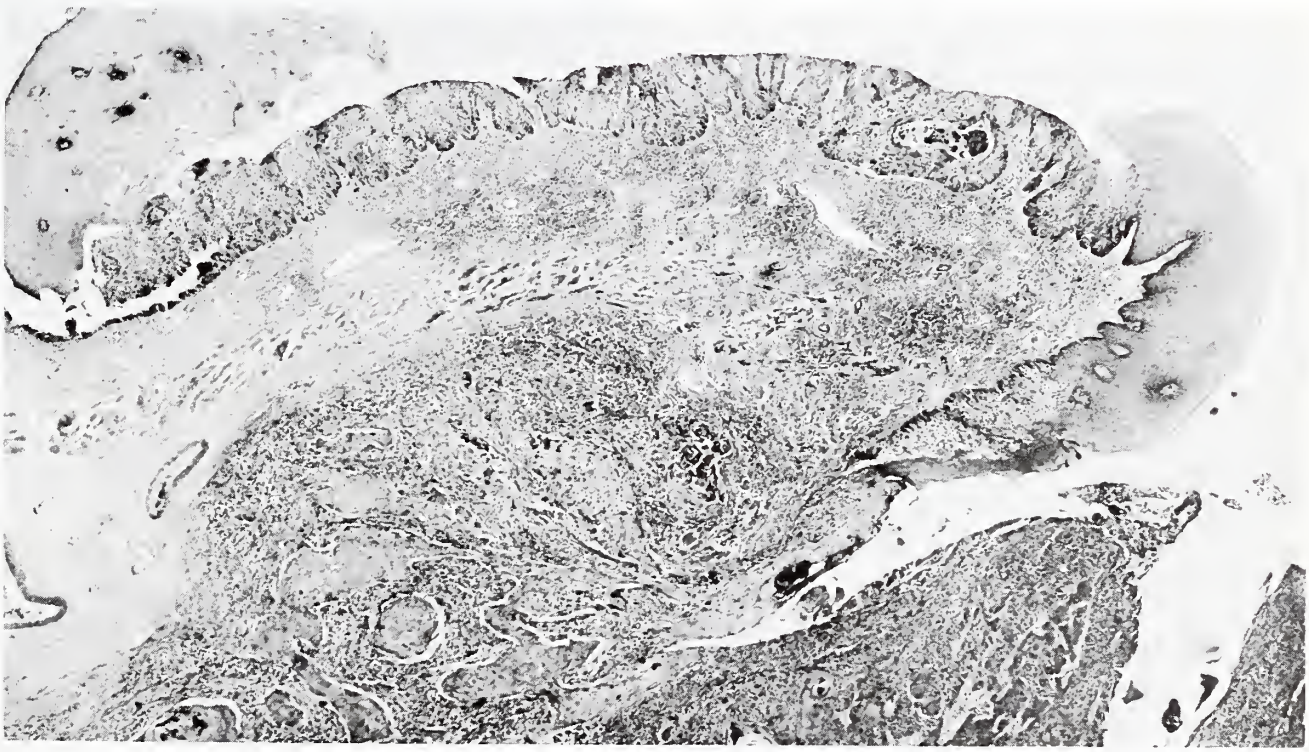

Fig. 24

INTRAEPITHELIAL SQUAMOUS CELL CARCINOMA

(Figures 24 and 25 from same case)

This section of the border area of an invasive squamous cell carcinoma is from a 40-year-old man. It shows intraepithelial carcinoma both in continuity with and separate from the invasive tumor. These two areas of intraepithelial lesion were connected at another level. × 26.

Fig. 25

INTRAEPITHELIAL SQUAMOUS CELL CARCINOMA

(Figures 24 and 25 from same case)

This section shows intraepithelial carcinoma and the contiguous normal squamous epithelium. The tumor cells extend further laterally in the basal portion than in the superficial portion and have a sharply limited junction with the normal epithelium which is also shown in figure 24. These features suggest that the intraepithelial component of the tumor is an extension of tumor growth rather than true in situ malignant transformation. × 140.

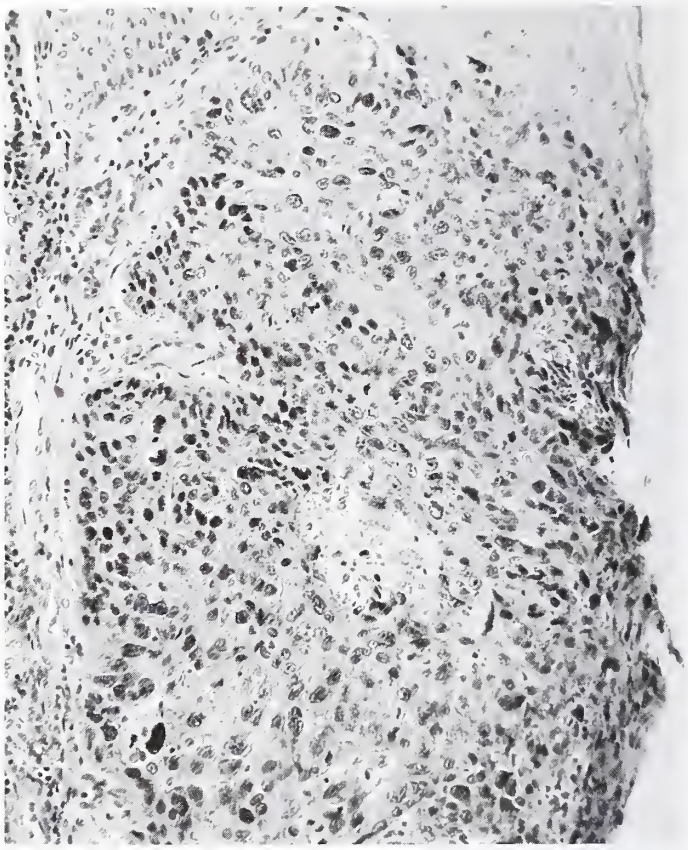

Fig. 25

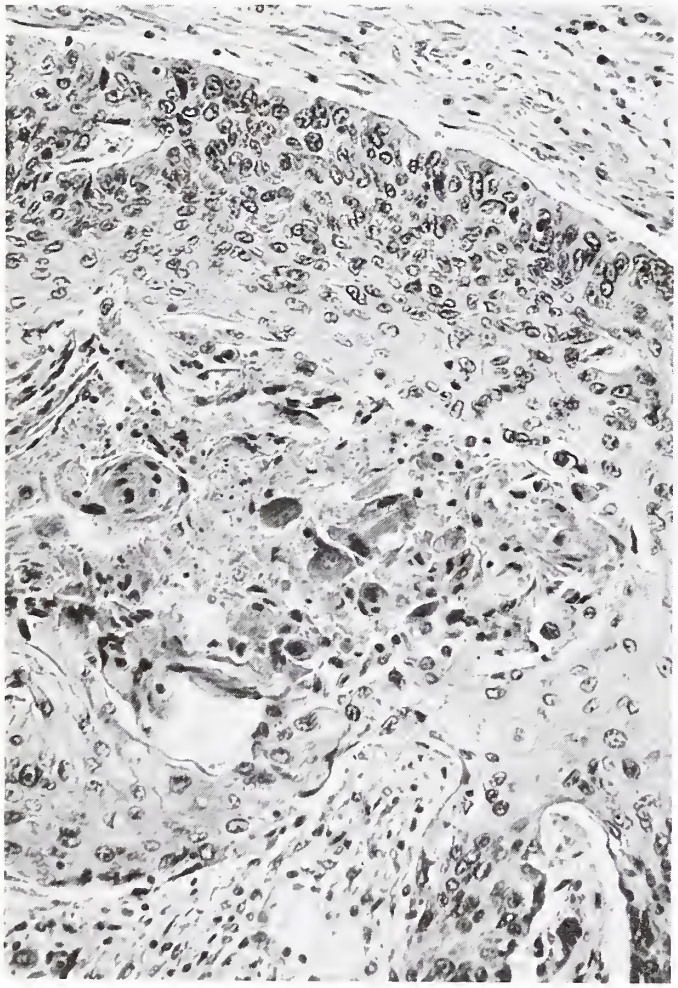

Fig. 26

Fig. 26

SQUAMOUS CELL CARCINOMA

The characteristic histologic appearance of a squamous cell carcinoma is shown. The tumor cells are well differentiated with degenerated keratotic cells in the center of the group. × 200

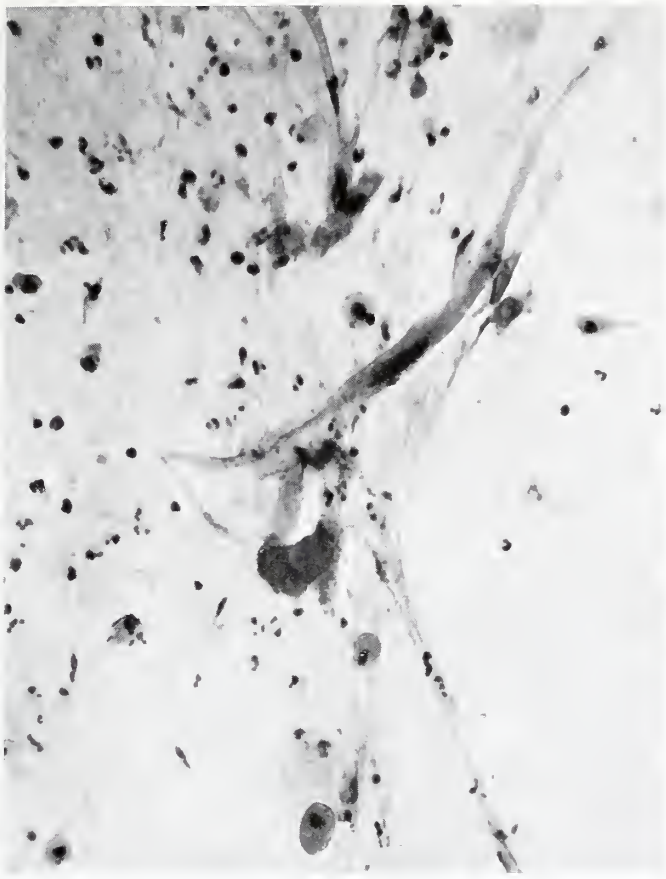

Fig. 27

CYTOLOGIC APPEARANCE OF SQUAMOUS CELL CARCINOMA

These well differentiated squamous carcinoma cells were found in the esophageal washing of a 54-year-old man. The tumor was a fungating carcinoma in the midesophagus. × 250.

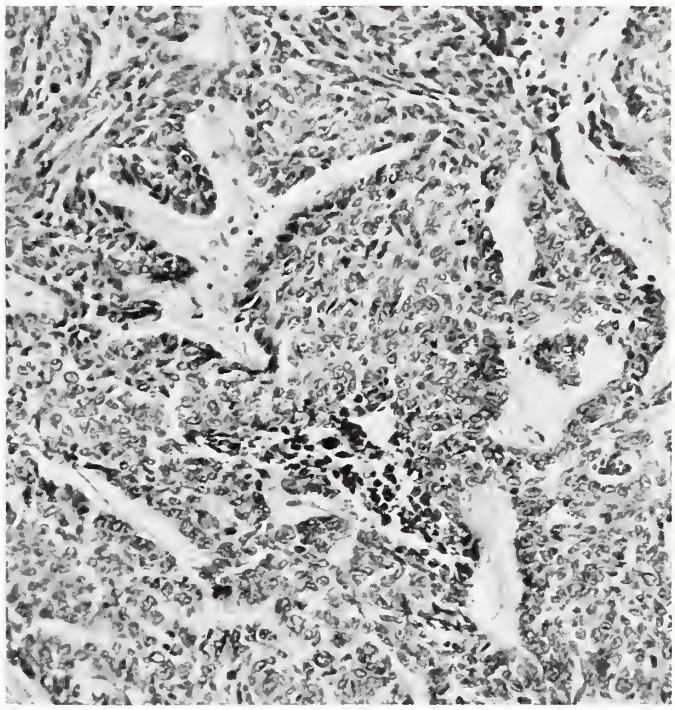

Fig. 28

SQUAMOUS CELL CARCINOMA

The histologic character of a nonkeratinizing squamous cell carcinoma is demonstrated. Some of the tumor cells are spindle-shaped, but most are oval or polyhedral, having a similarity to the cells at the periphery of the group shown in figure 26. × 150.

Fig. 29

CYTOLOGIC APPEARANCE OF SQUAMOUS CELL CARCINOMA

These squamous tumor cells were found in the esophageal washing of a 72-year-old man. They have hyperchromatic nuclei and varying amounts of cytoplasm. The histologic features of the tumor were similar to those shown in figure 28. × 268.

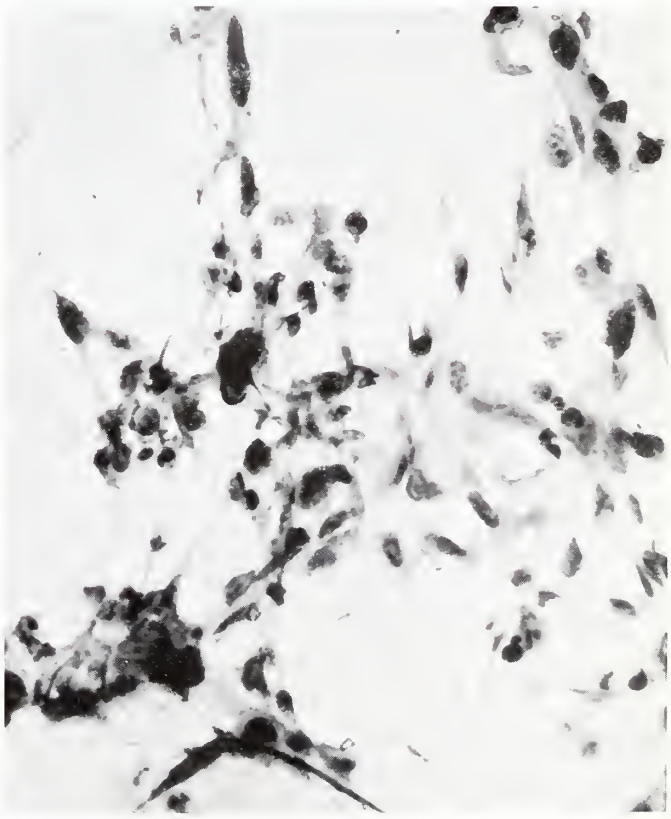

Fig. 29

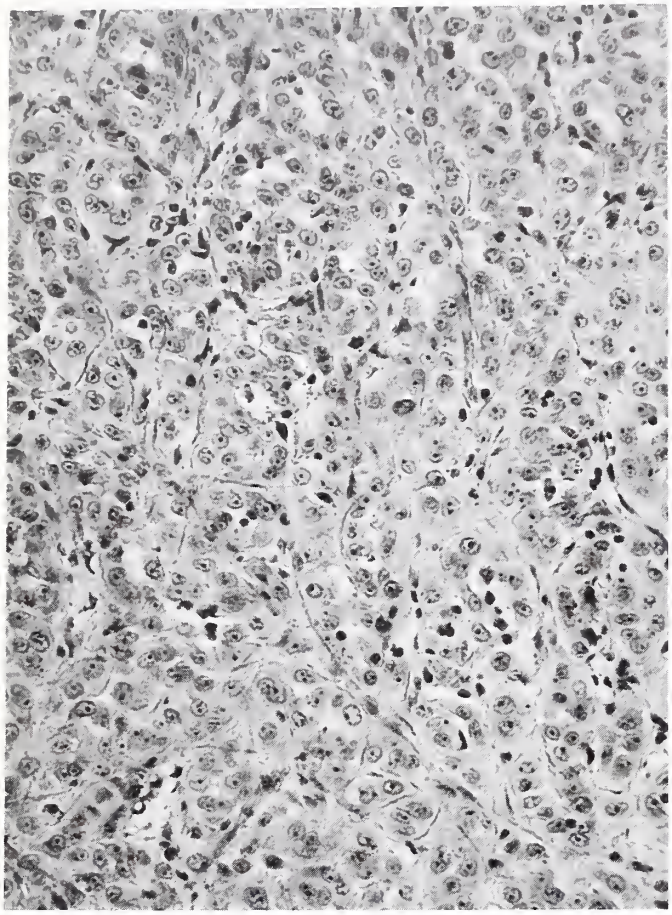

Fig. 30

SQUAMOUS CELL CARCINOMA

This is the histologic appearance of a poorly differentiated squamous cell carcinoma containing cells arranged in closely packed cords. Small spaces were present in the center of some of the cords simulating an adenocarcinoma. × 200

Occasionally, the cells are poorly differentiated, largely polyhedral in shape, and arranged in cords with little stromal tissue between them (fig. 30). The lack of interadherence of these poorly differentiated cells is sometimes manifested by separation of the tumor cells at the center of the cords, giving a false glandular appearance (fig. 31).

The rare undifferentiated carcinoma is probably also squamous cell in origin, since better differentiated squamous tumor cells may be found in some areas. Tumor cells are often small and generally round; some are irregular or elongated, with little cytoplasm, resembling oat cell carcinoma of the lung (figs. 32, 33). The term oat cell carcinoma has sometimes been applied to this tumor. Occasionally, bizarre giant cell forms are also present (fig. 33). Tumor cells infiltrate individually or in small groups. When they form large sheets, necrosis is generally present at the center. The unusual verrucous carcinoma is composed of moderately differentiated squamous cells with a prominent intraepithelial component. Papillary projections have a central fibrous core extending from the lamina propria (fig. 34). The pattern seen in invasive portions of the tumor is similar to that seen in other squamous cell tumors.

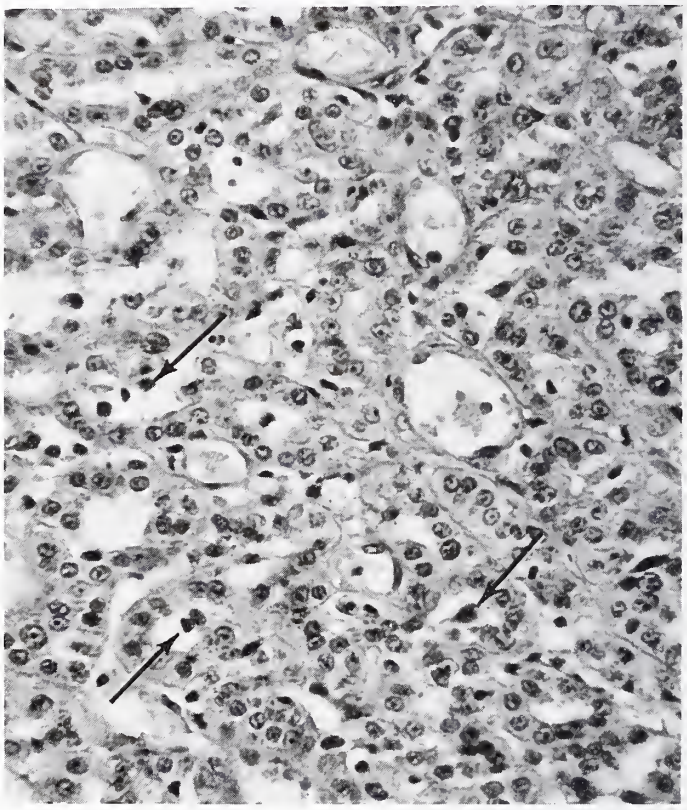

Fig. 31

SQUAMOUS CELL CARCINOMA

(Figures 22 and 31 from same case)

This is the histologic appearance of the infiltrating squamous cell carcinoma shown in figure 22. The prominent separation of the tumor cells in cords gives a false glandular appearance. In such spaces, pyknotic degenerating tumor cells are often present (arrows). In other areas not shown here, the tumor showed well differentiated squamous cells. × 268

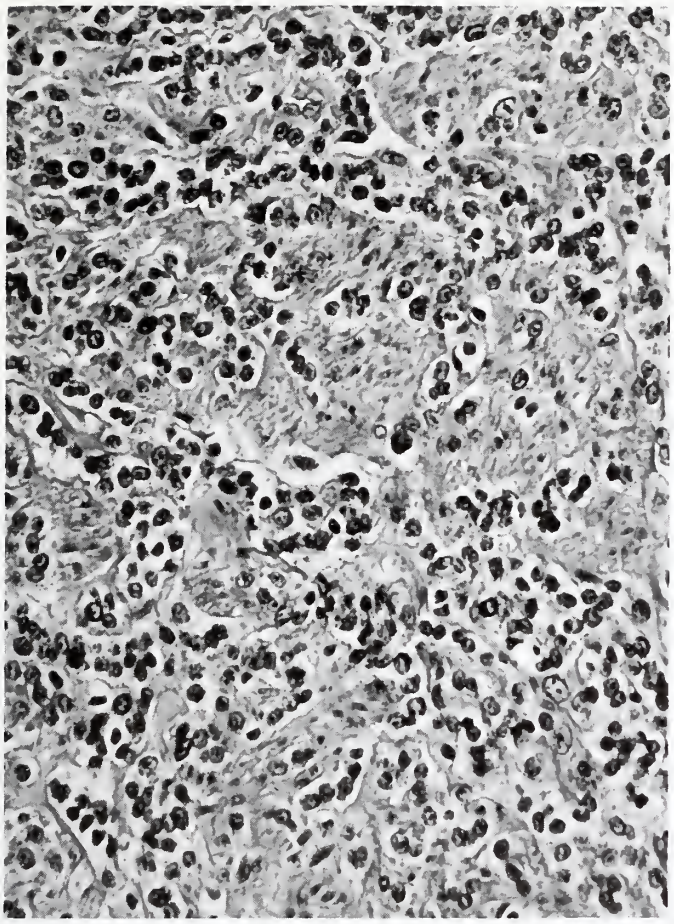

Fig 32

UNDIFFERENTIATED CARCINOMA

An undifferentiated small cell carcinoma of the esophagus reveals infiltration of the muscularis by individual cells and small groups × 268

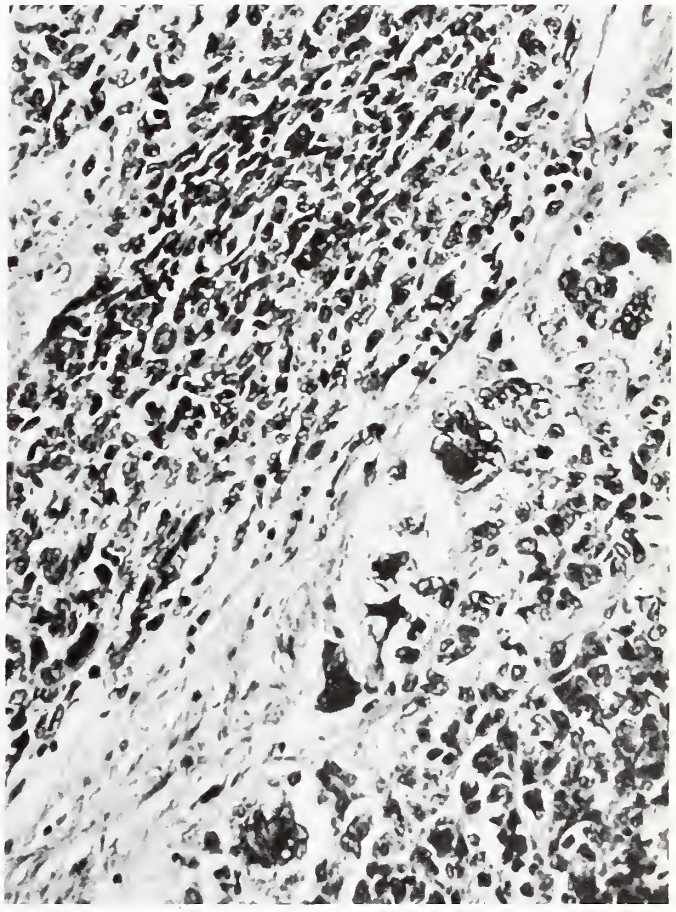

Fig 33

UNDIFFERENTIATED CARCINOMA

Another undifferentiated carcinoma has tumor cells with dark staining, irregular nuclei and indistinct scanty cytoplasm. Some cells are giant forms with multiple nuclei × 192.

Fig 34

VERRUCOUS SQUAMOUS CELL CARCINOMA

An area of verrucous squamous cell carcinoma shows a papillary pattern. Papillary projections are formed by intraepithelial carcinoma cells supported by strands of delicate stromal tissue. In other areas, the tumor had invaded through the wall. × 63

As stated earlier, the carcinoma often extends subepithelially beyond the main body of the tumor, either in continuity with the main tumor or by way of the lymphatic vessels. The resultant satellite tumor nodules may be visible grossly (fig. 35). More commonly, such an extension can only be seen microscopically (fig. 36), especially in the segment cephalad to the tumor (Bergman). This is an especially important factor to be considered if radical resection of the esophagus is undertaken.

No correlation exists between the degree of differentiation and the gross pattern of the tumor or between the histologic grade of the tumor and its prognosis. While it is reasonable to expect greater invasiveness and worse prognosis for a less differentiated tumor, it is meaningless since extensive infiltration and poor prognosis are almost universal in cases of esophageal carcinoma.

References

Bergman, F. Cancer of the oesophagus. A histological study of development and local spread of 10 cases of squamous cell carcinoma in the lower third of oesophagus. Acta Chir. Scand. 117: 356–365, 1959.

De la Pava, S., Pickren, J. W., Cabrera, A., and Studenski, E. Subclinical carcinoma of the esophagus. Study of second primary carcinoma. New York State J. Med. 64: 524–527, 1964.

DeMarco, A. R., Leon, W., Coleman, W. O., Welsh, R. A., and Strug, L. H. Pseudosarcoma of the esophagus. J. Thorac. Cardiovasc. Surg. 49: 188–193, 1965.

Entwistle, C. C., and Jacobs, A. Histological findings in the Paterson-Kelly syndrome. J. Clin. Path. 18:408–413, 1965.

McKeown, F. Oat-cell carcinoma of the oesophagus. J. Path. Bact. 64:889–891, 1952.

Meyerowitz, B. R., and Shea, L. T. The natural history of squamous verrucose carcinoma of the esophagus. J. Thorac. Cardiovasc. Surg. 61:646–649, 1971.

Minielly, J. A., Harrison, E. G., Jr., Fontana, R. S., and Payne, W. S. Verrucous squamous cell carcinoma of the esophagus. Cancer 20:2078–2087, 1967.

Stener, B., Kock, N. G., Pettersson, S., and Zetterlund, B. Carcinosarcoma of the esophagus. J. Thorac. Cardiovasc. Surg. 54:746–750, 1967.

Suckow, E. E., Yokoo, H., and Brock, D. R. Intraepithelial carcinoma concomitant with esophageal carcinoma. Cancer 15:733–740, 1962.

Ushigome, S., Spjut, H. J., and Noon, G. P. Extensive dysplasia and carcinoma in situ of esophageal epithelium. Cancer 20:1023–1029, 1967.

Wu, Y. K., Liu, Y., Hu, M. H., Hu, C. H., Liu, Y. C., Wu, H., Huang, K. C., Liu, T. H., and Chang, T. L. The classification of types of carcinoma of the esophagus, its diagnostic criteria and clinical significance. Chin. Med. J. 76:213–228, 1958.

Fig. 35

SUBMUCOSAL EXTENSION OF CARCINOMA

An ulcerated carcinoma of the midesophagus shows extensive infiltration into the paraesophageal tissue. Subepithelial extension of the tumor is evident proximal to the tumor, forming small nodules covered by intact epithelium.

Fig. 36

LYMPHATIC SPREAD OF CARCINOMA

Intralymphatic squamous tumor cells are present in a grossly normal segment of esophagus, 1.5 cm. from the ulcerative main tumor which measured 3.5 cm., including the submucosal extension. × 85

ADENOCARCINOMA*

SYNONYMS AND RELATED TERMS **Adenoid-cystic carcinoma; mucoepidermoid carcinoma; mucus producing adenocarcinoma; papillary adenocarcinoma**; adenoacanthoma; cylindroma.

Adenocarcinoma involving the esophagus is located principally at the esophagogastric junction. Of 300 cases of adenocarcinoma reported by Ellis and associates, 279 (93 percent) were located at the esophagogastric junction, 11 in the lower thoracic, 8 in the upper thoracic segment, and 2 carcinomas were in the cervical segment of the esophagus. Turnbull and Goodner reported 45 primary adenocarcinomas, located as follows: 2, cervical; 8, upper thoracic; 21, midthoracic; and 14, distal thoracic segments. There were 18 cases of adenocarcinoma in the files at the University of Maryland Hospital; 9 were located at the esophagogastric junction and 9 in the lower thoracic segment.

Adenocarcinoma at the esophagogastric junction is generally considered gastric in origin, arising from the cardiac glands. When it occurs elsewhere in the esophagus, the tumor generally appears to also originate from gastric epithelium, remnants of which are readily found in the vicinity of the tumor. In 1900 Hewlett suggested that in a few cases the tumor might have arisen from superficial cardiac glands normally present in the esophagus. Although the esophagus regularly contains mucous glands, carcinoma arising from them is exceedingly rare. In such cases, the lower end of the esophagus is also the predominant site.

GROSS. The gross characteristics of adenocarcinoma are similar to those of squamous cell carcinoma. Ming and Bullough reported a case showing unusual papillary configuration (figs. 37, 38). Rarely, the tumor is polypoid and resembles a benign lesion (Davis et al.). The esophageal mucosa proximal to the tumor is generally pale gray, smooth and shiny, and easily identifiable as squamous epithelium. The mucosa distal to the tumor, on the other hand, is often soft, pink and velvety, and resembles gastric mucosa (fig. 37). These gross impressions are readily confirmed microscopically. Small islands of squamous epithelium are sometimes present in the distal segment of the esophagus. This arrangement of epithelium supports the viewpoint

Fig. 37

ADENOCARCINOMA

(Figures 37 and 38 from same case)

This papillary adenocarcinoma was found in the lower half of the esophagus beginning at the level of the azygous vein in a 55-year-old woman. The tumor was 7 cm. in length and circumferential. Smooth, pale squamous epithelium is present proximal to the tumor and in small patches distal to it. Most of the mucosa distal to the lesion is identical with the gastric mucosa shown at the lower end where a separate poorly differentiated adenocarcinoma of the cardia was present. (Courtesy of Beth Israel Hospital, Boston, Mass., also fig. 1 from Ming, S.-C., and Bullough, P. G. Coexisting adenocarcinomas of the esophagus and of the esophagogastric junction. Amer. J. Dig. Dis. 8:439–443, 1963.)

that adenocarcinoma arises from aberrant gastric mucosa, irrespective of a congenital or acquired origin.

MICROSCOPIC. The gastric origin of the tumor is evident since in situ malignant changes may be found in the remnants of cardiac epithelium and the morphologic character of the tumor is identical with that seen in gastric carcinoma. The tumor shows varying degrees of glandular differentiation (fig. 39). Moderately developed striated borders and secretion of glycoprotein are present in the well differentiated areas.

A variant of adenocarcinoma shows a concomitant squamous element. It has been called **adenoacanthoma** or **mucoepidermoid carcinoma**, implying its origin is from the deep mucous glands (Stout and Lattes; McPeak and Warren; Azzopardi and Menzies; Kay). The relative proportion of the two components varies from tumor to tumor and from area to area within the same tumor. When the tumor is principally a well differentiated adenocarcinoma and small groups of squamous cells are surrounded by glandular cells (fig. 40), the former are most likely metaplastic and the term adenoacanthoma is applicable. Because of its similarity to other adenocarcinomas, adenoacanthoma probably arises from aberrant gastric epithelium rather than from deep mucous glands. True mucoepidermoid tumors are rare in the esophagus (Azzopardi and Menzies; Dodge; Kay). Like those present in the salivary glands, the mucous cells

Fig 38

ADENOCARCINOMA

(Figures 37 and 38 from same case)

This is the histologic appearance of the papillary adenocarcinoma shown in figure 37. The tumor is limited by the muscularis mucosae. Slightly dilated cardiac glands are present at the base of the tumor, some are connected with the neoplastic epithelium. × 23

are isolated or in small groups, scattered among large groups of squamous cells. The mucoepidermoid tumors of the esophagus show a high degree of malignancy; they are extensively invasive and metastases are generally present as in other types of carcinoma. Both groups are located mainly in the lower esophagus and have no distinctive gross features. Distinct from these tumors are the squamous cell carcinoma, with pseudoglandular degeneration, and the rare composite tumor, with coexisting squamous cell carcinoma and adenocarcinoma arising from separate foci. The former is distinguished by its lack of mucus secretion. In the latter, the tumors occupy separate areas, interdigitating at the junction (Dodge).

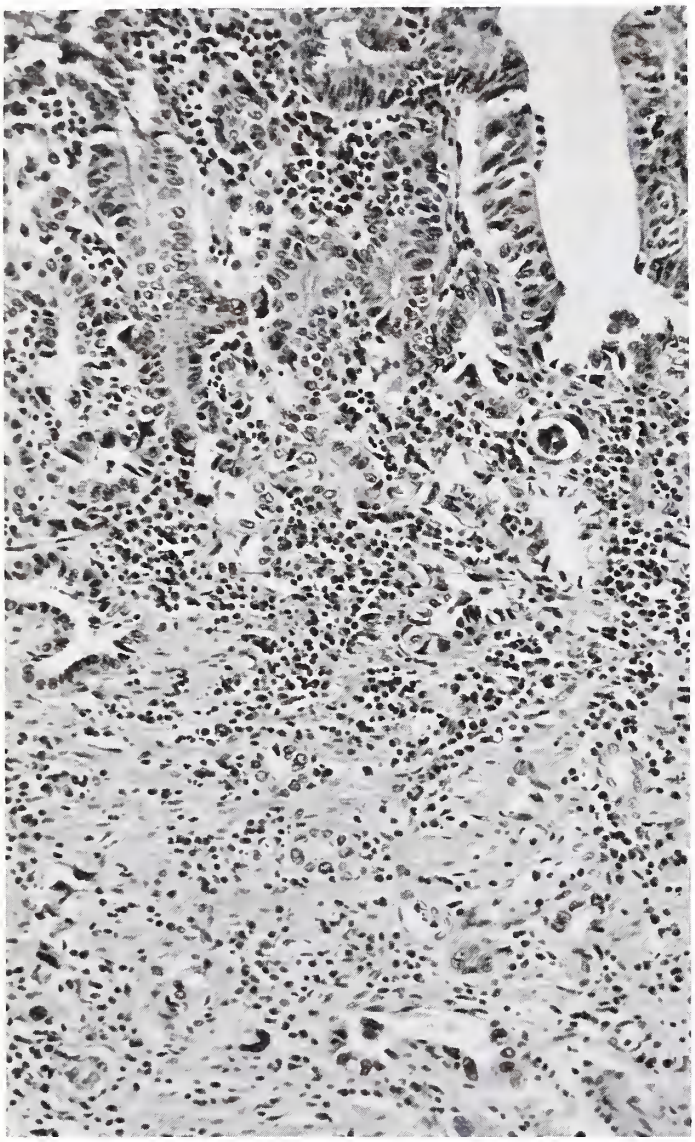

Fig. 39

ADENOCARCINOMA

An infiltrating adenocarcinoma of the lower esophagus shows varying degrees of glandular differentiation and infiltration of chronic inflammatory cells. × 155

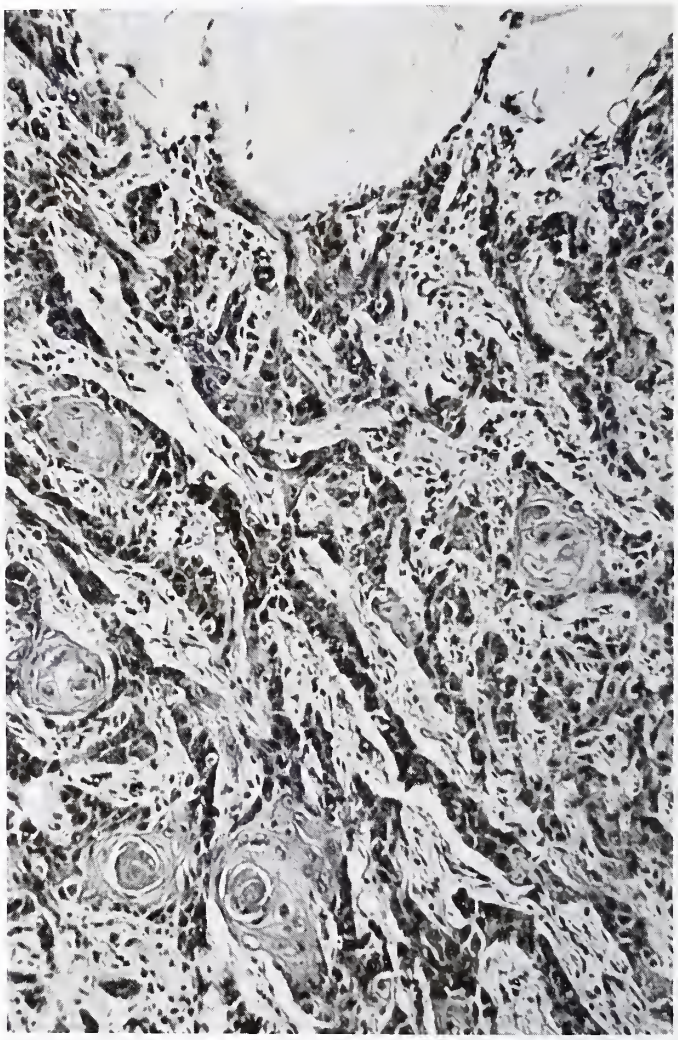

Fig. 40

ADENOACANTHOMA

This adenoacanthoma of the lower esophagus reveals well differentiated squamous cells surrounded by poorly differentiated cells arranged in a tubular pattern. The latter cells are contiguous with pools of mucus secretion seen on top, suggesting a glandular nature. Some tumors in tubular areas contained intracellular mucus. × 119.

Cylindroma or **adenoid-cystic carcinoma** have also been reported. The cases reported by Bergmann and Charnas and by Azzopardi and Menzies showed histologic features identical with those seen in the salivary glands. Similar cases were reported by Lortat-Jacob and associates and by Marcial-Rojas and Vallecillo, but their illustrations revealed only adenocarcinoma. Bergmann and Charnas' case was a tumor in the midesophagus of a 65-year-old man. There was in situ carcinoma in the covering squamous epithelium, but no invasive squamous cell carcinoma was found in the tumor. All four of Azzopardi and Menzies' patients were women; the tumor was found in the midesophagus in three patients and in the lower esophagus in the fourth. The tumors were either fungating or ulcerative. Intramural spread of the tumor was generally extensive and metastases were frequent. The relatively benign course pursued by similar tumors in other areas is not applicable for these esophageal lesions.

McKechnie and Fechner reported a case of **choriocarcinoma** of the esophagus with gonadotropin secretion in a 44-year-old man. The tumor was ulcerated and located at the junction of the middle and lower third of the esophagus. In addition to foci of histologically typical choriocarcinoma, well differentiated adenocarcinoma was also present in the esophageal tumor; only choriocarcinoma was seen in the metastatic lesions in other organs.

References

Azzopardi, J. G., and Menzies, T. Primary oesophageal adenocarcinoma. Confirmation of its existence by the finding of mucous gland tumors. Brit. J. Surg. 49:497–506, 1962.

Bergmann, M., and Charnas, R. M. Tracheobronchial rests in the esophagus. Their relation to some benign strictures and certain types of cancer of the esophagus. J. Thorac. Cardiovasc. Surg. 35:97–104, 1958.

Davis, W. McA., Goodwin, M. N., Jr., Black, H. C., Jr., and Hawk, J. C. Polypoid adenocarcinoma of the cervical esophagus. Arch. Path. 88:367–370, 1969.

Dodge, O. G. Gastro-oesophageal carcinoma of mixed histological type. J. Path. Bact. 81:459–471, 1961.

Ellis, F. H., Jr., Jackson, R. C., Krueger, J. T., Jr., Moersch, H. J., Clagett, O. T., and Gage, R. P. Carcinoma of the esophagus and cardia. Result of treatment, 1946 to 1956. New Eng. J. Med. 260:351–358, 1959.

Hewlett, A. W. The superficial glands of the esophagus. J. Exper. Med. 5:319–331, 1900.

Kay, S. Mucoepidermoid carcinoma of the esophagus. Report of two cases. Cancer 22:1053–1059, 1968.

Lortat-Jacob, J-L., Maillard, J. N., Richard, C. A., Fékété, F., Huguier, M., and Conte-Marti, J. Primary esophageal adenocarcinoma: report of 16 cases. Surgery 64:535–543, 1968.

Marcial-Rojas, R. A., and Vallecillo, L. A. Primary adenoid-cystic carcinoma of the esophagus. Report of one case and review of the literature. Arch. Otolaryng. 70:197–201, 1959.

McKechnie, J. C., and Fechner, R. E. Choriocarcinoma and adenocarcinoma of the esophagus with gonadotropin secretion. Cancer 27:694–702, 1971.

McPeak, E., and Warren, S. Histologic features of carcinoma of the cardio-esophageal junction and cardia. Amer. J. Path. 24:971–991, 1948.

Ming, S.-C., and Bullough, P. G. Coexisting adenocarcinomas of the esophagus and of the esophagogastric junction. Amer. J. Dig. Dis. 8:439–443, 1963.

Stout, A. P., and Lattes, R. Tumors of the Esophagus. Fascicle 20, Atlas of Tumor Pathology. Washington: Armed Forces Institute of Pathology, 1957.

Turnbull, A. D. M., and Goodner, J. T. Primary adenocarcinoma of the esophagus. Cancer 22:915–918, 1968.

CARCINOMA AT THE ESOPHAGOGASTRIC JUNCTION

The esophagogastric junction offers no barrier to extension of carcinoma. Tumor arising primarily in one organ penetrates freely into the other, not only intramurally but also mucosally.

Squamous cell carcinoma comprises only 3 to 10 percent of the tumors at this location (McPeak and Warren; Zacho and Fischermann). It is located primarily in the esophagus. Adenocarcinoma, on the other hand, shows a predilection for the esophagus in 17 percent of cases, the stomach in 60 percent, and equal involvement of the two areas in the remainder of cases (Dodge).

Adenoacanthoma and mucoepidermoid carcinoma constitute 2 to 4 percent of the tumors (Dietrich et al.; Dodge). About 6 percent

of the tumors are anaplastic. Rarely, do the tumors appear to have dual origin. Dodge reported two cases showing coexistent mucoepidermoid carcinoma and adenocarcinoma in continuity; in one case there was anaplastic carcinoma and adenocarcinoma separated by a narrow zone of normal esophagus.

GROSS. Irrespective of their histologic character, these carcinomas may be fungating (fig. 41) or infiltrating (fig. 42; pl. I – B) with varying degrees of ulceration. Stenosis may be present.

Fig. 41

SQUAMOUS CELL CARCINOMA AT THE ESOPHAGOGASTRIC JUNCTION

This is the longitudinal section of a squamous cell carcinoma removed from a 58-year-old man. The pale tumor tissue extends through the muscularis into the surrounding tissue at the esophagogastric junction and projects into the cardia of the stomach. The upper portion of tumor is covered by intact esophageal mucosa.

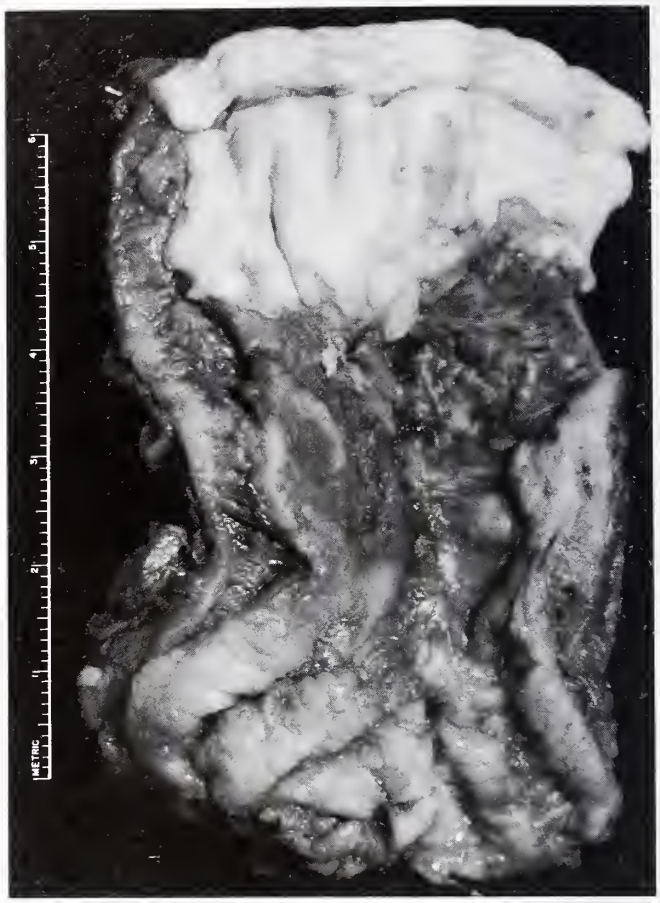

Fig. 42

ADENOCARCINOMA AT THE ESOPHAGOGASTRIC JUNCTION

This infiltrating adenocarcinoma located at the esophagogastric junction was excised from a 63-year-old woman. The tumor is superficially ulcerated and the lumen slightly narrowed.

MICROSCOPIC. Squamous cell carcinoma shows no unusual features microscopically. Adenocarcinoma generally shows moderate glandular differentiation (fig. 43). Subepithelial extension beyond the main tumor is common (fig. 44). Another frequent observation is the intermittent extension of the tumor tissue through squamous epithelium, forming small discrete nodules with compressed squamous epithelium around and partially covering it (figs. 45, 46). The base of the tumor nodules may or may not connect with tumor tissue in the adjacent area. While it is probable that these nodules are formed by a

random expansion of the tumor, it remains possible that they represent multicentric neoplastic transformation of superficial cardiac glands. In other areas, the cancerous glands, and occasionally squamous cells, may punctuate the squamous epithelium (fig. 47) in a fashion similar to that of the ducts of deep mucous glands. It appears that in rare instances both adenocarcinoma and squamous cell carcinoma may originate from the deep mucous glands and extend to the surface along the ducts, although this is difficult to ascertain unless in situ malignant change can be demonstrated in these glands.

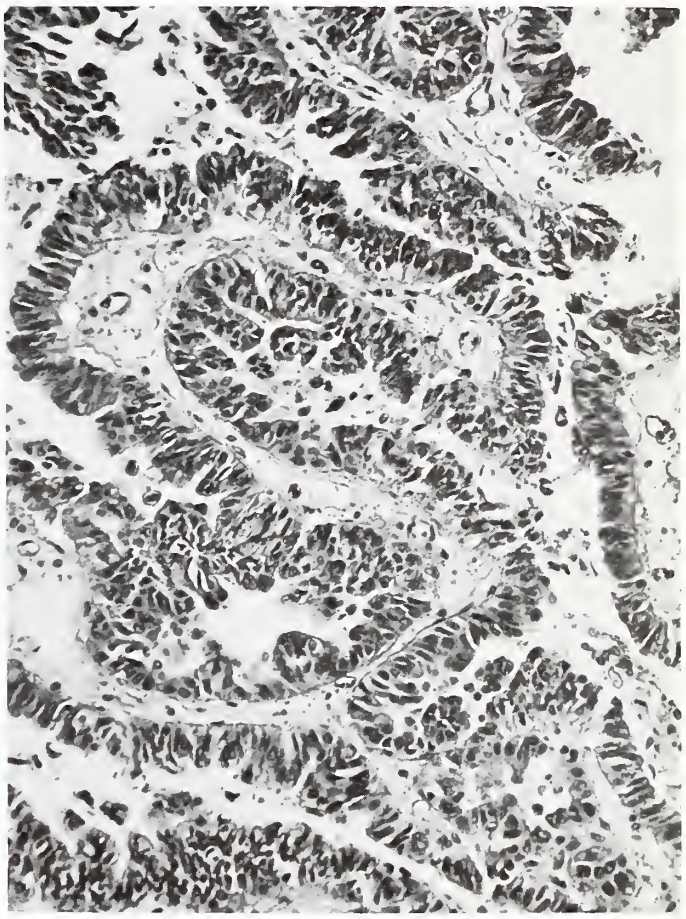

Fig 43

Fig 43

ADENOCARCINOMA AT THE ESOPHAGOGASTRIC JUNCTION

This is the histologic appearance of an adenocarcinoma at the esophagogastric junction. The tumor cells form well developed glands. × 150

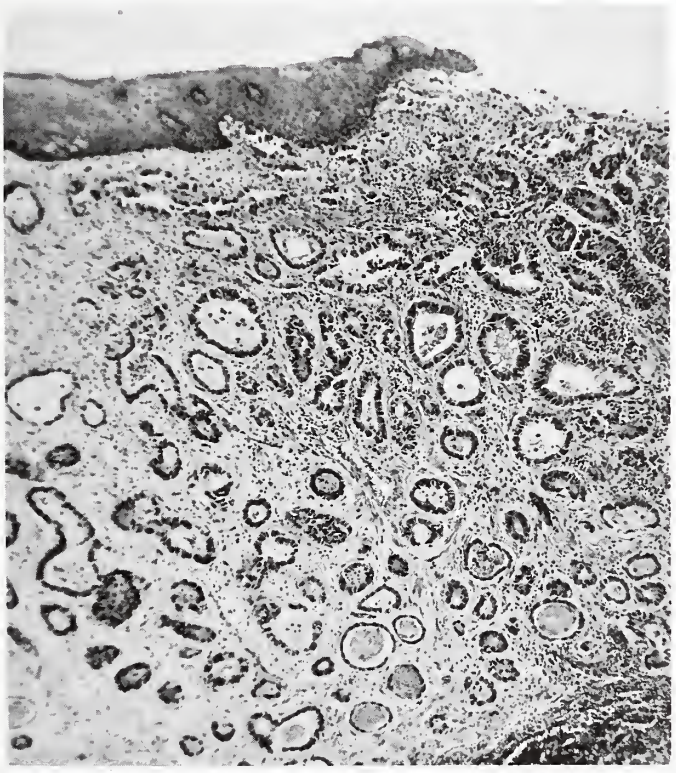

Fig 44

Fig 44

SUBEPITHELIAL EXTENSION OF ADENOCARCINOMA

This photomicrograph shows subepithelial extension into the esophagus by a well differentiated adenocarcinoma at the esophagogastric junction. × 45

Fig. 45

ADENOCARCINOMA AT THE ESOPHAGOGASTRIC JUNCTION

(Figures 45 and 46 from same case)

This tumor nodule in the esophagus is part of a moderately differentiated adenocarcinoma at the esophagogastric junction. It is separated from a similar area at the left by compressed squamous epithelium, portions of which also cover the margins of the nodule. The base of the tumor is delimited by chronic inflammatory infiltration of the submucosa. These nodules were not connected with the invasive main tumor, suggesting separate origin of carcinoma, probably from the superficial esophageal glands. × 18

Fig. 46

ADENOCARCINOMA AT THE ESOPHAGOGASTRIC JUNCTION

(Figures 45 and 46 from same case)

This is a higher magnification of the superficial portion of the tumor shown in figure 45. The tumor cells are well differentiated and show a striated border. × 216.

Fig. 46

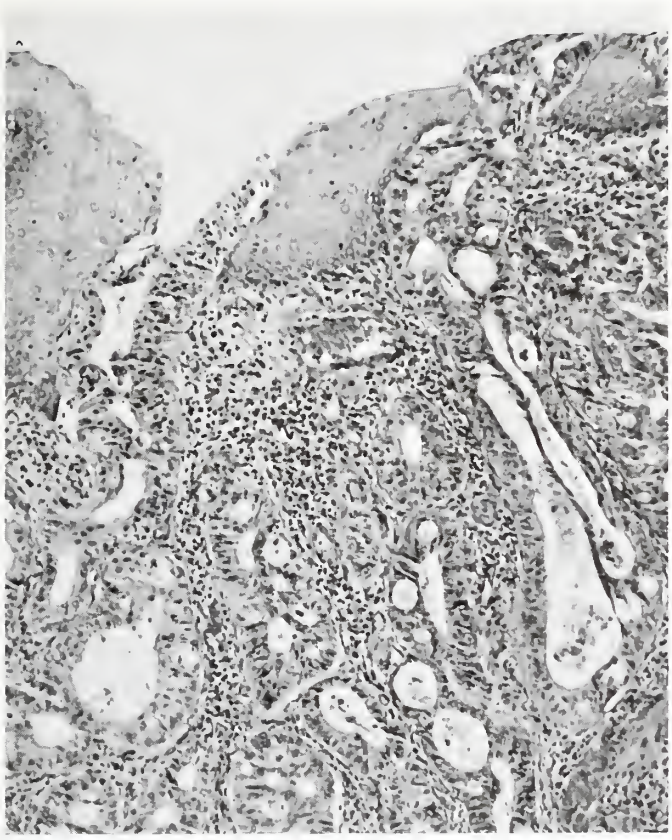

Fig. 47

ADENOCARCINOMA AT THE ESOPHAGOGASTRIC JUNCTION

This section is from the esophageal end of an adenocarcinoma found at the esophagogastric junction of a 68-year-old man. The tumor cells penetrate the squamous epithelium in a fashion resembling the ductal opening of the deep mucous gland. × 90

References

Dietrich, R. A., Dockerty, M. B., Olsen, A. M., and Ellis, F. H., Jr. Clinicopathologic study of carcinoma involving the esophagogastric junction. Surg. Gynec. Obstet. 118:1223–1233, 1964.

Dodge, O. G. The surgical pathology of gastro-oesophageal carcinoma. Brit. J. Surg. 49:121–125, 1961.

McPeak, E., and Warren, S. Histologic features of carcinoma of the cardio-esophageal junction and cardia. Amer. J. Path. 24:971–991, 1948.

Zacho, A., and Fischermann, K. Surgical treatment of malignancies of the oesophago-gastric junction. Acta Chir. Scand. Suppl. 356:121–129, 1965.

MULTIPLE CARCINOMAS

Widespread intraepithelial carcinoma contiguous with or independent of invasive carcinoma (Suckow et al.) and in association with diffuse dysplasia (Ushigome et al.) indicates the possible multicentric origin of esophageal carcinoma. The almost universally observed extensive nature of the carcinoma at the time of diagnosis, despite the brief duration of clinical manifestations, also suggests a multicentric origin. Yet, multiple independent carcinomas are infrequent. One example is shown in figure 48. Two separate carcinomas were present in 10 of 421 cases of squamous cell carcinoma of the esophagus studied by Moertel and associates. A case of Paget's disease of the esophagus coexisting with a squamous cell carcinoma in the distal esophagus was reported by Yates and Koss. Infrequently, carcinoma of the distal esophagus is accompanied by a separate carcinoma at the esophagogastric junction or cardia (Dodge; Golby and Codling; Ming and Bullough; Peison). Carcinoma has also been reported in the esophageal replacement following resection of a carcinoma; one occurred in a prethoracic skin tube 21 years after esophageal resection (Bromberg et al.), and another, a villous adenocarcinoma in a colon bypass, appeared two years after esophageal resection for squamous cell carcinoma (Goldsmith and Beattie). More commonly, esophageal carcinoma is associated with carcinomas in other organs, especially the oral cavity. Among 356 cases of esophageal carcinoma analyzed by Smithers and Payne, 27 patients had carcinoma in other locations, 11 of which were in the oral cavity. Goodner and Watson noted a similar incidence among 1,315 esophageal cancer patients: 126 of these had cancer in other organs, half of which were in the oral cavity.

References

Bromberg, B. E., Song, I. C., Mishrick, A., and Collins, R. Carcinoma in a reconstructed esophagus. Ann. Surg. 168:269–273, 1968.

Dodge, O. G. Gastro-oesophageal carcinoma of mixed histological type. J. Path. Bact. 81:459–471, 1961.

Fig 48

MULTIPLE CARCINOMA

This photograph shows the entire length of the esophagus of an elderly man. There was a fungating carcinoma at the upper end and an ulcerated carcinoma near the lower end. The arrow points to a superficial ulcerated carcinoma. All three tumors were squamous cell carcinomas with preinvasive lesions at their periphery.

Golby, M., and Codling, B. W. Coincidental carcinoma of oesophagus and stomach. Brit. J. Surg. 56:601–603, 1969.

Goldsmith, H. S., and Beattie, E. J., Jr. Malignant villous tumor in a colon bypass. Ann. Surg. 167:98–100, 1968.

Goodner, J. T., and Watson, W. L. Cancer of the esophagus. Its association with other primary cancers. Cancer 9:1248–1252, 1956.

Ming, S.-C., and Bullough, P. G. Coexisting adenocarcinomas of the esophagus and of the esophagogastric junction. Amer. J. Dig. Dis. 8:439–443, 1963.

Moertel, C. G., Dockerty, M. B., and Baggenstoss, A. H. Multiple primary malignant neoplasms. III. Tumors of multicentric origin. Cancer 14:238–248, 1961.

Peison, B. Simultaneous adenocarcinoma of the esophagus and stomach. Illinois Med. J. 134:742–747, 1968.

Smithers, D. W., and Payne, P. M. Analysis of the Patients with Carcinoma of the Oesophagus seen at the Royal Marsden Hospital, 1936 – 1954, pp. 310 – 328. In: Tumours of the Oesophagus. (Eds.) Tanner, N. C., and Smithers, D. W. Edinburgh & London: E. & S. Livingstone, Ltd., 1961.

Suckow, E. E., Yokoo, H., and Brock, D. R. Intraepithelial carcinoma concomitant with esophageal carcinoma. Cancer 15:733–740, 1962.

Ushigome, S., Spjut, H. J., and Noon, G. P. Extensive dysplasia and carcinoma in situ of esophageal epithelium. Cancer 20:1023–1029, 1967.

Yates, D. R., and Koss, L. G. Paget's disease of the esophageal epithelium. Report of first case. Arch. Path. 86:447–452, 1968.

DIFFERENTIAL DIAGNOSIS. The large fungating and ulcerative carcinomas of the esophagus generally offer no difficulty in establishing a correct diagnosis. Sarcomas and carcinosarcomas may resemble carcinomas in their gross features. Most of these tumors, however, are large polypoid masses with a relatively smooth contour and narrow base (pl. I – D); some are pedunculated. The small nodular carcinomas may resemble a benign tumor, grossly. Fortunately, such instances are rare and the microscopic features are easily distinguishable. Difficulty sometimes arises when biopsy of a polypoid tumor reveals only intraepithelial or focally invasive squamous cell carcinoma. In such cases, a majority will show invasive

squamous cell carcinoma in the main tumor. In rare instances, the carcinoma may only be a superficial or minor component, whereas the main tumor may be a polyp, benign tumor, sarcoma, or carcinosarcoma. Likewise, the presence of sarcomatous tissue in a biopsy does not exclude the existence of squamous cell carcinoma in or near the main tumor. These aspects will be discussed further in the sections in which these other tumors are presented.

An infiltrating stenotic carcinoma should be differentiated from benign strictures. The long duration of clinical manifestations and a history of ingestion of corrosive substances favor the latter diagnosis. The gross features of a benign stricture include: the absence of an intraluminal mass, a rubbery but not hard consistency, a homogenous and bulging light gray cut surface, uniform and circumferential involvement (fig. 49), and pronounced dilatation of the proximal segment (fig. 50). The differentiation between benign and malignant stenotic lesions may be difficult, however,

Fig 49

BENIGN STRICTURE

This benign stricture was located at the esophagogastric junction. The involvement is circumferential. The cut surface bulges slightly and shows light homogenous fibrous tissue (arrows). The mucosal aspect is focally ulcerated and lacks an intraluminal mass. (Courtesy of Beth Israel Hospital, Boston, Mass.)

Fig 50

BENIGN STRICTURE

This is another case of benign stricture of the esophagus at the lower end of the specimen with marked dilatation of the lumen above the stricture. (Courtesy of The Massachusetts General Hospital, Boston, Mass.)

and the final diagnosis rests upon the histologic features. When benign stricture is complicated by carcinoma, the lesion will assume the characteristics of the latter, obliterating other features of benignity except the marked dilatation of the lumen proximal to the tumor.

SPREAD OF CARCINOMA AND COMPLICATIONS. Despite the strategic position of the esophagus in relation to ingestion of food and the small caliber of the tube, symptoms of the disease occur relatively late considering that the carcinoma is already extensive when recognized. Rapid invasiveness of the tumor is amply demonstrated by its size and the extent of microscopic invasion. The frequent presence of submucosal tumor in the grossly normal portions some distance from the main lesion constitutes a potential hazard for incomplete surgical removal and its subsequent recurrence. This is particularly important when treating a potentially curable cancer having limited penetration with no evidence of metastasis.

Of the 32 surgically resected carcinoma specimens examined at the University of Maryland Hospital, lymph node metastases were present in 41 percent of cases, extension into periesophageal connective tissue in 38 percent, and both lymph node and periesophageal involvement occurred in 16 percent of cases. In 37 percent of the specimens, the tumor was confined to the esophageal wall. These findings may be misleading, however, since radical excision of lymph nodes is not generally performed because of their location. More extensive spread of the cancer is noted in autopsied cases even though death often occurs shortly after surgery. There were 54 autopsied cases at the University of Maryland Hospital; six of the patients died within days after surgery and no tumor was found at autopsy. Of the remaining 48 cases, only three revealed no tumor; two of these patients were treated with cobalt-60, two and six months prior to death, and the remainder had

Fig. 51

CARCINOMA INVADING TRACHEA AND BRONCHUS

An ulcerative squamous cell carcinoma of the esophagus invaded the bifurcation of the trachea and the left main bronchus

had esophagectomy for carcinoma in the upper third segment of the esophagus five years earlier. Tumor was present locally in the remaining 45 cases (94 percent). In 30 cases (62 percent) the tumor extended into neighboring organs. The tracheobronchial tree was invaded in 13 cases (figs. 51, 52), resulting in an esophagotracheal fistula in five and esophagobronchial fistula in two. Extensive mediastinal involvement was present in eight, one of which was further complicated by an esophageal fistula. Fistulas also developed between the esophagus and lung in two other cases (fig. 53). Extensive mediastinitis, pneumonia, and abscess formation were common in these cases. The aorta was penetrated by tumor

in seven cases; in two of these it ruptured, resulting in fatal massive bleeding into the digestive tract (fig. 19). Metastases to lymph nodes were present in 30 cases (62 percent), 16 of which also showed extension into neighboring structures. Metastases to distant organs were found only in those cases showing lymph node involvement; among them, the liver and lung were most often involved. A similar distribution of metastases was found in a much larger series analyzed by Dormanns (Table IV).

Fig 52

Fig 52

CARCINOMA INVADING TRACHEA

This illustrates extension of an esophageal carcinoma into the trachea forming an unusual nodular intraluminal mass just above the bifurcation. The patient also had achalasia of the esophagus. (Courtesy of Beth Israel Hospital, Boston, Mass.)

Fig 53

Fig. 53

CARCINOMA WITH ESOPHAGOPULMONARY FISTULA

An ulcerative carcinoma in the midesophagus extended through the pleura into the left lung. Deep ulceration resulted in the development of an esophagopulmonary fistula (arrow) and lung abscess.

Table IV
DISTRIBUTION OF METASTASES FROM CARCINOMA OF THE ESOPHAGUS AT AUTOPSY

Site	824 Cases (%) (Dormanns)	48 Cases (%) (University of Maryland Hospital)
Lymph nodes		
Mediastinal	406 (49%)	30 (62%)
Abdominal	236 (29%)	20 (42%)
Paratracheal and paraesophageal	220 (27%)	13 (27%)
Supraclavicular	38 (5%)	14 (29%)
Infraclavicular	7	8 (17%)
Liver	264 (32%)	12 (25%)
Lung and pleura	176 (21%)	15 (31%)
Bone	68 (8%)	3
Kidney	59 (7%)	3
Omentum and peritoneum	44 (5%)	5
Adrenal	35 (4%)	3
Stomach	34 (4%)	3
Heart and pericardium	33 (4%)	1
Intestines	17	1
Thyroid	15	4
Pancreas	15	4
Spleen	14	0
Larynx, trachea, bronchus	13	0
Central nervous system	7	2
Diaphragm	5	4

In both series, metastases were absent in 38 percent of cases at autopsy. Ochsner and DeBakey also noted that 40 percent of 1,025 reported autopsied cases showed no metastases. In these cases, death was associated with extension of tumor into the mediastinum and neighboring structures. The organs involved are related to the level of carcinoma in the esophagus (fig. 54). Local extension is most common in carcinomas of the upper esophagus (60 percent) and least common in the lower esophagus (34 percent), as shown in Table V. This feature determines in part the surgical resectability of the tumor in different segments of the esophagus. The frequency of metastases, on the other hand, is virtually identical among all cases. According to Humphrey and Cliffton, squamous cell carcinomas in the distal esophagus and cardia were less likely to have lymph node metastases than adenocarcinomas (26 and 46 percent of cases, respectively), whereas involvement of adjacent tissue occurred with about equal frequency for each group (33 percent). Dietrich and associates found lymph node metastases in 60 percent of squamous cell carcinomas and metastases in 80 percent of adenocarcinomas at the esophagogastric junction. All these were surgical cases.

LOCAL SPREAD OF CARCINOMA

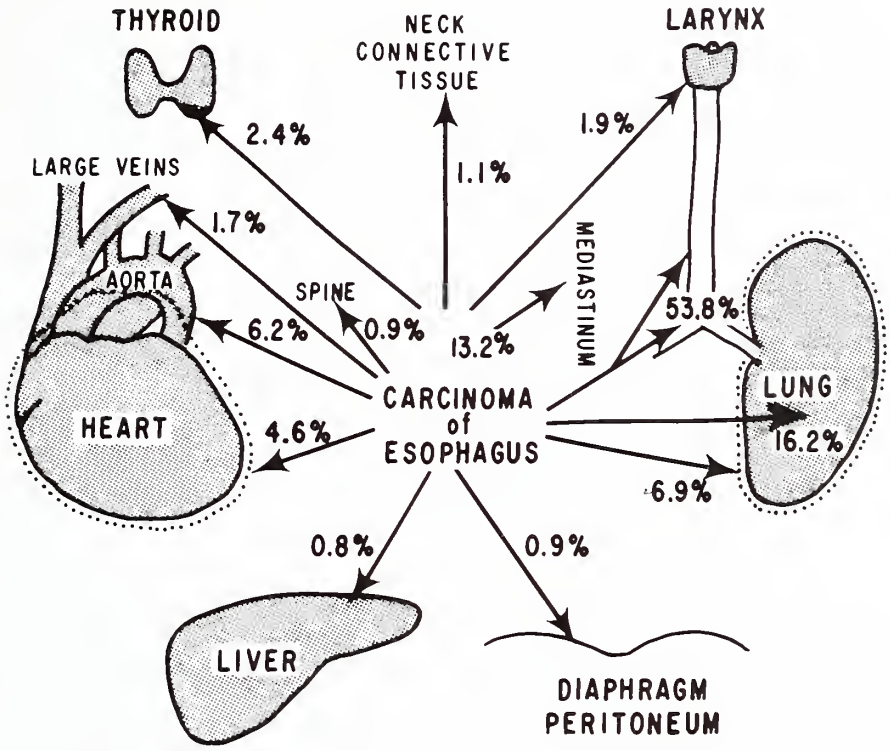

Fig. 54

This diagram indicates the percentage of cases in which neighboring organs were involved by direct extension of esophageal carcinoma The level of carcinoma in the esophagus dictated the organs involved The neck organs were infiltrated only by tumors in the upper esophagus, the thoracic organs at the level of bifurcation of trachea by tumors in the midesophagus, and subdiaphragmatic tissue was involved by tumors in the distal esophagus Superior mediastinal tissue was invaded by both upper and midesophageal carcinomas, and the inferior mediastinal tissue was infiltrated by both middle and lower esophageal carcinomas (Dormanns, E. Data from. Das Oesophaguscarcinom Ergebnisse der unter Mitarbeit von 39 pathologischen Instituten Deutschlands durchgeführten Erhebung über das Oesophaguscarcinom (1925–33). Z. Krebsforsch. 49.86–108, 1939.)

Table V
ESOPHAGEAL CARCINOMA SHOWING METASTASIS AND LOCAL EXTENSION BEYOND ESOPHAGUS ACCORDING TO LEVEL OF CARCINOMA*

	Number of Cases			Total
	Esophagus			
	Upper	Middle	Lower	
Metastasis and extension	68 (33.2%)	239 (35.7%)	101 (22.4%)	408 (30.8%)
Metastasis no extension	53 (25.9%)	179 (26.8%)	184 (40.9%)	416 (31.4%)
Extension no metastasis	54 (26.3%)	119 (17.8%)	53 (11.8%)	226 (17.1%)
Neither metastasis nor extension	30 (14.6%)	132 (19.7%)	112 (24.9%)	274 (20.7%)
Total	205 (15.5%)	669 (50.5%)	450 (34.0%)	1324 (100.0%)

*Data from Dormanns

References

Bottiglieri, N. G., Palmer, E. D., Briggs, G. W., and Connant, C. N. Aortoesophageal fistula complicating carcinoma involving the esophagus. Report of 3 cases. Amer. J. Dig. Dis. 8:837–844, 1963.

Dietrich, R. A., Dockerty, M. B., Olsen, A. M., and Ellis, F. H., Jr. Clinicopathologic study of carcinoma involving the esophagogastric junction. Surg. Gynec. Obstet. 118:1223–1233, 1964.

Dormanns, E. Das Oesophaguscarcinom. Ergebnisse der unter Mitarbeit von 39 pathologischen Instituten Deutschlands durchgeführten Erhebung über das Oesophaguscarcinom (1925 – 33) Z. Krebsforsch 49:86 – 108, 1939.

Humphrey, C. R., and Cliffton, E. E. Carcinoma of the distal part of the esophagus and cardia of the stomach. Surg. Gynec. Obstet. 127:737–743, 1968.

Martini, N., Goodner, J. T., D'Angio, G. J., and Beattie, E. J. Tracheoesophageal fistula due to cancer. J. Thorac. Cardiovasc. Surg. 59:319–324, 1970.

Ochsner, A., and DeBakey, M. Surgical aspects of carcinoma of the esophagus. Review of the literature and report of four cases. J. Thorac. Cardiovasc. Surg. 10:401–445, 1940.

Valtonen, E. J., and Koivuniemi, A. Aortoesophageal fistula complicating carcinoma of the esophagus. Report of observations in two cases. J. Thorac. Cardiovasc. Surg. 53:448–452, 1967.

CLINICAL FINDINGS. Carcinoma of the esophagus occurs predominantly in elderly men (fig. 55). Among the 278 cases seen at the University of Maryland Hospital, the male to female ratio was 5 to 1. Seventy percent of the patients were in their sixth and seventh decades: the youngest was a man of 34, and the oldest was a man aged 90; both had squamous cell carcinoma in the lower esophagus. Dysphagia is the chief complaint in nearly all cases. The tumor is generally progressive although temporary remissions may be noted. Weight loss is a common finding, but cachexia is rare. Many patients complain of chest or epigastric pain often related to swallowing. Extensive invasion into neighboring organs produces additional symptoms, such as respiratory distress and cough due to involvement of the tracheobronchial tree and hoarseness due to involvement of the recurrent laryngeal nerve. Rarely, fatal massive bleeding occurs in ulcerative carcinoma, especially in cases accompanied by an aortoesophageal fistula. In one of our cases, this was the only manifestation. Wright and

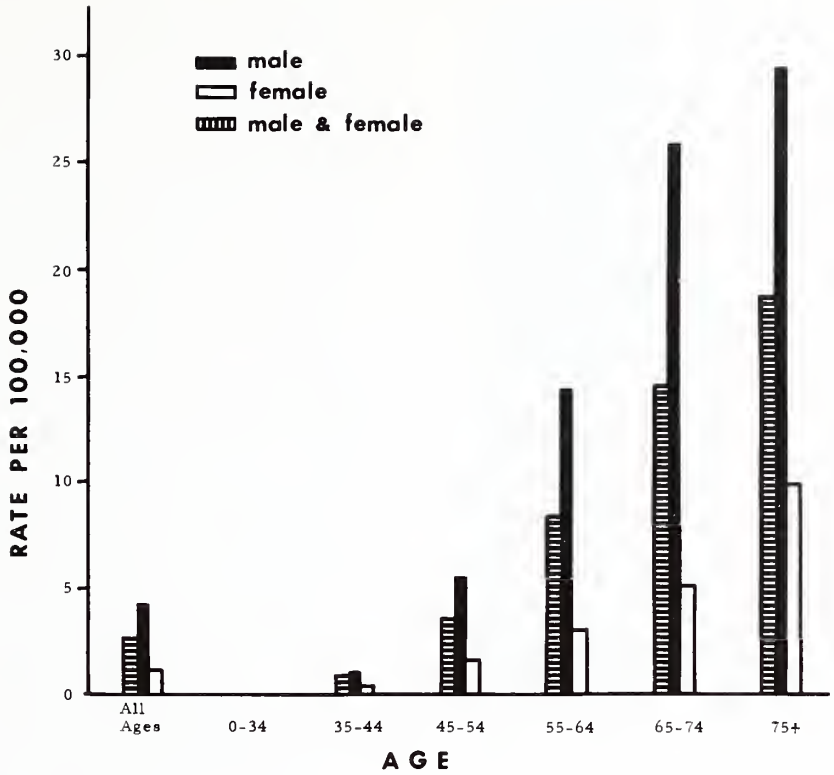

Fig 55

DEATH RATE DUE TO ESOPHAGEAL CARCINOMA ACCORDING TO SEX AND AGE

This graph depicts the death rate per 100,000 population due to esophageal cancer in the United States (1963), according to sex and age (World Health Organization 1963 data Causes of death Malignant neoplasms of oesophagus, of stomach, of intestine and of rectum WHO Epidem. Vital Statist Rep 18 261–288, 1965.)

Richardson reported four cases accompanied by malabsorption syndrome; three patients had megaloblastic and one had normocytic anemia. Other unusual manifestations include pseudohyperparathyroidism (Snedecor and Baker), hypokalemic alkalosis caused by ACTH-like substances secreted by the tumor (Lohrenz and Custer), and achalasia secondary to the destruction of esophageal ganglion cells by carcinoma which extended from gastric fundus (Kolodny et al.). Duration of symptoms in approximately two-thirds of the cases was less than six months and in one-third less than one month.

References

Carey, L. C., Darin, J. C., Worman, L. W., and Wagner, K. J. Upper gastrointestinal hemorrhage from carcinoma of esophagus A report of six cases Arch Surg 90 460–464, 1965.

Kolodny, M., Schrader, Z. R., Rubin, W., Hochman, R., and Sleisenger, M. H. Esophageal achalasia probably due to gastric carcinoma. Ann. Intern. Med 69 569–573, 1968

Lohrenz, F. N., and Custer, G. S ACTH producing metastases from carcinoma of the esophagus. Ann. Intern. Med 62 1017–1022, 1965

Martini, N., Goodner, J. T., D'Angio, G. J., and Beattie, E. J Tracheoesophageal fistula due to cancer J. Thorac. Cardiovasc Surg 59 319–324, 1970.

Miller, C Carcinoma of thoracic oesophagus and cardia. A review of 405 cases. Brit J Surg 49 507–522, 1962.

Mustard, R. A., and Ibberson, O Carcinoma of the esophagus A review of 381 cases admitted to Toronto General Hospital, 1937–1953 inclusive Ann. Surg 144 927–940, 1956

Snedecor, P. A., and Baker, H. W. Pseudohyperparathyroidism due to malignant tumors. Cancer 17:1492–1496, 1964.

Valtonen, E. J., and Koivuniemi, A. Aortoesophageal fistula complicating carcinoma of the esophagus. Report of observations in two cases. J. Thorac. Cardiovasc. Surg. 53:448–452, 1967.

Wright, J. T., and Richardson, P. C. Squamous carcinoma of the thoracic oesophagus in malabsorption syndrome. Brit. Med. J. 1:540–542, 1967.

DIAGNOSIS. Three principal procedures have been employed to achieve a correct diagnosis: roentgenography, esophagoscopy, and cytology. In view of the large size of the tumor, it is surprising that roentgenologic features do not always correlate with the gross pathologic findings. Miller pointed out that the tumor is usually found to be shorter than roentgenogram would indicate. Wu and associates attempted to correlate the roentgenogram with gross pathologic findings, but Bergman and associates noted many inconsistencies. Occasionally, a benign lesion may simulate a carcinoma or vice versa. The discrepancy between roentgenologic and gross findings can be explained in some cases by: the presence of food or air in the esophagus; the contractility of the organ in situ; and tumor alterations caused by treatment or changes taking place during the interval between roentgenologic examination and subsequent gross examination of the lesion.

The accuracy of cytologic examination varies from 55 to 94 percent correct diagnosis for a malignant lesion. An equally wide range of accuracy has been reported for esophagoscopy. Hookman reported positive diagnosis by endoscopic biopsy in 97 percent of cases and 72 percent by cytologic examination. He pointed out, however, that cytologic examination was particularly useful in diagnoses of patients manifesting very early lesions and the extremely ill patients. Furthermore, no false positive diagnosis for malignancy was found by cytologic examination in benign lesions, whereas other diagnostic procedures gave false reports of malignancy in about 5 percent of cases (MacDonald et al.). Prolla and associates noted that over 90 percent of squamous cell carcinomas and 70 to 80 percent of adenocarcinomas were correctly diagnosed by each of these methods. The joint application of all these methods should give the correct diagnosis in virtually every case. Radioactive phosphorus (P^{32}) is absorbed by tumor cells and has been used to detect esophageal cancer by means of a miniature Geiger tube. Nelson and Lanza reported accurate diagnoses in 96 percent of carcinoma cases by this method. However, this procedure also gave false positive results in 4 of 27 patients with esophagitis, as might be predicted, because phosphorus is picked up by any dividing nuclei and rapidly metabolizing cells.

References

Bergman, F., Borgstrom, K. E., and Gynning, I. Squamous epithelial carcinoma of the oesophagus; roentgenologic and histologic investigations. Acta Radiol. 3:234–240, 1965.

Block, G. E., and Lancaster, J. R. Adenocarcinoma of the cardioesophageal junction. Arch. Surg. 88:852–859, 1964.

Dietrich, R. A., Dockerty, M. B., Olsen, A. M., and Ellis, F. H., Jr. Clinicopathologic study of carcinoma involving the esophagogastric junction. Surg. Gynec. Obstet. 118: 1223–1233, 1964.

Hookman, P. A comparison of endoscopic biopsy and esophageal exfoliative cytology in establishing the diagnosis of carcinoma of the esophagus. Gastroint. Endosc. 12: 29–31, 1966.

MacDonald, W. C., Brandborg, L. L., Taniguchi, L., and Rubin, C. E. Esophageal exfoliative cytology. A neglected procedure. Ann. Intern. Med. 59:332–337, 1963.

Miller, C. Carcinoma of thoracic oesophagus and cardia. A review of 405 cases. Brit. J. Surg. 49:507–522, 1962.

Nelson, R. S., and Lanza, F. L. The clinical value of radioactive phosphorus (^{32}p) in the diagnosis of esophageal cancer. Amer. J. Dig. Dis. 14:538–544, 1969.

Prolla, J. C., Taebel, D. W., and Kirsner, J. B. Current status of exfoliative cytology in diagnoses of malignant neoplasms of the esophagus. Surg. Gynec. Obstet. 12: 743–752, 1965.

Wu, Y. K., Liu, Y., Hu, M. H., Hu, C. H., Liu, Y. C., Wu, H., Huang, K. C., Liu, T. H., and Chang, T. L. The classification of types of carcinoma of the esophagus; its diagnostic criteria and clinical significance. Chin. Med. J. 76: 213–228, 1958.

TREATMENT AND PROGNOSIS. Although distant metastases occur only in about one-third of cases and lymph node metastases in two-thirds of cases at autopsy, the rate of cure for carcinoma of the esophagus is disappointingly low, generally less than 5 percent. Even among surgically resectable cases, the reported 5-year survival rates were about 10 percent (Burge and Ochsner), with best results approaching 24 percent (Wu et al.). LeRoux summarized his surgical experience as follows: 39 percent of cases were inoperable; 43 percent of patients survived resection; and only 5 percent of patients lived more than five years. Extension of tumor into a neighboring organ is the major deterrent for curative surgical resection, thus resectability of the tumor is lowest for curative purposes in the upper esophagus and highest in the lower esophagus (Lu et al.). The size of the tumor, the cell type, grade of differentiation, and gross pattern are not significant factors in prognosis. But the general condition, and particularly the age of the patient, together with the extent of tumor invasion and the location of tumor in the esophagus are important factors in assessing surgical management (Magill and Simmons). Wu and associates noted a threefold better survival rate in patients without lymph node metastases than those with metastases and a twofold better survival rate in patients with carcinoma in the lower third of the esophagus compared to those with tumor in the upper segments.

Radiotherapy, particularly the supervoltage technic, has been used extensively in the hope of increasing the rate of cure. Occasionally the tumor is eliminated (fig. 56). In general, the results of this treatment have been just as disappointing as surgery (Gynning and Lindgren; Leborgne et al.; Marcial et al.). Pearson reported the best results with 20 percent of patients surviving five years or more. The general consensus is that radiotherapy provides better results for carcinomas of the upper esophagus, and

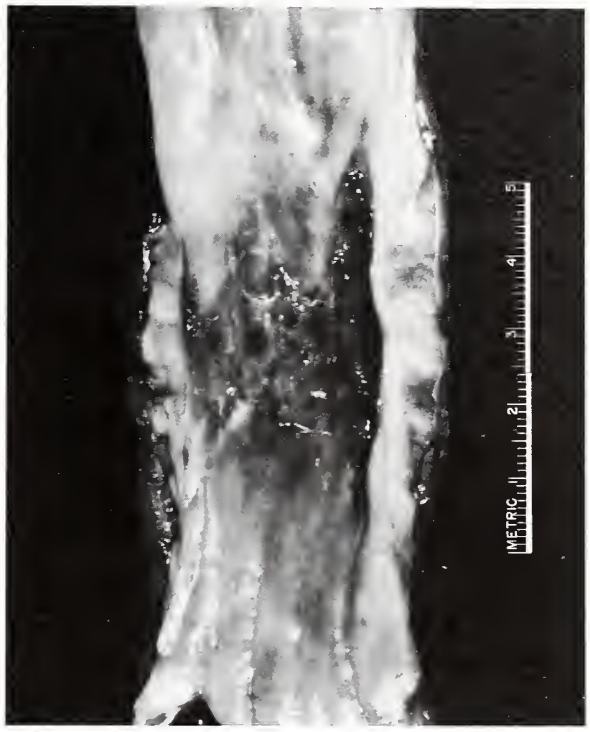

Fig 56

CARCINOMA TREATED WITH COBALT-60

This segment of esophagus was resected two months after cobalt-60 treatment for squamous cell carcinoma No residual tumor was found in this specimen The former cancer site was superficially ulcerated and hemorrhagic There was fibrosis in the muscular layer

surgical resection is more promising for carcinomas of the distal esophagus. General observation also indicates that radiotherapy gives immediate relief for some symptoms, prolongs the survival period, and renders some of the nonresectable tumors resectable. Combined radiotherapeutic and surgical treatment may be expected to provide the best results. In this regard, two important observations should be borne in mind: (1) Radiation-induced cell injury is at its peak two to three weeks after treatment and is overshadowed by the growth of undamaged cells one month later (Doctor and Sirsat); and (2) significant cell damage may be induced by concentrated radiation of 2000 to 2500 R total tumor dose, considered a low tolerable dose compared to the

6000 R usually applied, which often causes radiation damage in normal tissue and makes subsequent surgery difficult. With such a low dose of radiation followed by a staged surgical operation, Nakayama and associates achieved a 38 percent 5-year survival rate. Because of the low incidence of resectability for cure, palliative surgery may be the only recourse for alleviation of symptoms. A simple segmental resection with end-to-end anastomosis sometimes results in amazingly long survival of patients (Davidson).

References

Burge, J. P., and Ochsner, J. L. Management of esophageal tumors. Surg. Clin. N. Amer. 46:1457–1467, 1966.

Davidson, J. S. Resection of squamous-cell carcinoma of the oesophagus with end-to-end oesophageal anastomosis. Brit. J. Surg. 54:63–70, 1967.

Doctor, V. M., and Sirsat, M. V. A histopathologic study of pre-operative radiated carcinoma of the esophagus. Clin. Radiol. 18:422–427, 1967.

Goodner, J. T. Surgical and radiation treatment of cancer of the thoracic esophagus. Amer. J. Roentgen. 105:523–528, 1969.

Gynning, I., and Lindgren, M. Roentgen rotation therapy of oesophageal cancer. Acta Chir. Scand. Suppl. 356: 130–136, 1965.

Lawler, M. R., Jr., Gobbel, W. G., Jr., Killen, D. A., and Daniel, R. A., Jr. Carcinoma of the esophagus. J. Thorac. Cardiovasc. Surg. 58:609–613, 1969.

Leborgne, R., Leborgne, F., and Barlocci, L. Cancer of the oesophagus. Results of radiotherapy. Brit. J. Radiol. 36:806–811, 1963.

LeRoux, B. T. The influence of resection on the natural history of carcinoma of the hypopharynx, esophagus, and proximal stomach. Surg. Gynec. Obstet. 115:162–170, 1962.

Logan, A. The surgical treatment of carcinoma of the esophagus and cardia. J. Thorac. Cardiovasc. Surg. 46:150–161, 1963.

Lu, Y. K., Li, Y. M., Ch'en, T. M., and Keng, C. C. An analysis of mortality and postoperative complications of esophageal resection for cancer. Chin. Med. J. 83:39–44, 1964.

Magill, T. G., and Simmons, R. L. Resection of cardioesophageal carcinoma. Factors contributing to its mortality, palliation, and cure. Arch. Surg. 94:865–870, 1967.

Marcial, V. A., Tomé, J. M., Ubinas, J., Bosch, A., and Correa, J. N. The role of radiation therapy in esophageal cancer. Radiology 87:231–239, 1966.

Nakayama, K., Orihata, H., and Yamaguchi, K. Surgical treatment combined with preoperative concentrated irradiation for esophageal cancer. Cancer 20:778–788, 1967.

Pearson, J. G. The value of radiotherapy in the management of esophageal cancer. Amer. J. Roentgen. 105: 500–513, 1969.

Wu, Y. K., Huang, K. C., and Chang, W. Remote results of resection of squamous cell carcinoma of the esophagus. Acta Un. Int. Cancr. 19:1497–1498, 1963.

CARCINOID

Brodman and Pai reported a large carcinoid in a 66-year-old woman which involved the fundus of the stomach and the distal esophagus, with metastases to the gastric lymph nodes. The bulk of the tumor was located in the stomach. In this case, the carcinoid probably originated in the stomach and invaded the esophagus secondarily.

Brenner and associates reported a carcinoid in the distal esophagus just above the esophagogastric junction in a 56-year-old man who had symptoms of dysphagia and weight loss. The tumor was covered by intact esophageal epithelium. It infiltrated the muscularis and metastasized to the regional lymph nodes. Argentaffin stain was negative and the urine 5-hydroxyindole acetic acid was normal. Exploration of the remainder of the gastrointestinal tract failed to reveal other tumors.

References

Brenner, S., Heimlich, H., and Widman, M. Carcinoid of esophagus. New York J. Med. 69:1337–1339, 1969.

Brodman, H. R., and Pai, B. N. Malignant carcinoid of the stomach and distal esophagus. Review of the literature and a case report. Amer. J. Dig. Dis. 13:677–681, 1968.

MALIGNANT MELANOMA

There have been sporadic reports of malignant melanoma in the esophagus. Basque and associates found 29 cases in the literature since 1906 and described an ulcerative lesion in a 7-year-old boy. The primary nature of the tumor had been questioned even though junctional changes were usually present. There were two reasons: the absence of reports of a benign nevus, and the lack of melanoblasts in the esophageal epithelium. Benign nevus of the esophagus still has not been reported. The presence of melanoblasts in the esophagus has been documented, however. De la Pava and associates found melanoblasts in 4 of 100 carefully examined esophagi; they were in the upper esophagus in two cases and in the midesophagus in two. Cases reported by Raven and Dawson and by Piccone and associates noted their presence in the epithelium away from a melanoma as well as in the areas of junctional change adjacent to the tumor. Lacking junctional change, proof that the submucosal lesion is not metastatic would be desirable.

Malignant melanoma of the esophagus occurs primarily in older persons of either sex. It forms a polypoid tumor, usually in the lower esophagus, and may or may not be pigmented. The histologic characteristics and biologic behavior of the tumors resemble malignant melanomas found elsewhere.

References

Basque, G. J., Boline, J. E., and Holyoke, J. B. Malignant melanoma of the esophagus: first reported case in a child. Amer. J. Clin. Path. 53:609–611, 1970.

De la Pava, S., Nigogosyan, G., Pickren, J. W., and Cabrera, A. Melanosis of the esophagus. Cancer 16:48–50, 1963.

Piccone, V. A., Klopstock, R., LeVeen, H. H., and Sika, J. Primary malignant melanoma of the esophagus associated with melanosis of the entire esophagus. First case report. J. Thorac. Cardiovasc. Surg. 59:864–870, 1970.

Raven, R. W., and Dawson, I. Malignant melanoma of the oesophagus. Brit. J. Surg. 51:551–555, 1964.

Sakornpant, P., Barlow, D., and Bevan, C. M. Two cases of primary malignant melanoma of the oesophagus. Brit. J. Surg. 51:386–388, 1964.

CARCINOMA INVOLVING THE ESOPHAGUS SECONDARILY

Carcinoma in the upper portion of the stomach often invades the distal esophagus. Of 94 cases studied by Majima and associates, the esophagus was invaded in 65 percent, mostly by way of the submucosal lymphatic vessels. Carcinoma of the hypopharynx and larynx may extend into the upper esophagus in a similar fashion. Both Toreson, and Abrams and associates found metastatic tumors in the esophagus in 3 percent of cases of carcinoma at autopsy; most of the patients had primary tumors of the lung, stomach, larynx, or breast. Among our cases, there were eight secondary carcinomas in the esophagus, six from the lung, one from thyroid, and one from the pharynx. Contiguous spread of tumor into the esophagus may produce an ulcerative lesion resembling primary cancer of the esophagus, as exemplified by the extension of tumor from the gastric cardia. Fungating intraluminal masses generally do not develop. The lymphatic spread of tumor is usually a microscopic feature, or at most, it produces a small submucosal nodule. The presence of a large ulcerative mass probably indicates a primary esophageal carcinoma.

References

Abrams, H. L., Spiro, R., and Goldstein, N. Metastases in carcinoma. Analysis of 1000 autopsied cases. Cancer 3:74–85, 1950.

Atkins, J. P. Metastatic carcinoma to the esophagus. Endoscopic considerations with special reference to carcinoma of the breast. Ann. Otol. 75:356–367, 1966.

Majima, S., Yamaguchi, I., Yoshida, K., Karube, K., and Teshima, T. Esophageal extension of carcinoma of the stomach. Tohoku J. Exp. Med. 83:237–244, 1964.

Toreson, W. E. Secondary carcinoma of the esophagus as a cause of dysphagia. Arch. Path. 38:82–84, 1944.

TUMORS AND TUMOR-LIKE LESIONS OF MESODERMAL ORIGIN

TUMORS OF MUSCULAR TISSUE

LEIOMYOMA*

SYNONYMS AND RELATED TERMS: Angiomyofibroma; fibroleiomyoma; fibromyoma, myofibroma, myofibroma lymphangiectaticum, myoma, superficial leiomyoma, telangiectatic fibromyoma, vascular leiomyoma

Leiomyoma is the most common benign tumor in the esophagus (Table I). It occurs more commonly in men, with a male to female ratio of 2 to 1, and is most frequently found during the third to fifth decades. One tumor was reported in the distal esophagus of a 13-year-old girl (Botting et al.). The small tumors are asymptomatic and found incidentally at autopsy. The symptoms, chiefly dysphagia and substernal pain, are produced by a large tumor or an encircling tumor; the latter probably has its origin in the circular layer of the muscularis. The origin of the tumor also contributes to its relationship with the esophageal wall. Tumors arising in the muscularis mucosae are likely to be pedunculated and intraluminal, and those arising in the outer layer of the muscularis may be extramural and present as a mediastinal mass (Griff and Cooper).

Leiomyomas are located in the lower esophagus in 50 percent of cases, in the middle portion in 30 percent, and in the upper portion in 20 percent. Occasionally, a leiomyoma straddles the esophagogastric junction and is located partly in the stomach. It has also been found in the wall of a diverticulum. Of the surgically resected tumors, about one-half are larger than 5 cm. Most of the tumors form a well circumscribed mass covered by intact mucosa. Ulceration and bleeding are rare. Nodularity may be present peripherally (fig. 57), particularly in the elongated or annular tumors (fig. 58), suggesting multicentricity. Barrett

Fig 57

NODULAR LEIOMYOMA

This leiomyoma of the esophagus has a nodular external surface and whorled pale gray tissue on its cut surface (Courtesy of The Massachusetts General Hospital, Boston, Mass.)

described one multicentric tumor forming an intramural mass 9 cm. in length. Occasionally, multiple discrete nodules are present. The tumor tissue is rubbery, firm, and has a whorled appearance on the cut surface. Rarely, it is partially calcified. Histologically, the tumor is often partly covered by normal cells of the muscularis. Fibrous encapsulation is absent. The tumor cells are spindly or fusiform and closely resemble normal smooth muscle cells (fig. 59). They form interlacing bundles with varying amounts of fibrous tissue which tends to be more conspicuous in

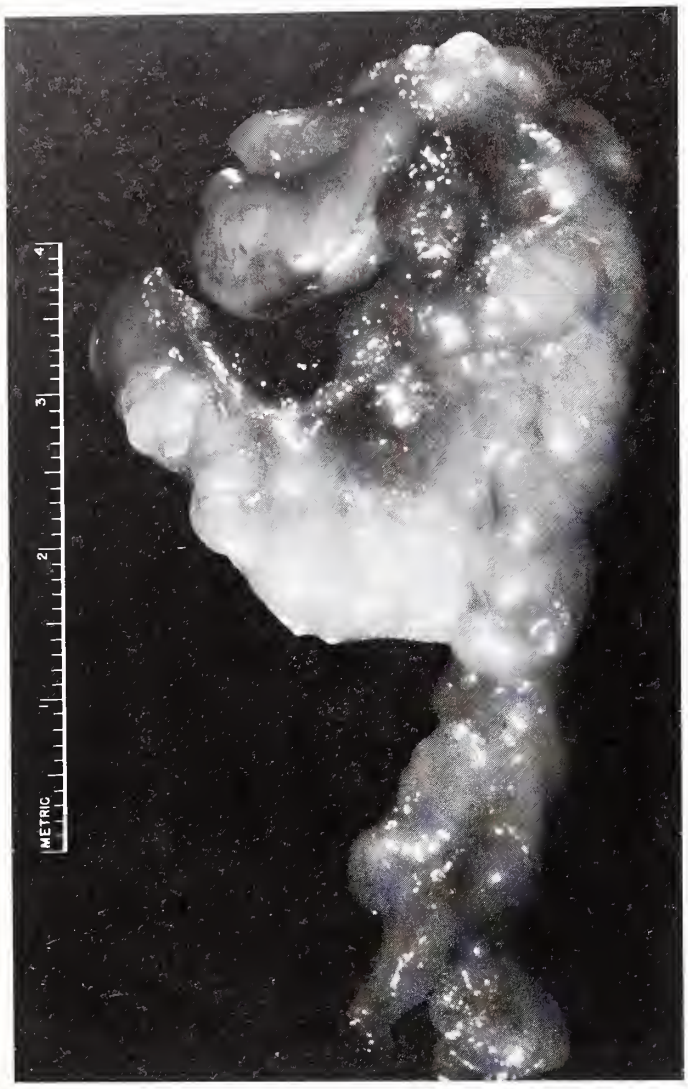

Fig 58

ANNULAR LEIOMYOMA

This leiomyoma partially encircled the esophagus The distinct nodularity and irregular outline suggest possible multicentricity (Courtesy of Beth Israel Hospital, Boston, Mass.)

the larger tumors. Palisading arrangement of nuclei is uncommon; when present, the tumor may be mistaken for a neurofibroma. Differentiation between the two lesions can be made by the pattern of reticulum fibers. Silver impregnation of leiomyoma reveals abundant reticulum fibers surrounding the individual cells, whereas the reticulum fibers in a neurofibroma have a haphazard arrangement.

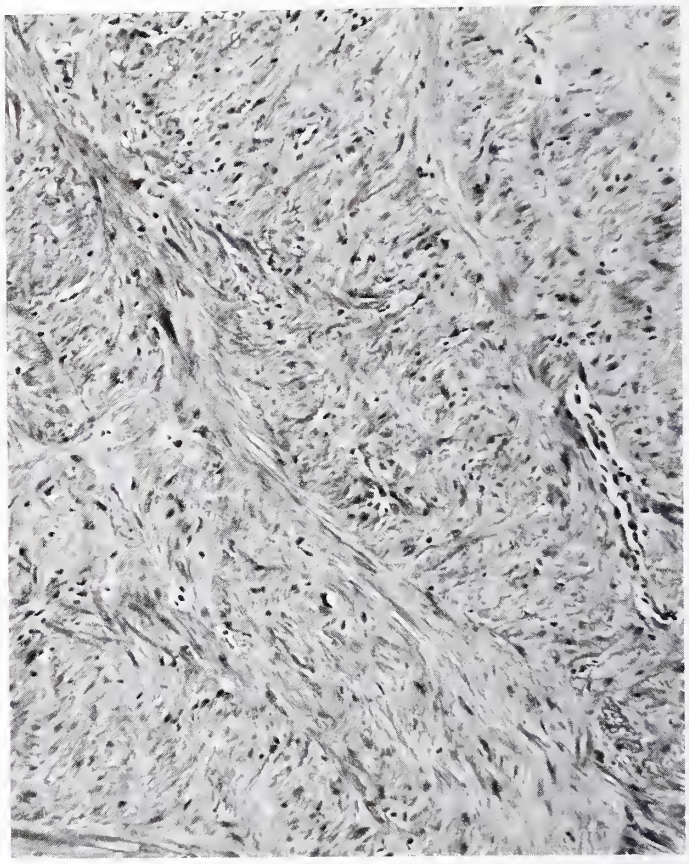

Fig 59

LEIOMYOMA

This leiomyoma reveals the classical pattern of interlacing bundles of smooth muscle cells Fibrous tissue is absent ×87

References

Barrett, N R Benign smooth muscle tumours of the oesophagus Thorax 19 185–194, 1964

Botting, A J, Soule, E H, and Brown, A L, Jr Smooth muscle tumors in children Cancer 18 711–720, 1965

Gowing, N F C The Pathology of Oesophageal Tumours, pp 91–135 In Tumours of the Oesophagus (Eds) Tanner, N C, and Smithers, D W Edinburgh & London, E & S Livingstone, Ltd, 1961

Griff, L C, and Cooper, J Leiomyoma of the esophagus presenting as a mediastinal mass Amer J Roentgen 101 472–481, 1967

Schmidt, H W, Clagett, O T, and Harrison, E G, Jr Benign tumors and cysts of the esophagus J Thorac Cardiovasc Surg 41 717–732, 1961

Sweet, R H, Soutter, L, and Valenzuela, C T Muscle wall tumors of the esophagus J Thorac Cardiovasc Surg 27 13–35, 1954

Totten, R S, Stout, A P, Humphreys, G H, II, and Moore, R L Benign tumors and cysts of the esophagus J Thorac Cardiovasc Surg 25 606–622, 1953

Watson, R R, O'Connor, T M, and Weisel, W Solid benign tumors of the esophagus Ann Thorac Surg 4 80–91, 1967

LEIOMYOSARCOMA*

SYNONYMS AND RELATED TERMS Malignant leiomyoma, metastasizing leiomyoma, myosarcoma

Sarcomas of the esophagus are rare. Among them, leiomyosarcoma is probably the most common. Among 1,456 cancers of the esophagus reviewed by Goodner and associates, there were eight sarcomas, seven leiomyosarcomas, and one fibrosarcoma. Rainer and Brus collected 30 cases from the literature and reported three additional cases. Twenty of these patients were men and 12 were women. The average age was in the sixth decade. The tumors were distributed rather evenly in different parts of the esophagus.

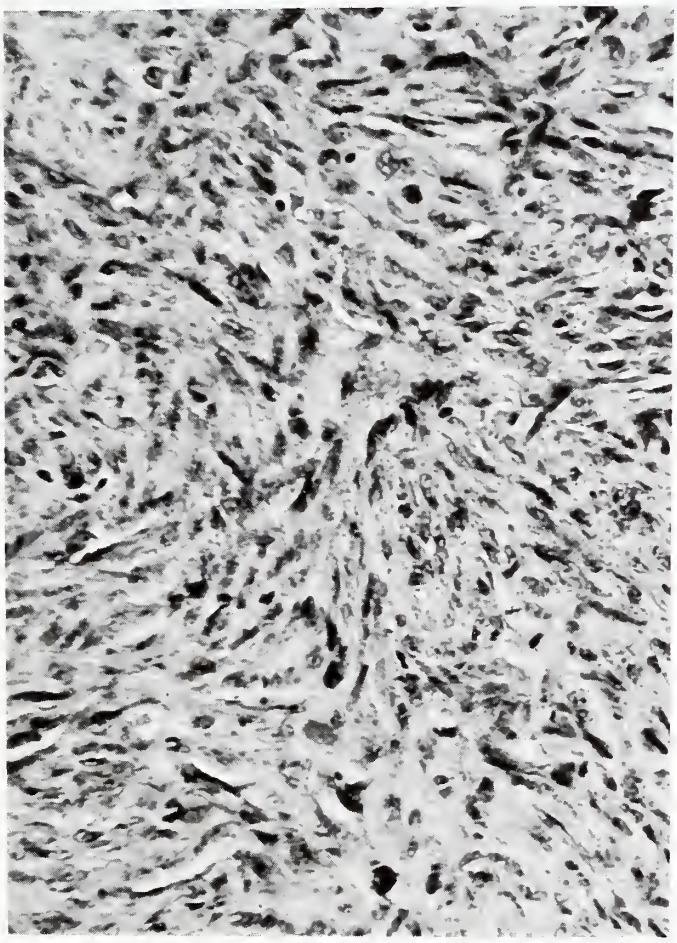

Fig 60

LEIOMYOSARCOMA

This leiomyosarcoma invaded the distal esophagus of a 64-year-old man. The tumor cells show moderate pleomorphism, with large hyperchromatic nuclei, scattered mitoses, and disorganized arrangement. × 268

The gross appearance of leiomyosarcoma is often that of a polypoid intraluminal mass with a broad base. Occasionally, there is a narrow stalk. The covering mucosa may be intact or ulcerated. Rarely, foci of superficial squamous cell carcinoma have been found in the tumor (Rainer and Brus; Camishion et al.). Some of the tumors infiltrate extensively, resembling invasive carcinoma. Infiltration into neighboring organs may be present but is not common. Microscopically, the tumor is composed predominantly of elongated cells forming interlacing fascicles (fig. 60). Pleomorphism may be marked and bizarre, and giant cell forms are frequent. Mitoses are always present. The tumor usually infiltrates into and occasionally beyond the adjacent esophageal muscularis. Metastasis is rare, even at autopsy. Prognosis is good, especially for polypoid tumors, even after limited excision (Borrie; Johnston et al.). Leiomyosarcomas are sensitive to radiation and remarkable regressions have been noted following radiotherapy (Athanasoulis and Aral; Wolfel).

RHABDOMYOSARCOMA*

SYNONYMS AND RELATED TERMS Malignant rhabdomyoma, myosarcoma, rhabdomyoblastoma

Rhabdomyosarcoma is extremely rare in the esophagus. Only five cases were reported before 1956 (DeMuth). Most of these tumors were polypoid. The diagnosis had been based on the presence of pleomorphic cells with giant cell forms, but without cross-striations. This tumor may well be a poorly differentiated leiomyosarcoma, particularly if it occurs in an area where striated muscle cells are normally absent. Rhabdomyosarcoma has also been reported as a component of carcinosarcoma (Ende et al.; Stout and Lattes).

References

Athanasoulis, C. A., and Aral, I. M. Leiomyosarcoma of the esophagus. Gastroenterology 54:271–274, 1968.

Borrie, J. Sarcoma of esophagus: surgical treatment. J. Thorac. Cardiovasc. Surg. 37:413–426, 1959.

Camishion, R. C., Gibbon, J. H., Jr., and Templeton, J. Y., III. Leiomyosarcoma of the esophagus. Review of the literature and report of two cases. Ann. Surg. 153:951–956, 1961.

DeMuth, W. E., Jr. Rhabdomyosarcoma of the esophagus. J. Thorac. Cardiovasc. Surg. 32:115–118, 1956.

Ende, N., Pizzolato, P., Raider, L., and Ziskind, J. An unusual case of carcinosarcoma of the esophagus. Amer. J. Roentgen. 65:227–231, 1951.

Goodner, J. T., Miller, T. R., and Watson, W. L. Sarcoma of the esophagus. Amer. J. Roentgen. 89:132–139, 1963.

Johnston, J. B., Clagett, O. T., and McDonald, J. R. Smooth-muscle tumours of the oesophagus. Thorax 8:251–265, 1953.

Rainer, W. G., and Brus, R. Leiomyosarcoma of the esophagus, review of the literature and report of 3 cases. Surgery 58:343–350, 1965.

Stout, A. P., and Lattes, R. Tumors of the Esophagus. Fascicle 20, Atlas of Tumor Pathology. Washington: Armed Forces Institute of Pathology, 1957.

Wolfel, D. A. Leiomyosarcoma of the esophagus. Amer. J. Roentgen. 89:127–131, 1963.

TUMORS OF FIBROUS AND ADIPOSE TISSUE

FIBROUS POLYP

SYNONYMS AND RELATED TERMS: Fibrovascular polyp, fibrolipoma; myxofibroma; pedunculated lipoma.

Polyps are the second most common benign tumor in the esophagus and the most common intraluminal tumor (Table I). Totten and associates found them chiefly in the upper esophagus, particularly at the level of cricoid cartilage. Plachta, on the other hand, found the lower esophagus to be the favored site (Table II). Most of the patients were adult men. Ulceration and bleeding may occur, but generally are mild. Symptoms are usually due to obstruction of the esophagus or larynx. There have been reports of periodic and dramatic regurgitation of the large pedunculated mass, and in such cases asphyxiation due to obstruction of the larynx by the mass is usually the cause of death.

The size of the polyps varies from less than 1 cm. in diameter up to 20 cm. in length, most of them averaging less than 5 cm. in greatest dimension. The larger polyps may be lobulated and some are multiple (pl. I–C). They are covered by a smooth mucosa which may be focally ulcerated. Histologically, the polyp is composed primarily of mature fibrous tissue with varying degrees of vascularity and varying amounts of adipose tissue. When the latter is prominent, the polyp has been called fibrolipoma or pedunculated lipoma. Inflammation is usually mild, unless ulcerated. Leand and associates reported a 5 cm. polypoid mass in the lower esophagus of a 36-year-old man. The mass contained abundant eosinophilic leukocytes and was considered to be an eosinophilic granuloma. The epithelial covering of the fibrous polyp is usually squamous, but Dieter and associates reported a polyp in the upper esophagus of a 6-year-old girl which contained gastric and respiratory epithelium as well as cartilage. The squamous epithelium covering the polyp is usually normal, but Stout and Lattes described one polyp containing a focus of invasive squamous cell carcinoma (fig. 61) which also involved the adjacent mucosa. Marcial-Rojas and Suau reported a focus of invasive carcinoma in an 11 by 3.5 cm. pedunculated lipoma. Both tumors were located in the upper esophagus.

FIBROMA* AND LIPOMA*

SYNONYMS AND RELATED TERMS: Fibrolipoma; fibromatosis; pedunculated lipoma.

A number of fibromas and lipomas have been reported (Tables I and II). Some, especially the pedunculated ones, are probably fibrous polyps. Leiomyomas may also be mistaken for fibromas. Sessile submucosal nodules that are composed almost entirely of fibrous or adipose tissue may be considered true fibromas or lipomas. Such tumors are rare. The esophagus may also be involved in generalized fibromatosis (Stout and Lattes).

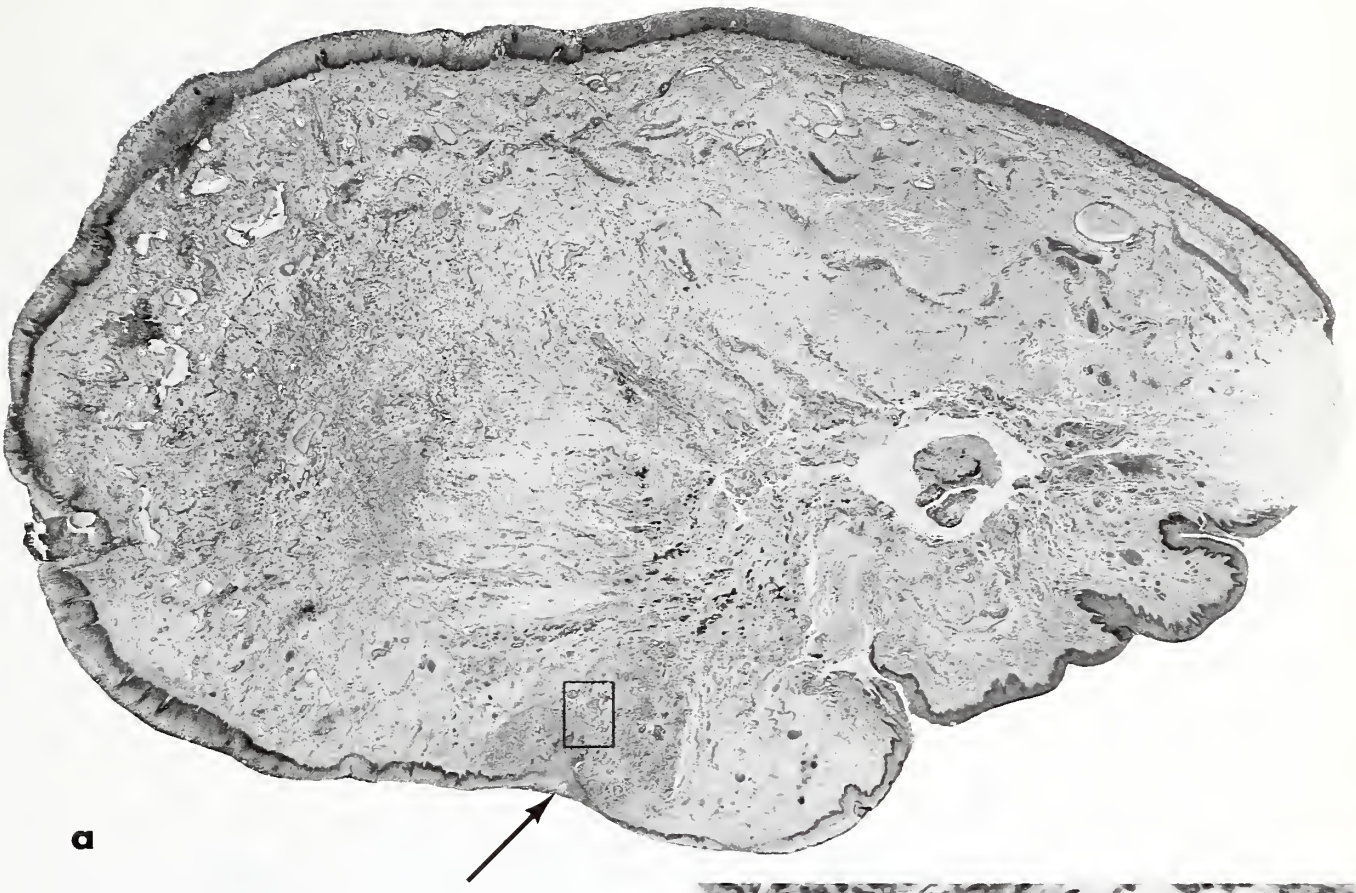

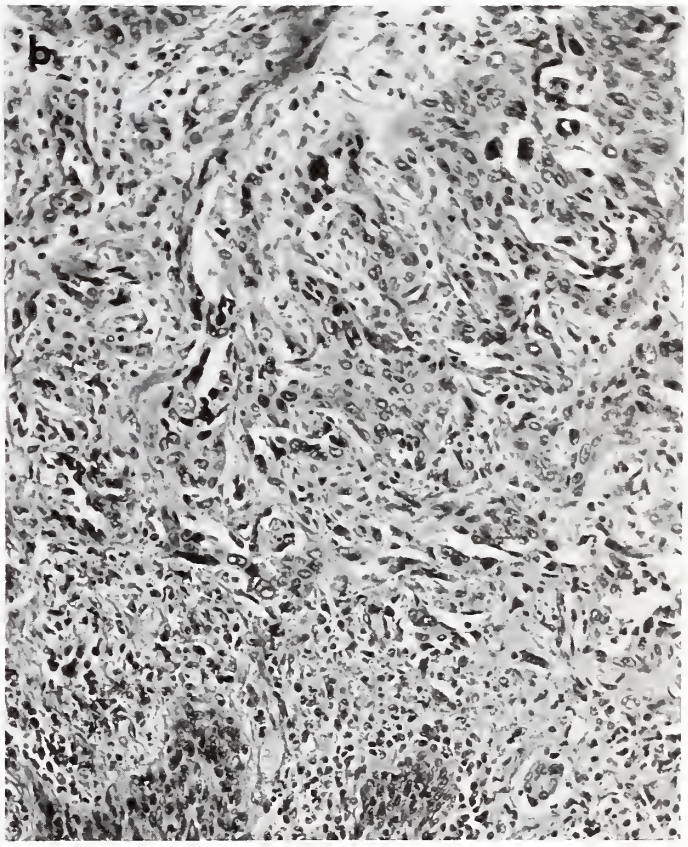

Fig 61

FIBROUS POLYP WITH SQUAMOUS CELL CARCINOMA

This section (a) is from a fibrous polyp removed from the upper esophagus of a 70-year-old man. The arrow points to a small focus of invasive squamous cell carcinoma which was also present in the adjacent hypopharyngeal wall. The details of invasive carcinoma are shown in (b). (Figs 13 and 14 from Stout, A. P., and Lattes, R. Tumors of the Esophagus. Fascicle 20, Atlas of Tumor Pathology. Washington: Armed Forces Institute of Pathology, 1957.)

PLATE I

SQUAMOUS CELL CARCINOMA OF ESOPHAGUS

A. This ulcerative squamous cell carcinoma in the distal esophagus infiltrated through the muscularis into the peri-esophageal connective tissue. Submucosal tumor nodules covered by intact epithelium are evident at the border of the ulcer. (Courtesy of Beth Israel Hospital, Boston, Mass.)

ADENOCARCINOMA AT ESOPHAGOGASTRIC JUNCTION

B. This infiltrative, stenosed adenocarcinoma at the esophagogastric junction was found in a 68-year-old man. The mucosa is granular, but lacks gross ulceration.(Courtesy of Beth Israel Hospital, Boston, Mass.)

FIBROUS POLYPS OF ESOPHAGUS

C. These multiple fibrous polyps were removed from the esophagus of a 51-year-old man. (Pl. I-C from Stout, A. P., and Lattes, R. Tumors of the Esophagus. Fascicle 20, Atlas of Tumor Pathology. Washington: Armed Forces Institute of Pathology, 1957, courtesy of Dr. A. F. McBride, Jr., Paterson, N. J.)

CARCINOSARCOMA OF ESOPHAGUS

(Plate I-D and Figure 64 from same case)

D. This is a polypoid carcinosarcoma of the esophagus from a 46-year-old woman. (Pl. I-D from Stout, A. P., and Lattes, R. Tumors of the Esophagus. Fascicle 20, Atlas of Tumor Pathology. Washington: Armed Forces Institute of Pathology, 1957.)

A

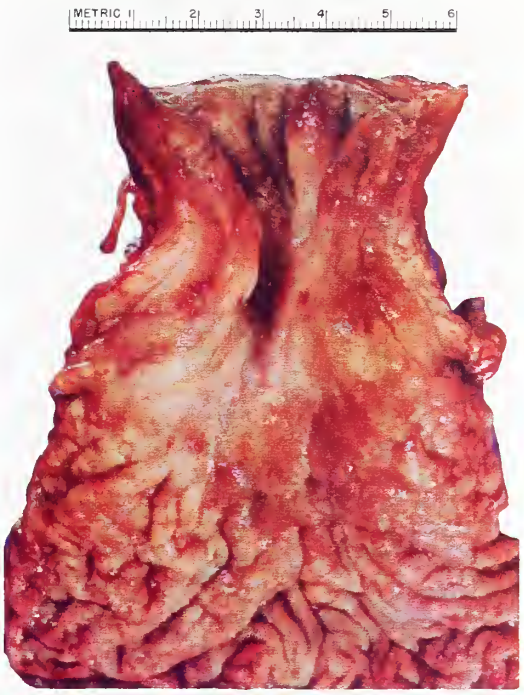

B

C

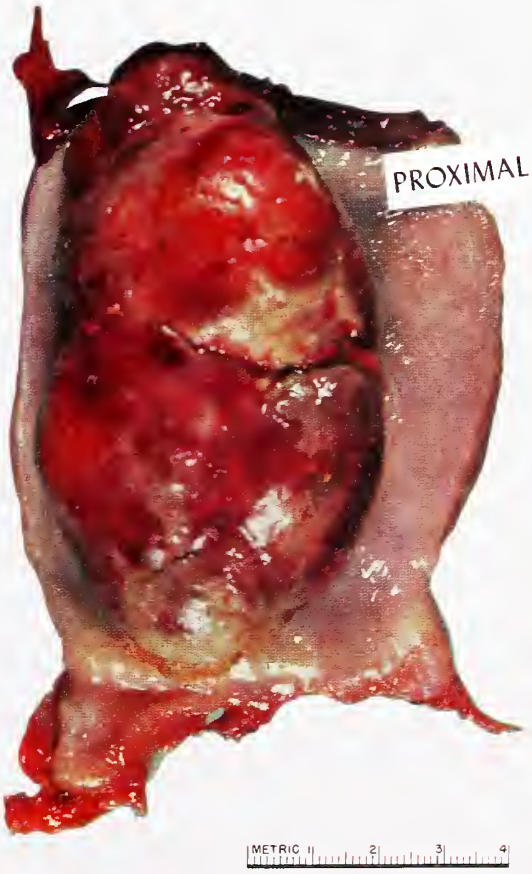

D

PLATE I

FIBROSARCOMA*

SYNONYMS AND RELATED TERMS Fibromyxosarcoma, fibrosarcoma myxomatodes; neurogenic sarcoma

Thorek and Neiman listed fibrosarcoma as the most common sarcoma among the recorded cases up to 1950. Only occasional cases have been reported in recent years. It is likely that many of those reported earlier were actually leiomyosarcomas. The case reported by Clark was a sessile mass in the upper esophagus of a 43-year-old man. The diagnosis was based on the absence of myofibrils in sections of tumor stained by phosphotungstic acid hematoxylin. This negative finding does not confirm the fibrous tissue origin of the tumor, however. Goodner and associates reported one fibrosarcoma among 1,456 esophageal malignancies. The tumor was located in the cervical esophagus of a 54-year-old woman who 30 years previously had received radiation for an enlarged thyroid. The patient was well 13 years after resection of the tumor. A similar case was reported by Goolden of a 50-year-old woman who received radiation treatment for thyrotoxicosis 29 years previously. Long survival was also noted in Gowing's patient and among seven surgically treated cases collected from the literature by Borrie.

References

Allen, M. S., Jr., and Talbot, W. H. Sudden death due to regurgitation of a pedunculated esophageal lipoma. J. Thorac. Cardiovasc. Surg. 54:756–758, 1967.

Borrie, J. Sarcoma of esophagus: surgical treatment. J. Thorac. Cardiovasc. Surg. 37:413–426, 1959.

Clark, D. E. Sarcoma of the esophagus. Report of successful resection of a fibrosarcoma. Arch. Surg. 59:348–354, 1949.

Dieter, R. A., Jr., Riker, W. L., and Holinger, P. Pedunculated esophageal hamartoma in a child. A case report. J. Thorac. Cardiovasc. Surg. 59:851–854, 1970.

Goodner, J. T., Miller, T. R., and Watson, W. L. Sarcoma of the esophagus. Amer. J. Roentgen. 89:132–139, 1963.

Goolden, A. W. G. Radiation cancer of the pharynx. Brit. Med. J. 2:1110–1112, 1951.

Gowing, N. F. C. The Pathology of Oesophageal Tumours, pp. 91–135. In: Tumours of the Oesophagus (Eds.) Tanner, N. C., and Smithers, D. W. Edinburgh & London: E. & S. Livingstone, Ltd., 1961.

Jang, G. C., Clouse, M. E., and Fleischner, F. G. Fibrovascular polyp—a benign intraluminal tumor of the esophagus. Radiology 92:1196–1200, 1969.

Leand, P. M., Murray, G. F., Zuidema, G. D., and Shelley, W. M. Obstructing esophageal polyp with eosinophilic infiltration. So-called eosinophilic granuloma. Amer. J. Surg. 116:93–96, 1968.

Marcial-Rojas, R. A., and Suau, P. Epidermoid carcinoma in mucosa overlying a pedunculated lipoma of the esophagus. J. Thorac. Cardiovasc. Surg. 37:427–434, 1959.

Nora, P. F. Lipoma of the esophagus. Amer. J. Surg. 108:353–356, 1964.

Plachta, A. Benign tumors of the esophagus. Review of literature and report of 99 cases. Amer. J. Gastroent. 38:639–652, 1962.

Stout, A. P., and Lattes, R. Tumors of the Esophagus. Fascicle 20, Atlas of Tumor Pathology. Washington: Armed Forces Institute of Pathology, 1957.

Thorek, P., and Neiman, B. H. Rhabdomyosarcoma of the esophagus. J. Thorac. Cardiovasc. Surg. 20:77–89, 1950.

Totten, R. S., Stout, A. P., Humphreys, G. H., II, and Moore, R. L. Benign tumors and cysts of the esophagus. J. Thorac. Cardiovasc. Surg. 25:606–622, 1953.

TUMORS OF VASCULAR TISSUE

HEMANGIOMA

SYNONYMS AND RELATED TERMS. **Capillary hemangioma; cavernous (venous) hemangioma;** cavernous hemangioma, capillary hemangioma, granuloma type, venous hemangioma

Hemangioma has been found infrequently in the esophagus (Table I). It is usually a polypoid bluish nodule in the middle portion of the esophagus. Many are small, asymptomatic, and found incidentally at autopsy (Gentry et al.). Some hemangiomas are lobulated and occasionally multiple (Boyd and Hill). Bleeding, sometimes massive, is the main clinical manifestation. Rarely, the tumor is large enough to cause obstruction (Vinson et al.).

LYMPHANGIOMA*

SYNONYMS AND RELATED TERMS Cavernous lymphangioma, cystic lymphangioma, simple lymphangioma

Watson-Williams reported a case of lymphangioma with several round masses in the distal esophagus. Since they were red, it might well have been hemangioma rather than lymphangioma.

GLOMUS TUMOR*

SYNONYMS AND RELATED TERMS Tumor of neuromyoarterial glomus; glomangioma, angioneuroma, angioneuromyoma; neuromyoarterial glomus; Popoff tumor

Recently, a glomus tumor was reported in the distal esophagus of a 62-year-old woman. The tumor was resected and the patient was well two years after surgery.

KAPOSI'S DISEASE

SYNONYMS AND RELATED TERMS **Hemorrhagic sarcoma (Kaposi)**; angiosarcoma multiplex, granuloma multiplex hemorrhagicum, "Kaposi's disease", Kaposi's syndrome, multiple hemorrhagic sarcomatosis, multiple idiopathic hemorrhagic sarcoma, sarcoma nodulosum cavernosum

Kaposi's disease may involve the esophagus as a part of systemic involvement. The case reported by Siegel and associates was interesting in that the disease manifested itself in a patient following renal homograft and immunosuppressive treatment.

References

Boyd, D P., and Hill, L D., III Benign tumors and cysts of the esophagus Amer J Surg 93 252–258, 1957

Gentry, R W., Dockerty, M B., and Clagett, O T Vascular malformations and vascular tumors of the gastrointestinal tract Internat Abstr Surg 88 281–323, 1949

Grimes, O F Cavernous hemangioma of the esophagus Dis Chest 48 380–384, 1965

Rueff, F., and Grabiger, A Glomustumor des Ösophagus Bruns Beitr Klin Chir 215 106–110, 1967

Siegel, J H., Janis, R., Alper, J C., Schutte, H., Robbins, L., and Blaufox, M D Disseminated visceral Kaposi's sarcoma Appearance after human renal homograft operation J A M A 207 1493–1496, 1969

Vinson, P P., Moore, A B., and Bowing, H H. Hemangioma of the esophagus Report of a case Amer J Med. Sci 172 416–418, 1926

Watson-Williams, E Specimen lymphangioma of the oesophagus Proc Roy Soc. Med 27 1288, 1934

TUMORS OF NERVOUS TISSUE

NEUROFIBROMA*

SYNONYMS AND RELATED TERMS Neurinoma, solitary neurofibroma (solitary nerve sheath tumor).

Neurofibroma has occasionally been reported (Tables I and II). The typical histologic features seen in neurilemoma are generally absent. Instead, the tumor is composed of spindle cells indistinguishable from smooth muscle cells. Like other benign mesodermal tumors in the esophagus, many if not all of these tumors are actually leiomyomas.

GRANULAR CELL TUMOR

SYNONYMS AND RELATED TERMS **Granular cell myoblastoma**; Abrikossoff's tumor, embryonal rhabdomyoblastoma, "granular cell neurofibroma", granular cell schwannoma, granular myoblastoma, myoblastic myoma, myoblastoma, "pleomorphic-cell sarcoma".

The cell origin of granular cell tumor remains controversial. Although the term "myoblastoma" is still widely used, evidence, including ultrastructural and cytochemical features, strongly indicates a Schwann cell origin (Sobel et al.). It occurs in the esophagus rarely. Flege and Edmonds reviewed nine reported cases in the literature and added one of their own. Of the 10 adult patients, all under 50 years of age, eight were women. The upper esophagus was the favored site. Most of the lesions were small and round. Two were annular and obstructive. The tumor reported by Obiditsch-Mayer and Salzer-Kuntschik invaded the trachea and metastasized to cervical lymph nodes. There was one case at the University of Maryland Hospital (figs. 62, 63). It was a 1.5 cm. firm, sessile nodule in the mid-esophagus of a 41-year-old woman. The tumor was mainly submucosal, but infiltrated the muscularis. As in other cases, the covering squamous epithelium showed pseudoepitheliomatous hyperplasia (fig. 62).

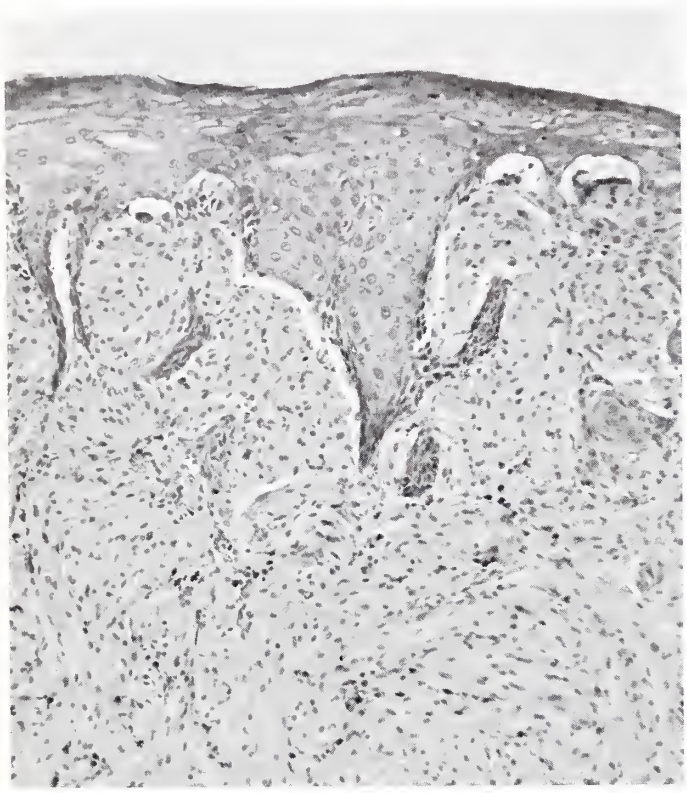

Fig. 62

GRANULAR CELL TUMOR

(Figures 62 and 63 from same case)

This granular cell tumor of the esophagus was excised from a 41-year-old woman who complained of postprandial chest pain and occasional regurgitation of food. The tumor was a 1.5 cm. sessile nodule and was located principally in the submucosa. The covering squamous epithelium shows pseudoepitheliomatous hyperplasia. The tumor cells are pale staining with small nuclei and abundant cytoplasm. ×110.

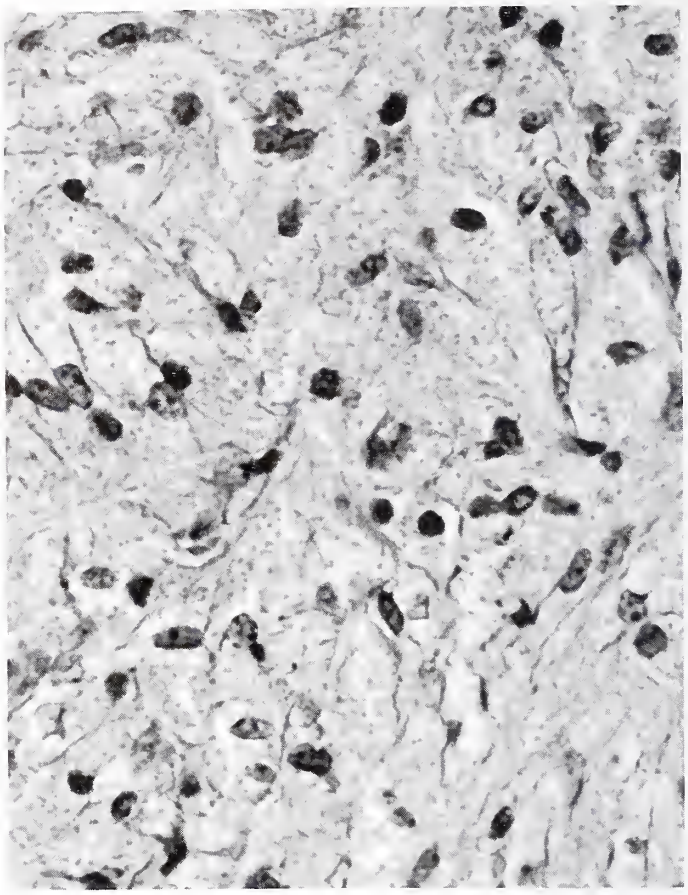

Fig. 63

GRANULAR CELL TUMOR

(Figures 62 and 63 from same case)

This is a higher magnification of the granular cell tumor shown in figure 62. The tumor cells have relatively small nuclei and abundant cytoplasm which is characteristically granular. ×550

References

Flege, J. B., Jr., and Edmonds, T. T. Granular cell myoblastoma of the esophagus. A case report. J. Thorac. Cardiovasc. Surg. 58: 217–220, 1969.

Obiditsch-Mayer, I., and Salzer-Kuntschik, M. Malignes, "gekörntzelliges Neurom," sogenanntes "Myoblastemyom," des Oesophagus. Beitr. Path. Anat. 125: 357–373, 1961.

Sobel, H. J., Marquet, E., Avrin, E., and Schwarz, R. Granular cell myoblastoma. An electron microscopic and cytochemical study illustrating the genesis of granules and aging of myoblastoma cells. Amer. J. Path. 65: 59–78, 1971.

Sturdy, D. E. Neurofibroma (syn. neurilemmoma) of the oesophagus. Brit. J. Surg. 54: 315–316, 1967.

TUMORS OF OSTEOCARTILAGINOUS TISSUE

Mahour and Harrison reported an **osteochondroma*** in the upper esophagus of a 66-year-old woman. The tumor was a lobulated and pedunculated mass which measured 5.5 by 3.5 by 2.3 cm. on surgical resection. These authors referred to Meyer, who in 1887 reported one case with cartilaginous tissue in the esophagus, and they collected 12 others from the literature; all were small nodules found at autopsy. Stout and Lattes illustrated a similar lesion found incidentally at autopsy. The only other lesion diagnosed and resected surgically was reported by Reeves. The tumor was 1 cm. in diameter and was removed through an esophagoscope.

References

Mahour, G. H., and Harrison, E. G., Jr. Osteochondroma (tracheobronchial choristoma) of the esophagus. Report of a case. Cancer 20: 1489–1493, 1967.

Reeves, E. Osteochondroma of the esophagus removed perorally with the aid of a speculum. With review of the benign tumors of the esophagus. Arch. Otolaryng. 29: 151–158, 1939.

Stout, A. P., and Lattes, R. Tumors of the Esophagus. Fascicle 20, Atlas of Tumor Pathology. Washington: Armed Forces Institute of Pathology, 1957.

LYMPHOMA

Mediastinal involvement by lymphoma is common, but compression of the esophagus is infrequent, and infiltration into the esophageal wall is rare. Most such patients have Hodgkin's disease. Among 174 clinical cases of Hodgkin's disease, Jackson and Parker recorded one case of a 59-year-old man who developed difficulty in swallowing because of extensive irregular infiltration of the midesophagus. Ennuyer and associates found five other reports in the literature with prominent esophageal involvement during the course of disease, and presented one case of their own. They also found four reports in which dysphagia due to esophageal involvement was the initial manifestation. Their patient was a 25-year-old woman who had a constricting lesion in the esophagus and involvement of the regional lymph nodes. Piaget and associates described one case that was complicated by esophagotracheobronchial fistula. Less commonly, lymphoma of histiocytic (reticulum cell) type may have a similar presentation. These esophageal lesions are polypoid or nodular, often multiple. Circumferential involvement with stenosis may also occur, mimicking a carcinoma. Diagnosis is readily established by biopsy of cervical lymph nodes which are usually involved. Radiotherapy generally results in marked regression of the lesion and prompt alleviation of dysphagia.

References

Ennuyer, A., Bataini, P., and Helary, J. Hodgkin's disease of the upper respiratory and digestive tracts. Possible portal of entry of the causal agent of malignant lymphogranuloma. Ann. Radiol. 4: 145–165, 1961.

Finby, N., and Begg, C. F. Correlation conferences in radiology and pathology. Reticulum cell lymphoma with dysphagia as present symptom. New York J. Med. 65: 3060–3063, 1965.

Jackson, H., Jr., and Parker, F., Jr. Hodgkin's Disease and Allied Disorders. New York: Oxford University Press, 1947.

Piaget, Mazaré, and Kuentz. Maladie de Hodgkin et perforation oesophago trachéo-bronchique. Ann. Otolaryng. 81: 183–185, 1964.

Williams, E. R. A radiological study of intrathoracic lymphogranuloma and lymphosarcoma. Brit. J. Radiol. 8: 265–279, 1935.

CONCOMITANT MESODERMAL TUMOR AND CARCINOMA

Two cases of squamous cell carcinoma seen at the University of Maryland Hospital had separate, incidental small mesodermal lesions in the esophagus, one a fibrous polyp and the other a leiomyoma. There have been other recorded cases of carcinoma with separate tumors such as leiomyoma (Callanan; Lu et al.; Puestow et al.) or leiomyosarcoma (Ovens and Russell; Rella et al.) in the same esophagus. Such concurrent tumors may be considered chance findings. More interesting are those carcinomas that have apparently developed in the mucosa covering a mesodermal

tumor. Marcial-Rojas and Suau reported a case of invasive squamous cell carcinoma in a large pedunculated lipoma and mentioned another patient with carcinoma near the base of a lipoma. Stout and Lattes described a small focus of squamous cell carcinoma in a fibrous polyp (fig. 61). Superficial squamous cell carcinomas were also present in polypoid leiomyomas reported by Camishion and associates and by Rainer and Brus. Carcinoma is known to occur more frequently in an esophagus that has suffered chronic tissue damage, such as in association with benign stricture, achalasia, and hiatus hernia. It is possible that malignant transformation of the epithelium covering a polypoid tumor has a similar etiologic basis.

References

Callanan, J. G. Simultaneous occurrence of simple and malignant tumors in the esophagus. J. Thorac. Cardiovasc. Surg. 28:4–10, 1954.

Camishion, R. C., Gibbon, J. H., Jr., and Templeton, J. Y., III. Leiomyosarcoma of the esophagus. Review of the literature and report of two cases. Ann. Surg. 153:951–956, 1961.

Lu, Y. K., Li, Y. M., and Keng, C. C. The coexistence of benign and malignant tumors of the esophagus. Chin. Med. J. 82:805–808, 1963.

Marcial-Rojas, R. A., and Suau, P. Epidermoid carcinoma in mucosa overlying a pedunculated lipoma of the esophagus. J. Thorac. Cardiovasc. Surg. 37:427–434, 1959.

Ovens, J. M., and Russell, W. O. Concurrent leiomyosarcoma and squamous carcinoma of the esophagus. Arch. Path. 51:560–563, 1951.

Puestow, C. B., Gillesby, W. J., and Powers, J. A. Benign tumors of the esophagus. Amer. Surg. 21:425–433, 1955.

Rainer, W. G., and Brus, R. Leiomyosarcoma of the esophagus, review of the literature and report of 3 cases. Surgery 58:343–350, 1965.

Rella, A. J., Farrell, J. T., and Comer, J. V. Concurrent leiomyosarcoma and squamous cell carcinoma of the esophagus. New York J. Med. 65:1254–1256, 1965.

Stout, A. P., and Lattes, R. Tumors of the Esophagus. Fascicle 20, Atlas of Tumor Pathology. Washington: Armed Forces Institute of Pathology, 1957.

CARCINOSARCOMA AND PSEUDOSARCOMA

SYNONYMS AND RELATED TERMS: Adenosarcoma; carcinoma sarcomatodes; mixed tumor; sarcocarcinoma.

Carcinosarcoma, a malignant tumor composed of both epithelial and mesenchymal elements, occurs infrequently in the esophagus. In 1949, Stout and associates reviewed 18 cases including one of their own (pl. I–D; fig. 64). In 1963, Moore and associates added 11 more cases. Twenty of these 29 tumors were polypoid with a broad base, up to 15 cm. in greatest dimension, and nine were infiltrative and ulcerated. Talbert and Cantrell reported four polypoid tumors and noted a low incidence of metastases, but a high mortality rate. The longest survivor was a patient reported by Stener and associates who remained asymptomatic for over six years following surgical resection. Forty-one cases of carcinosarcoma were found in the literature; most occurred in the lower portion of the esophagus, predominantly in men over 50 years of age. Histologically, the epithelial component is usually of the squamous cell type (fig. 65), but occasionally it is glandular or anaplastic. The sarcomatous elements are spindle cells with frequent bizarre giant cell forms (fig. 65). Cartilaginous, osteoid, or myomatous tissue is also occasionally present (fig. 66). Either or both carcinomatous and sarcomatous elements may be present in the metastatic lesion.

Several possible histogenetic theories have been advanced for this unusual tumor. Harvey and Hamilton suggested four possibilities: double tumor; carcinoma complicated by the development of a sarcoma either independently or as a result of exaggerated stromal reaction to the carcinoma; carcinoma with spindle cell variants of epithelial cells; and carcinoma with active but benign stromal reaction. Saphir and Vass offered two additional possibilities: carcinoma invading a benign fibroma or leiomyoma, and sarcoma invading normal or metaplastic epithelium. They con-

cluded that most such tumors were carcinomas with variations in histologic features. Before assessing these various possibilities, one must consider the morphologic features as well as the biologic behavior of these tumors. Some facts are clear. The majority of carcinosarcomas are large polypoid masses with limited invasion into the underlying tissue; the carcinomatous components are limited, often preinvasive, and may be found only at the base of the mass or in the adjacent mucosa. When they metastasize, the secondary foci are sarcomatous unless the carcinomatous tissue is extensive, as in the infiltrative variety. Lastly, polypoid carcinomas are rare in the esophagus. One, therefore, cannot avoid the impression that the tumor, especially the polypoid type, is composed primarily and principally of sarcomatous tissue. It is difficult to accept that preinvasive carcinoma or carcinoma with limited invasion will produce such a pronounced stromal response, or that the sarcomatous elements are in reality epithelial, particularly since the tumor is so totally different from esophageal carcinoma, both histologically and behaviorally. Therefore, the concept that these tumors represent true double tumors seems much more tenable. When the carcinoma develops early or overtakes the sarcoma by its invasiveness, an ulcerated infiltrating tumor results. In most cases, carcinoma seems to be a later complication. In this regard, Harvey and Hamilton's postulation that one malignant tissue stimulates the development of another malignant tissue may have some validity. In the esophagus, carcinoma seems to

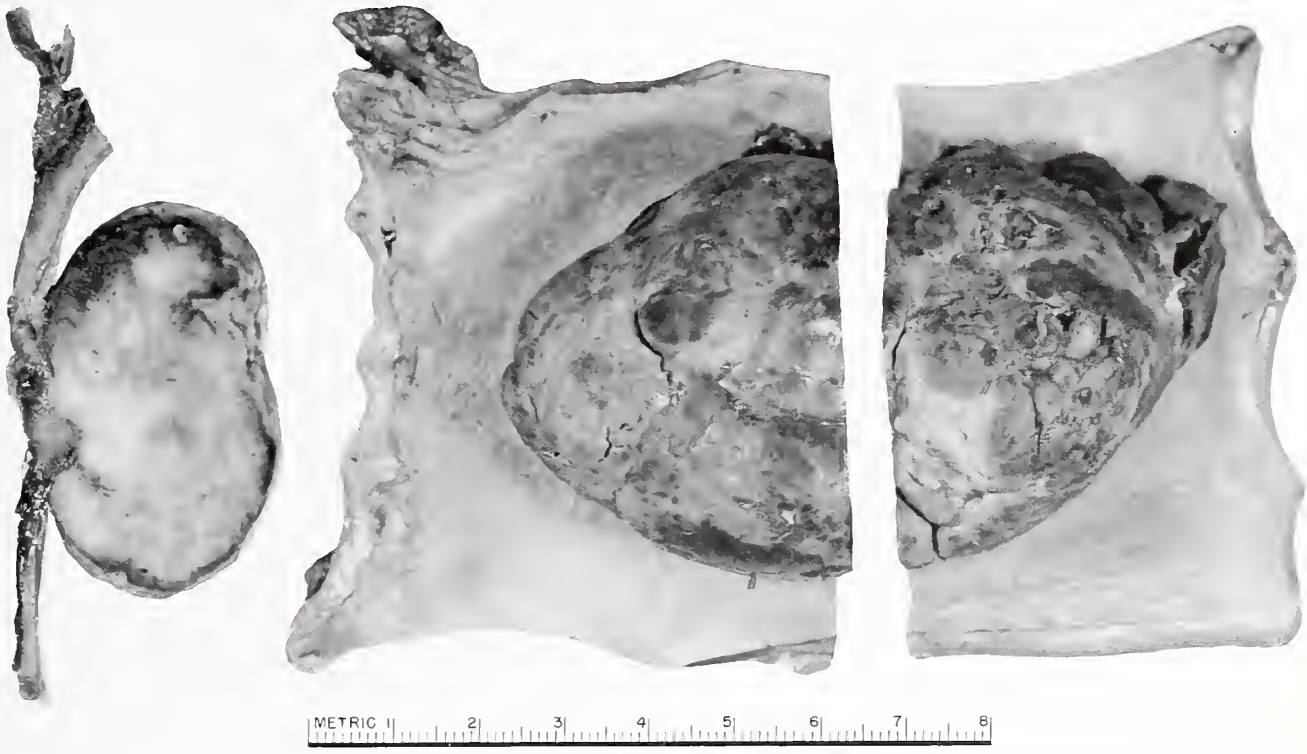

Fig. 64

CARCINOSARCOMA

(Figure 64 and Plate I-D from same case)

This carcinosarcoma found in the lower esophagus is also shown in plate I-D. The tumor is polypoid with a focally ulcerated mucosal surface. (Fig. 4 from Stout, A. P., Humphreys, G. H., II, and Rottenberg, L. A. A case of carcinosarcoma of the esophagus. Amer. J. Roentgen. 61:461–469, 1949; also fig. 50 from Stout, A. P., and Lattes, R. Tumors of the Esophagus. Fascicle 20, Atlas of Tumor Pathology. Washington: Armed Forces Institute of Pathology, 1957.)

develop more readily wherever the local tissue is altered, as in cases of benign stenosis, achalasia, hiatus hernia, and esophagus lined with columnar epithelium.

A polypoid tumor composed of active, bizarre sarcoma-like tissue and with preinvasive or invasive carcinoma in or near the main mass has been reported in the esophagus; it has been designated "pseudosarcoma" (figs. 67, 68). The seemingly sarcomatous tissue is considered nonmalignant since metastases do not occur. Lane reported 10 similar lesions occurring in the oral cavity and larynx and found only carcinoma cells producing metastasis. He suggested that the sarcoma-like tissue was a result of reaction to carcinoma and suspected that some carcinosarcomas were in reality pseudosarcomas as well. A similar view was presented by Stout and associates with regard to such tumors in the esophagus. The similarity between pseudosarcoma and carcinosarcoma is indeed remarkable. Many of the reported carcinosarcomas had only intra-

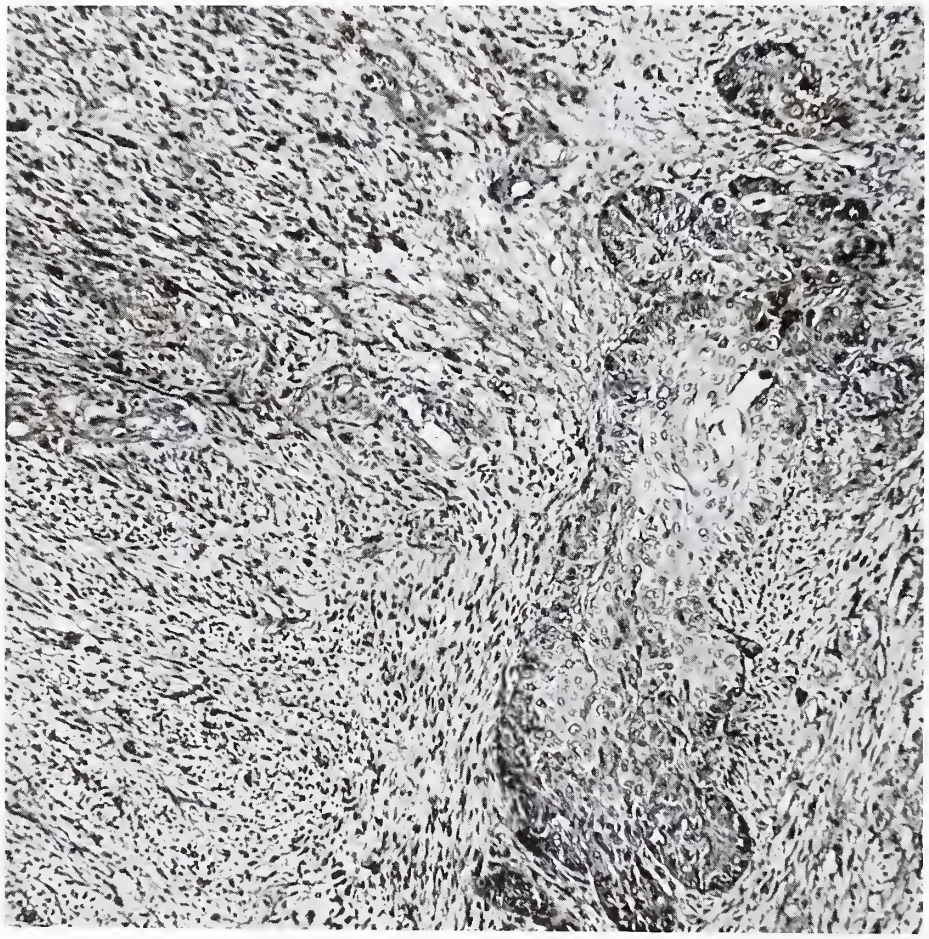

Fig. 65

CARCINOSARCOMA

(Figures 65 and 66 from same case)

This polypoid carcinosarcoma involved the middle and lower esophagus of a 55-year-old man. It is composed of islands of squamous cells in a stroma of atypical fusiform cells of apparent fibrous tissue nature, some of which have large nuclei. × 90 (Courtesy of Dr. Benjamin Lyne, St. Paul, Minn.; case presented by Dr. M. B. Dockerty at 32d Seminar of American Society of Clinical Pathologists, Washington, D. C., 1966.)

epithelial carcinoma at or near the base of the sarcomatous mass, and three of the pseudosarcomas reported by Lane had invasive and metastasizing squamous cell carcinoma in the main mass. The difficulty in distinguishing pseudosarcoma from carcinosarcoma is well demonstrated by the case of a 57-year-old man with a mobile polypoid mass in the midesophagus, reported by Hughes and Cruickshank. The histologic character of the resected lesion was at first thought to be compatible with pseudosarcoma. The patient died eight months later with local recurrence, extensive infiltration, and possible lymph node metastases. The malignant nature of this tumor is evident. The benignity of other reported cases is based on a follow-up of only a matter of months. The relative benignity of the sarcomatous elements in carcinosarcoma, with a low incidence of metastases and lack of extensive local invasion, is also well recognized. From evidence presented by sporadic case reports, it would seem preferable to regard all these tumors as carcinosarcomas, although the sarcomatous tissue pursues a relatively benign course and shows local infiltration but only occasional metastases. This

Fig 66

CARCINOSARCOMA

(Figures 65 and 66 from same case)

Another part of the tumor shown in figure 65 reveals cartilaginous tissue (upper) and osteoid tissue (right lower). × 90. (Courtesy of Dr. Benjamin Lyne, St. Paul, Minn.; case presented by Dr. M. B. Dockerty at 32d Seminar of American Society of Clinical Pathologists, Washington, D. C., 1966.)

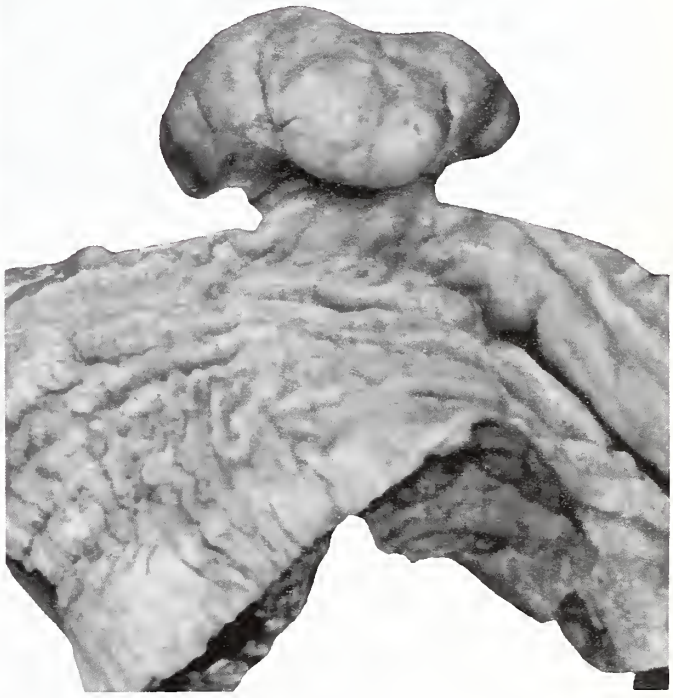

Fig 67

"PSEUDOSARCOMA"

This "pseudosarcoma" of the lower esophagus was found in an 80-year-old woman. The sarcoma-like tissue extended into the stalk and adjacent esophageal wall. Intraepithelial carcinoma was present in the mucosa near the stalk. (Fig 52 from Stout, A. P., and Lattes, R. Tumors of the Esophagus. Fascicle 20, Atlas of Tumor Pathology. Washington: Armed Forces Institute of Pathology, 1957; courtesy of Dr. D. L. Alcott, Los Gatos, Calif.)

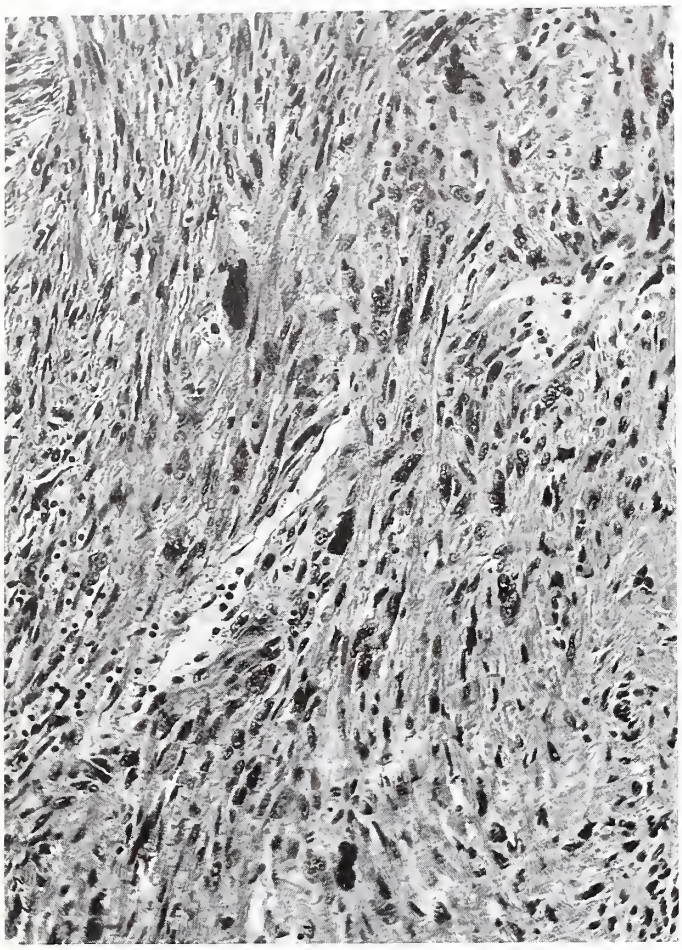

Fig 68

Fig 68

"PSEUDOSARCOMA"

This polypoid "pseudosarcoma" removed from the esophagus of a 70-year-old man is composed of interlacing bundles of fusiform cells with scattered bizarre forms. Mitoses were present, but rare. The resemblance to sarcomatous tissue in carcinosarcoma is evident (Fig 58 from Stout, A. P., and Lattes, R. Tumors of the Esophagus. Fascicle 20, Atlas of Tumor Pathology. Washington Armed Forces Institute of Pathology, 1957, courtesy of Dr J. A. Lyon, Jr., Baltimore, Md.)

is the behavior of other sarcomas of the esophagus, notably leiomyosarcoma, which is often polypoid and has a low rate of metastasis. When carcinomatous tissue is prominent and extensively invasive, a course similar to pure carcinoma may be expected. Because of the local invasiveness and presence of carcinoma in the adjacent mucosa, segmental resection rather than simple amputation appears to be the better choice of treatment for a polypoid lesion.

References

DeMarco, A. R., Leon, W., Coleman, W. O., Welsh, R. A., and Strug, L. H. Pseudosarcoma of the esophagus. J. Thorac. Cardiovasc. Surg. 49:188–193, 1965.

Fraser, G. M., and Kinley, C. E. Pseudosarcoma with carcinoma of the esophagus. A report of two cases. Arch. Path. 85:325–330, 1968.

Harvey, W. F., and Hamilton, T. D. Carcinosarcoma. A study of the microscopic anatomy and meaning of a peculiar cancer. Edinb. Med. J. 42:337–378, 1935.

Hughes, J. H., and Cruickshank, A. H. Pseudosarcoma of the oesophagus. Brit. J. Surg. 56:72–76, 1969.

Lane, N. Pseudosarcoma (polypoid sarcoma-like masses) associated with squamous-cell carcinoma of the mouth, fauces, and larynx. Report of ten cases. Cancer 10:19–41, 1957.

Moore, T. C., Battersby, J. S., Vellios, F., and Loehr, W. M. Carcinosarcoma of the esophagus. J. Thorac. Cardiovasc. Surg. 45:281–288, 1963.

Saphir, O., and Vass, A. Carcinosarcoma. Amer. J. Cancer 33:331–361, 1938.

Stener, B., Kock, N. G., Pettersson, S., and Zetterlund, B. Carcinosarcoma of the esophagus. J. Thorac. Cardiovasc. Surg. 54:746–750, 1967.

Stout, A. P., Humphreys, G. H., II, and Rottenberg, L. A. A case of carcinosarcoma of the esophagus. Amer. J. Roentgen. 61:461–469, 1949.

Talbert, J. L., and Cantrell, J. R. Clinical and pathologic characteristics of carcinosarcoma of the esophagus. J. Thorac. Cardiovasc. Surg. 45:1–12, 1963.

TUMORS OF THE STOMACH

INTRODUCTION

The stomach is a complex organ, both functionally and anatomically. Its digestive functions depend mainly upon the well recognized special cells of the mucosal glands: the pepsinogen-forming, zymogenic or chief cells; and the acid-secreting, oxyntic or parietal cells. The third major cell type is the mucus-secreting cell of the cardiac and pyloric glands. All these cells are vulnerable to injury and often decrease or even disappear, resulting in atrophic gastric mucosa. The mucus-secreting surface and foveolar or pit cells generally are retained, probably because of their ability to regenerate rather than their intrinsic resistance to injury. Thus, the foveolar cells at the isthmus and neck region of the gland have been found to degenerate readily; their disintegration may be responsible for loss of the glands underneath and resultant atrophy (Palmer).

Regeneration of foveolar cells maintains the integrity of gastric mucosa, at least the mucous cell covering. In rare instances, foveolar cells may reproduce the more specialized cells as well, but only in small numbers. Of more importance is the role of foveolar cells in the histogenesis of epithelial tumors of the stomach. Abnormal regeneration of foveolar cells may result in the histologic transformation of gastric mucosa to an intestinal type of mucosa (Ming et al.).

The stomach manifests a complicated response to injury. The resultant alterations of mucosa can be categorized under the general heading of gastritis which takes a variety of forms. Its chronic form has two chief manifestations: **chronic atrophic gastritis,** which has an atrophic mucosa and is almost always accompanied by intestinal metaplasia; and so-called **chronic hypertrophic gastritis,** which has a thickened mucosa accompanied by varying degrees of hyperplasia of glandular cells. The latter term is a misnomer and will be discussed later under **hyperplastic gastropathy.** Each of these manifestations has been related to the development of polyps and carcinoma (Schindler; Siurala and Seppälä).

As with the esophagus, carcinoma is the most important and the most common tumor in the stomach. Unlike the esophagus, gastric carcinoma is preceded or accompanied by a variety of mucosal alterations. Their malignant potential has caused a great deal of controversy and this will be discussed on pages 142 – 143 and 151 – 161. In all these conditions, the mucous cells, particularly the foveolar cells, are involved in proliferative activity, either in a relatively normal state or in a metaplastic form.

There has been a long-held belief that polyps of the stomach are precancerous because carcinoma often develops in them. In 1962, Monaco and associates challenged this concept, and as a result there is confusion and uncertainty concerning the significance of gastric polyps. An examination of the cellular characteristics readily observable in histologic sections of these polyps may help clarify their malignant potential. In these polyps, intestinal type metaplastic cells play an important role in their formation. This then raises the question of the relation of intestinal type metaplasia to gastric carcinoma (see pp. 151 – 161).

Table VI lists some of the reported series of tumors of the stomach; in all, carcinoma is by far the most frequent tumor. Cases from the Memorial Hospital of New York (McNeer and Pack) and

the Lahey Clinic of Boston (Marshall) were diagnosed during the patients' lifetime and the 92 percent incidence of gastric carcinoma reported in both series represents the clinical incidence. Stout's series included only resected carcinomas seen in the laboratory of surgical pathology. The cases from the University of Maryland Hospital included both surgical and postmortem specimens. The incidence of carcinoma is lower in these latter two series; this is probably due to the exclusion of inoperable carcinomas in Stout's series and the inclusion of various types of clinically silent tumors in the University of Maryland Hospital series.

Table VI
TUMORS OF THE STOMACH

Malignant Tumors	Stout	UMH*	McNeer and Pack	Marshall	Total	Percent Combined Series
Carcinoma	470	310	1623	1567	3970	87.9
Carcinoid	5	3	3		11	
Leiomyosarcoma	24	13	24	16	77	1.7
Rhabdomyosarcoma	1				1	
Lymphoma	39	23	39	35	136	3.0
Plasmacytoma	2	1			3	
Kaposi's disease	1				1	
Total	542	350	1689	1618	4199	93.0
Benign Tumors or Tumor-like Lesions						
Polyp	32	20	51	37	140	3.1
Leiomyoma	39	16	9	28	92	2.0
Vascular tissue tumors	8	1	1		10	0.2
Nervous tissue tumors	4		3		7	0.2
Lipoma	1		3	2	6	0.1
Fibrous tissue tumors		2			2	
Heterotopic pancreas	6	1	1	12	20	0.4
Enterogenous cyst		1	1		2	
Inflammatory lesions	19	4	7		30	0.7
Miscellaneous			3	3	6	0.1
Total	109	45	39	82	315	7.0
Series Total	651	395	1768	1700	4514	100.0

*The University of Maryland Hospital (series not previously reported)

References

Marshall, S F Symposium on surgery of digestive tract, gastric tumors other than carcinoma, report of unusual cases Surg Clin N Amer 35 693–702, 1955

McNeer, G., and Pack, G T Benign Tumors of the Stomach General Considerations, p 519 In Neoplasms of the Stomach Philadelphia J P Lippincott, 1967

Ming, S-C, Goldman, H, and Freiman, D G Intestinal metaplasia and histogenesis of carcinoma in human stomach Light and electron microscopic study Cancer 20 1418–1429, 1967

Monaco, A P., Roth, S I., Castleman, B, and Welch, C E Adenomatous polyps of the stomach A clinical and pathological study of 153 cases Cancer 15 456–467, 1962

Palmer, E D Gastritis A revaluation Medicine 33 199–290, 1954

Schindler, R Gastric carcinoma and gastritis with reference to coexistence of carcinoma and chronic hypertrophic glandular gastritis Amer J Dig Dis 10 607–624, 1965

Siurala M, and Seppala, K Atrophic gastritis as a possible precursor of gastric carcinoma and pernicious anemia Results of follow-up examinations Acta Med Scand 166 455–474, 1960

Stout, A P Tumors of the Stomach Fascicle 21, Atlas of Tumor Pathology Washington Armed Forces Institute of Pathology, 1953

EMBRYOLOGY

The part of the foregut destined to become the stomach is identifiable as a dilated segment behind the heart at the end of the fourth week of fetal life. During the second month it moves downward into the abdominal cavity. The foregut also moves to the left and rotates along its long axis so that the dorsal edge turns to the left and the ventral edge to the right. The faster growth of the dorsal edge forms the greater curvature and the slower growing ventral edge becomes the lesser curvature of the stomach. A fundic diverticulum appears during the ninth week of fetal life, which merges with the greater curvature in the twenty-fifth week to further increase the length of its left border.

Johnson made a detailed study of the development of gastric mucosa. He found that the gastric epithelium in a 7.5 mm. embryo (about fifth week of fetal life) was composed of a flat layer of columnar cells, 2 or 3-cells thick. Shallow pits were seen in a 16 mm. embryo (about the seventh week) and they became deeper and more numerous thereafter. Mucosal folds, also apparent at this stage, became progressively more prominent. The epithelial cells formed a single layer in a 55 mm. embryo (about tenth week) and mucus secretion was present in these cells in a 91 mm. embryo (about fourteenth week). The glands were formed at the end of the fourth fetal month; the parietal cells appeared before the chief cells. At the same time, branching of the glands also developed. These continued until birth, at which time the gastric mucosa appeared essentially identical to that seen in the adult. Kirk found that the parietal cells in the pig embryo were the first specialized cells to appear and both parietal and chief cells developed from nonmucoid cells. But Menzies noted the presence of mucinogen granules in the chief cells of the young rabbit fetus; these granules disappeared at a later date so he concluded that the chief cells were derived from mucous cells.

The muscularis externa of the gastric wall in man develops between the latter part of the second month and the early part of the fourth month. The muscularis mucosa is formed between the fourth and fifth fetal month (Botha).

References

Botha, G S M Organogenesis and growth of the gastroesophageal region in man Anat Rec 133 219–239, 1959

Johnson, F P The development of the mucous membrane of the oesophagus, stomach and small intestine in the human embryo Amer J Anat 10 521–561, 1910

Kirk, E G On the histogenesis of gastric glands Amer J Anat 10 473–520, 1910

Menzies, G Observations on the developmental cytology of the fundic region of the rabbit's stomach, with particular reference to the peptic cells Quart J Microscopic Sci 99 485–496, 1958

ANATOMY

GROSS. The stomach is an abdominal organ normally situated in the left hypochondrium and epigastrium. In rare instances, it may be located partly in the mediastinum, as is the case with a congenitally short esophagus. The convex greater curvature which forms the left border of the stomach is about 2 to 3 times as long as the concave lesser curvature which forms its right border. The stomach begins at the cardia left of the midsagittal line and ends at the pylorus to the right of the midsagittal line. It is often arbitrarily divided into four portions: cardia, fundus, body, and pyloric antrum or simply antrum. The narrow distal portion of the antrum is also called the pyloric canal. The cardia is the region immediately distal to the esophagus and is about 2 to 3 cm. in width. The fundus is the out-pouching at the left upper portion of the stomach, lying above a horizontal line drawn at the level of the esophagogastric junction in an erect position. This portion is developed postnatally, probably due to distention of the stomach. The body of the stomach is demarcated from the antrum by a notch at the lesser curvature, the incisura angularis, at about the junction of the middle and distal thirds of the curvature. From the notch, a line is drawn downward and to the patients' left toward the greater curvature to separate the body of the stomach from the antrum. This arbitrary division generally makes the length of the greater curvature of the antrum about twice that of the lesser curvature. While these divisions serve as a general guide for the location of lesions in the stomach, it does not always correlate with the gross appearance of the mucosa. In the open stomach, the mucosa in the fundus and the body is identical; its redundancy causes it to form many long-branching folds or rugae, roughly parallel to the long axis of the stomach, except at the lesser curvature where there is generally no fold. The height of the rugae depends upon the degree of dilatation of the organ. The thickness of the mucosa is about 1 mm. The mucosa in the antrum is thinner and there are a few small folds, depending upon the degree of dilatation.

The stomach has a rich network of communicating lymphatic vessels throughout its wall. They drain into six groups of lymph nodes: paracardial; superior gastric; subpyloric; inferior gastric; splenic; and pancreatic nodes (fig. 69). From these nodes, the lymphatics join the mediastinal, hepatic, and mesenteric systems. The nodes are situated along the major arteries. The arterial blood derives from the coeliac axis (fig. 69). The left gastric artery and the right gastric branch of the hepatic artery supply the lesser curvature of the stomach. The left gastroepiploic branch of the splenic artery and the right gastroepiploic branch of the gastroduodenal artery supply the greater curvature. The veins enter the portal system through the pyloric vein, the gastric and left gastroepiploic branches of splenic vein, the right gastroepiploic branch of the superior mesenteric vein, and the coronary vein. The coronary vein receives blood from the lesser curvature of the stomach and communicates with the esophageal vein, thereby serving as a link between the portal and systemic systems.

HISTOLOGIC MORPHOLOGY. The arbitrary gross divisions of the stomach may give the impression that they correspond to the location of the three types of gastric glands: the cardiac glands in the cardia, fundic glands in the fundus and body, and pyloric glands in the pyloric antrum. This assumption is incorrect. A meticulous study done by Oi and associates revealed a wide variation in the location of the borderline zone between the areas occupied by the fundic glands and areas occupied by the pyloric glands. In the majority of stomachs, the pyloric glands occupied an area extending proximally 4 to 9 cm. from the pylorus at the lesser curvature and 4 to 8 cm. in the greater curvature with extremes varying from 0 to 16 cm. from the pylorus. A similar though less striking observation made by Landboe-Christensen revealed that the pyloric glands occupied the

distal 11 to 15 percent of the length of the greater curvature and 35 to 44 percent of the length of the lesser curvature. The total area occupied by the pyloric glands was 11 to 18 percent of the entire gastric mucosa. In view of these observations, Grossman proposed dividing the gastric mucosa according to histologic forms into the fundic gland and pyloric gland areas to correlate with their physiologic characteristics. For a better understanding of the pathologic alterations, a histologic division of the gastric mucosa is much more meaningful than an arbitrary gross division. To locate the lesions grossly, it is better to use the border areas of the stomach, such as the cardiac end, pylorus, and the curvatures as the points of reference. The fundic and pyloric areas referred to later are based on their histologic division.

There are three types of gastric glands; namely, cardiac, fundic, and pyloric glands. Cardiac glands are morphologically similar to pyloric glands, but they are more separated and appear

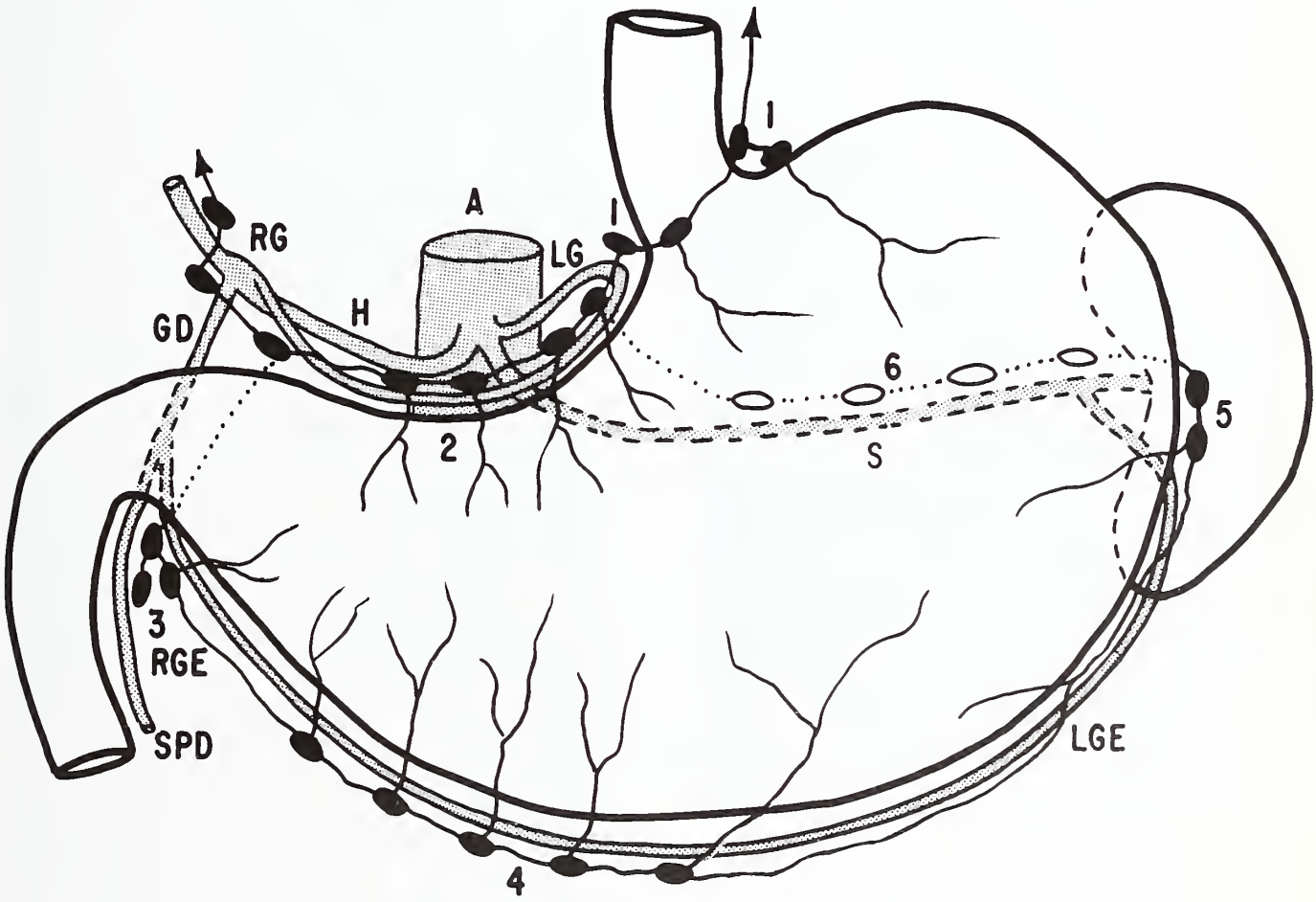

Fig 69

ARTERIAL AND LYMPHATIC SYSTEMS OF THE STOMACH

A schematic diagram of the arteries of the stomach illustrates A, aorta. LG, left gastric artery. H, hepatic artery. RG, right gastric artery; GD, gastroduodenal artery. RGE, right gastroepiploic artery; S, splenic artery; LGE, left gastroepiploic artery, and SPD, superior pancreaticoduodenal artery The lymph nodes are situated along the arteries and consist of six groups (1) paracardiac nodes; (2) superior gastric nodes; (3) subpyloric nodes, (4) inferior gastric nodes; (5) splenic nodes; and (6) pancreatic nodes.

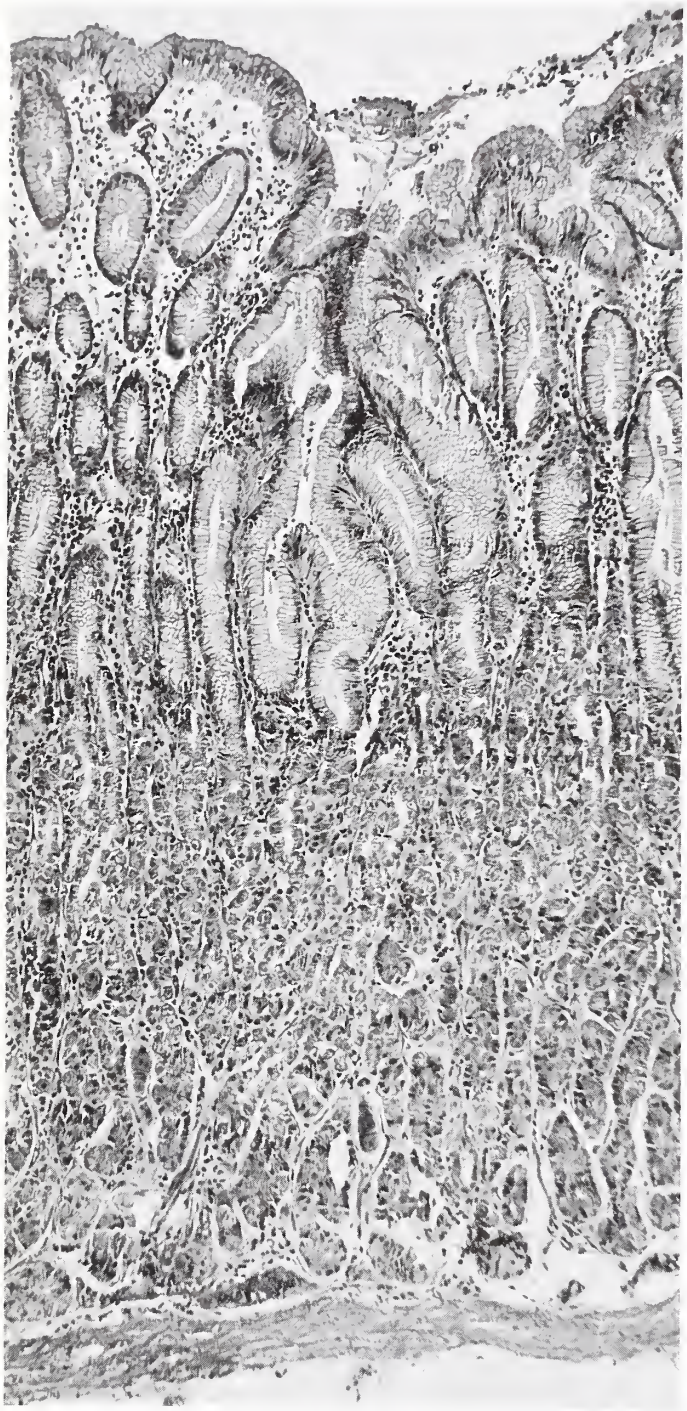

Fig 70

NORMAL FUNDIC MUCOSA

The fundic mucosa has pale mucous cells lining the surface and foveolae or pits. These cells have basally located, oval or compressed nuclei, and a cup-shaped clear supranuclear zone containing mucus. The glands branch at various levels in the crypt. The upper lamina propria is loose and contains a few lymphocytes, occasional plasma cells, and eosinophils. The deep portion of mucosa is packed with straight tubular glands in which the parietal and chief cells and scattered neck mucous cells lie. × 80.

less compact. They are restricted to a narrow zone, measuring about 1 to 1.5 cm., at the cardiac end. The pyloric and fundic glands have the same type of mucous cells covering their surface and lining the foveolae or pits. The foveolae occupy approximately one-fourth to one-half the depth of the fundic glands and one-third to one-half the depth of the pyloric glands (figs. 70, 71).

The difference between the fundic and pyloric glands lies in their cellular structure. The fundic glands are straight tubules, composed of parietal or oxyntic cells, primarily located in the superficial portion; the chief, zymogenic or peptic cells, rest in the deeper portion of the glands, with scattered neck mucous cells among them. The pyloric glands are coiled, being composed entirely of mucous cells. A small number of parietal cells may be seen, but no chief cells are evident (fig. 72). Occasional argentaffin cells are present at the bottom of the glands. Transition from the fundic to the pyloric area may be sudden or gradual; in most stomachs the borderline zone is less than 2 cm. in width (Oi et al.).

Functionally, the parietal cells secrete HC1, blood group substances, and intrinsic factor. The parietal cell population correlates well with peak HC1 secretion following histamine stimulation (Konturek and Urban). The chief cells secrete electrolytes, pepsinogen, and other proteolytic proenzymes; the mucous cells secrete mucosubstances of variable chemical composition, blood group substances, and electrolytes (Glass). Gastrin is extracted only from the pyloric mucosa and is probably secreted by the pyloric glands. Cell renewal studies have revealed the chief and parietal cells to be inactive, whereas the mucous cells actively proliferate, particularly the foveolar cells in the region of the isthmus of the gland (Bertalanffy). From these cells, the surface epithelium is renewed normally, and in abnormal conditions, these cells may form metaplastic intestinal epithelium or even neoplastic cells (Ming et al.; Planteydt and Willighagen; Teir and Räs-

anen). Neck mucous cells may reproduce the parietal and chief cells (Hunt). The cardiac and pyloric gland mucous cells reproduce themselves (Bertalanffy). But special attention must be given to the foveolar mucous cells in the diseased gastric mucosa.

Surface and **foveolar cells** are identical. There is a gradual decrease in the amount of intracellular mucus in the direction of the isthmus. In hematoxylin and eosin stained sections, the cup-shaped supranuclear cytoplasm, which is weakly eosinophilic and clear, contains sparse fine granules (figs. 71, 72). Periodic acid-Schiff reaction shows the dark red mucin granules located in the apical portion of the cells (pl. II-A; fig. 72). In the electron micrograph, the apical location of the mucin granules is also evident whereas the mid-portion of the cytoplasm is occupied by mitochondria, supranuclear Golgi apparatus, and sparse endoplasmic reticulum (fig. 74). Mucin granules are dense, small and round, oval or disk-shaped. The microvilli of these cells are poorly developed, sparse, and short. The PAS positive mucus is neutral glycoprotein and, therefore, has no affinity for alcian blue (pl. II-B). Mucicarmine stain is weakly positive. Carboxylated acid mucin, which is alcian blue stainable at pH 2.5 but not at pH 1.0, and not metachromatically stainable by toluidine blue, is present in scattered cells in the deep portion of the foveolae (fig. 75). A weak staining reaction for sulfated acid mucin is occasionally obtained in the deep foveolar cells in the antrum (Goldman and Ming). The fine granules in the neck mucous cells and the pyloric and cardiac gland cells are stainable by PAS reaction only. Weak staining suggests that these granules are more sparsely distributed than those in the foveolar cells (pl. II-A; fig. 73).

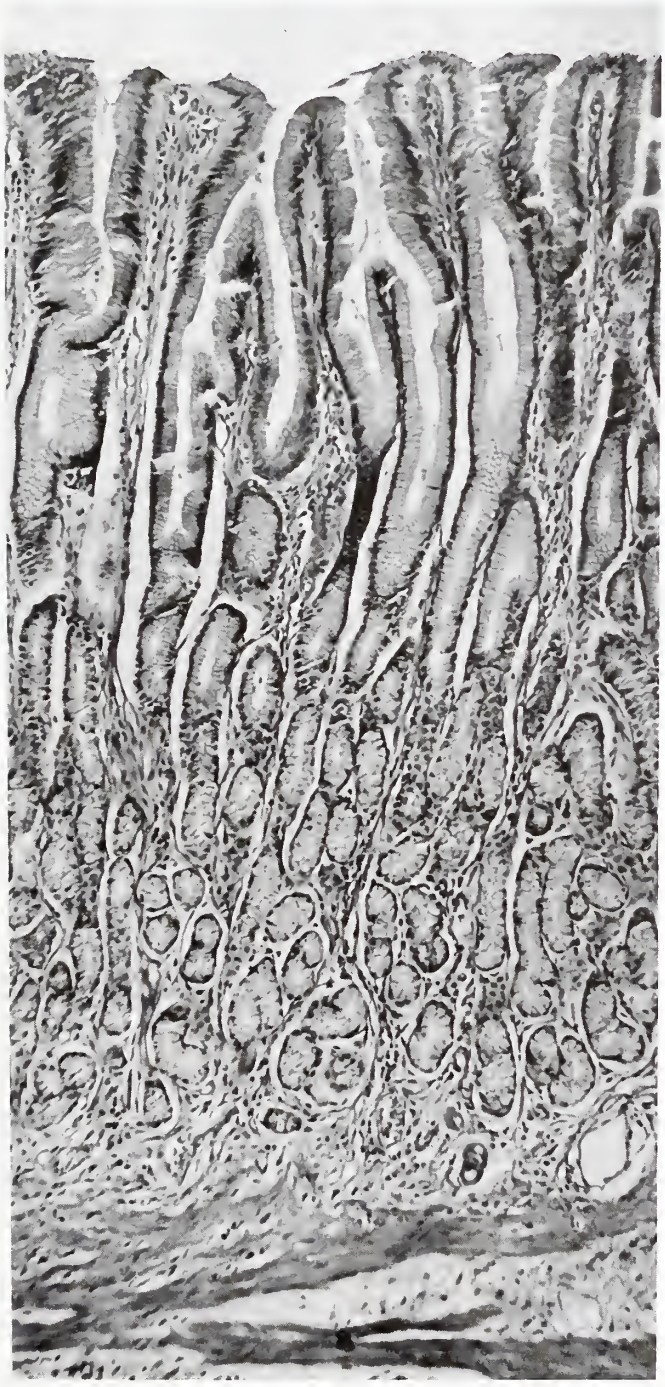

Fig. 71

Fig 71

NORMAL PYLORIC MUCOSA

The superficial portion of the pyloric mucosa is identical with that of the fundic mucosa. The pyloric glands are coiled, particularly in the deep portion. Their mucous cells have a finely granular cytoplasm. The basally located nuclei are round and smaller than those of the foveolar cells. The glands are not as compact as the fundic glands, and the lamina propria is more prominent than that in the fundic mucosa. × 95.

Fig. 72

PARIETAL CELLS IN PYLORIC MUCOSA

Parietal cells with large, round, centrally located nuclei are present in the neck portion of the pyloric glands. The foveolar mucous cells above them have a relatively clear supranuclear cytoplasm, whereas the mucous cells of the glands shown in the lower portion have fine granules throughout the cytoplasm. × 450.

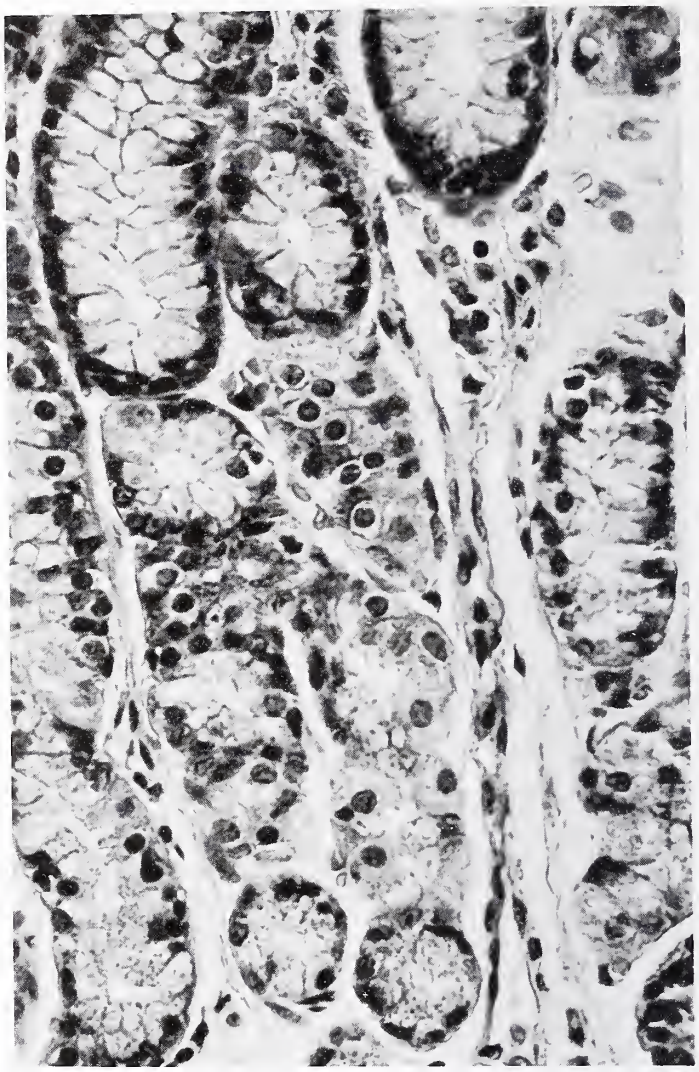

Fig. 72

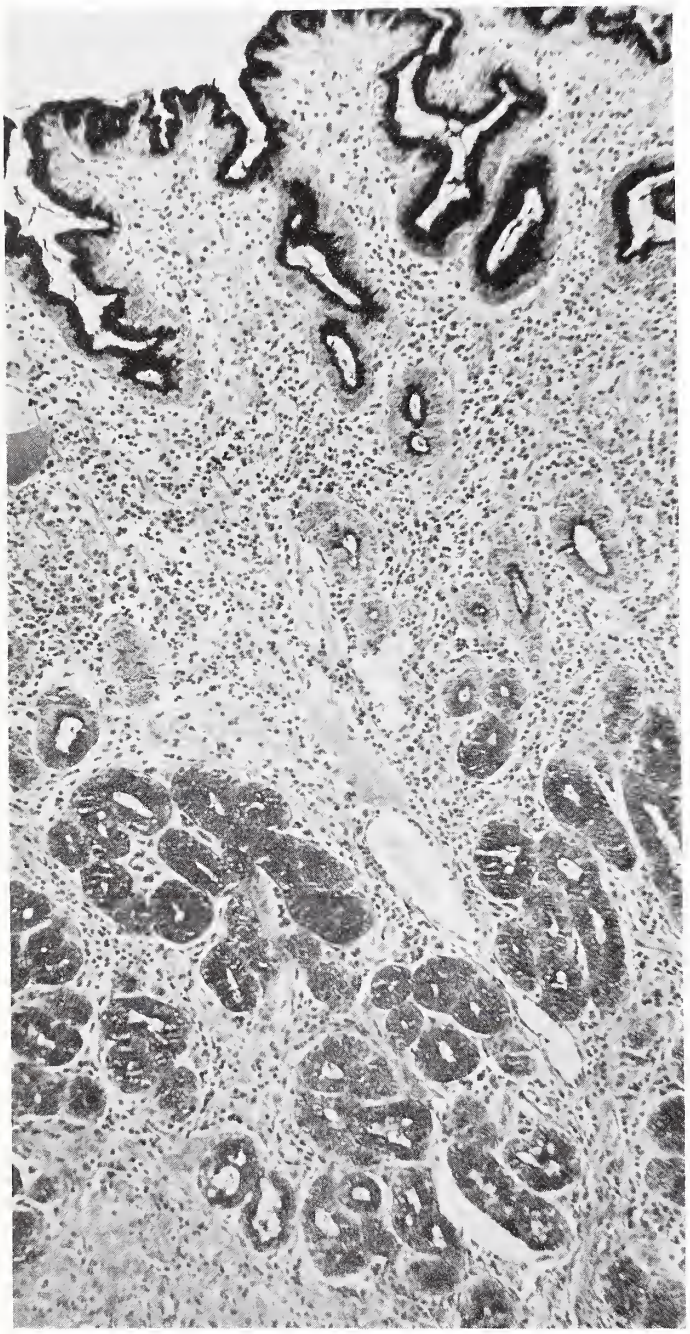

Fig. 73

Fig. 73

PYLORIC MUCOSA

This section of pyloric mucosa is stained by the periodic acid-Schiff (PAS) method. The surface and foveolar mucous cells are deeply stained in their apical portion. A much smaller amount of mucus is present in the cells in the deep foveolar and neck regions. The PAS positive granules in the pyloric gland cells are distributed uniformly throughout the cytoplasm. The granules are more scattered and the staining appears weaker in these cells than the surface cells. A mild chronic inflammation is present. × 90.

FOVEOLAR MUCOUS CELLS

Fig. 74

This electron micrograph of normal foveolar cells shows densely packed dark mucin granules in the apical portion of the cells. The granules are relatively uniform; most are round, but some are oval or discoid. A few dark granules in the midportion of the cell are either lipid or lysosomes. Mitochondria, ribosomes, and sparse endoplasmic reticulum are scattered in the cytoplasm. The Golgi system is situated supranuclearly. The nuclei are oval with prominent nucleoli. × 3200.

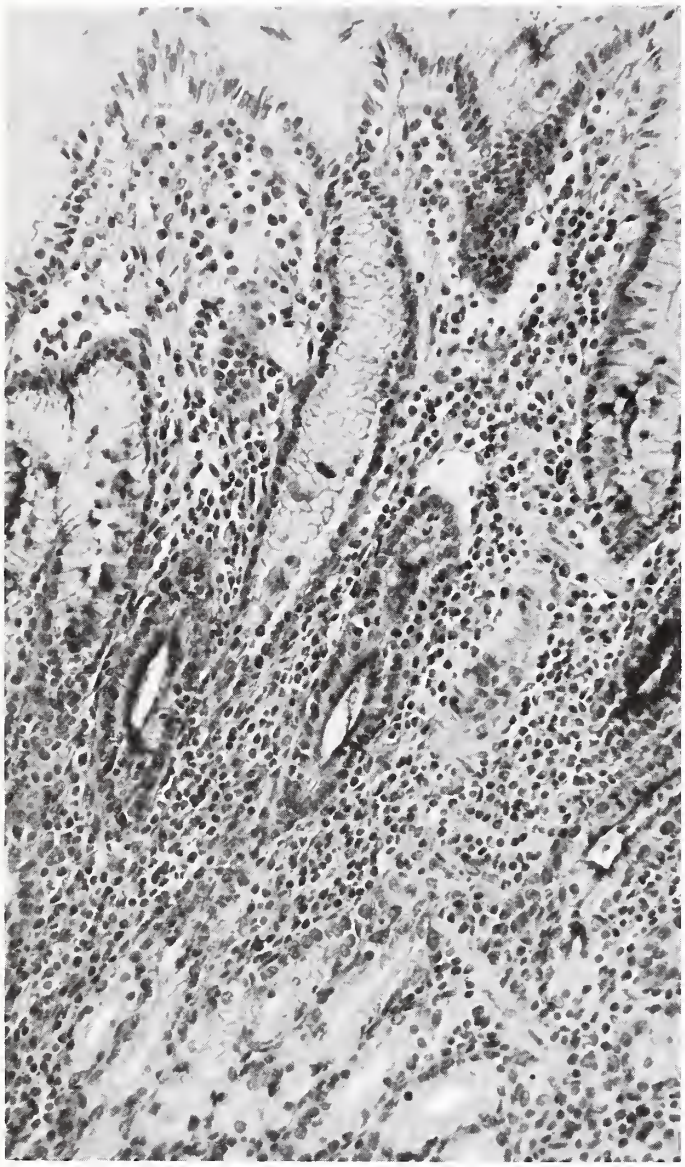

Fig. 75

ACID MUCIN IN DEEP FOVEOLAR CELLS

This midportion of the pyloric mucosa is stained by alcian blue at pH 2.5. Dark acid mucin is present in variable amounts in the apical portion of the deep foveolar cells. The pyloric gland cells shown at the bottom are negative. There is moderate chronic gastritis. × 260.

INTESTINAL METAPLASIA

Intestinal metaplasia occurs frequently in atrophic gastric mucosa, particularly in the pyloric area. Although considered to be a form of heterotopia by some investigators (Rubin et al.; Taylor), its metaplastic origin is generally accepted. This view is supported by its increased frequency in the aged and in those who have diseased gastric mucosa (Goldman and Ming). Focal metaplasia is also observed occasionally in the foveolae of otherwise normal appearing glands, but it is frequently accompanied by chronic gastritis. The inflammation is not always significant, however. In pernicious anemia, metaplasia is most severe in the atrophic fundic mucosa, often without overt chronic inflammation (Magnus; Morson). Mucosa with fully developed metaplasia closely resembles the mucosa of the small intestine, although the villi are usually short and blunt, and preserved gastric glands are present in some areas (fig. 76). The cell renewal cycle in metaplastic glands is also similar to that of the normal intestines (Winawer and Lipkin). Metaplastic mucosa has many goblet cells interposed by nonmucus-secreting columnar cells having distinct striated borders (fig. 77; pl. II-B and C). Paneth cells are present at the bottom of the glands and the number of argentaffin cells are increased. The goblet cells secrete acid mucin which occupies most or all of the supranuclear portion of the cytoplasm, and stains brilliantly by mucicarmine, PAS, and alcian blue at pH 2.5 (fig. 77; pl. II-B and C). Weak staining with alcian blue at pH 1.0 and slight metachromasia are sometimes observed. Thus, mucin in the goblet cells is chiefly carboxylated, but a small amount of sulfated mucin may also be present. Electron microscopy reveals that metaplastic glands closely resemble intestinal glands. The goblet cells are filled with large, pale, finely mottled mucin granules which are packed in most or all of the supranuclear portion of the cytoplasm (fig. 78). The mucin granules are expelled through the apex of the cell typical of apocrine secretion. Mitochondria and prominent endoplasmic reticulum are compressed to the lateral positions. There is a prominent supranuclear Golgi system in which occasional mucin granules may be found. The intervening columnar cells have well developed and closely arranged microvilli, numerous mitochondria, and interdigitating lateral cell membranes (fig. 79).

INTESTINAL METAPLASIA

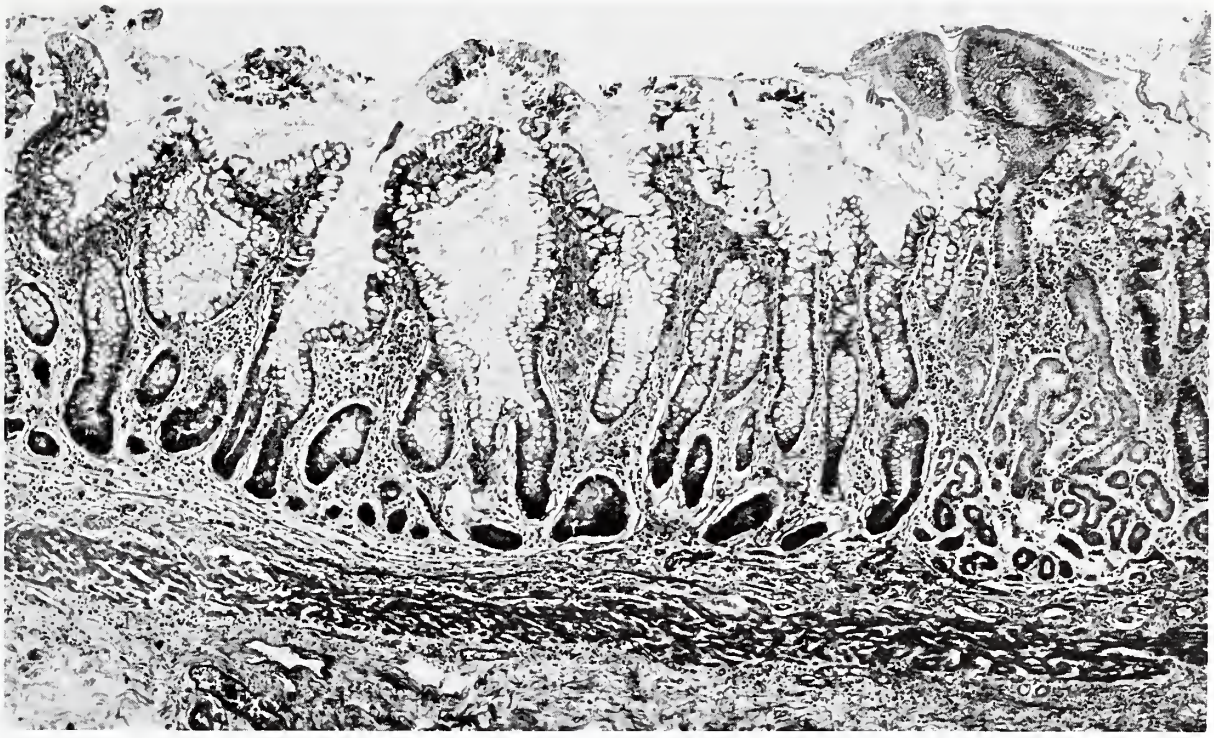

Fig 76

This section of pyloric mucosa, adjacent to a carcinoma in an 82-year-old man, shows marked intestinal metaplasia with villi and crypt formation A group of pyloric glands is seen on the right × 55

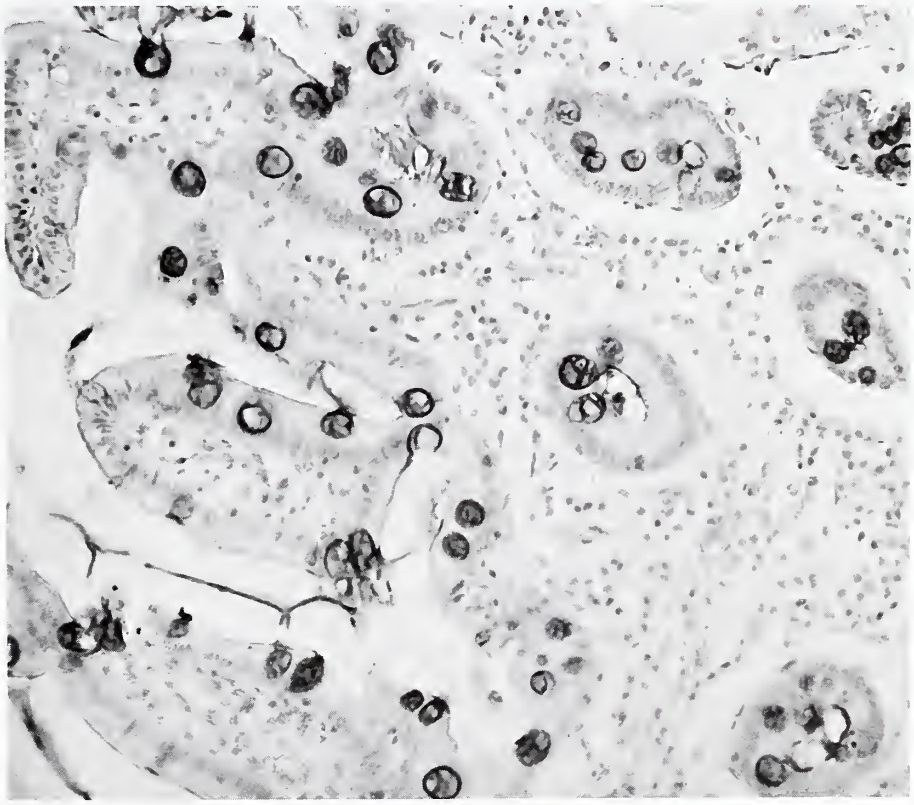

Fig 77

Alcian blue stain at pH 2.5 shows darkly stained acid mucin in the goblet cells The interposed columnar cells have no mucin secretion, but have a well developed striated border best shown at the left upper corner In other areas the striated border is shown as a dark line because of the staining of trapped mucin × 220

Fig. 78

INTESTINAL METAPLASIA

This electron micrograph of metaplastic mucosa shows goblet cells filled with pale mucin granules in the apical half of the cytoplasm. These cells also have prominent endoplasmic reticulum and supranuclear Golgi areas; the latter contain a few mucin granules. Mucin granules extrude through the apex of the cells and appear to be secreted in apocrine fashion. The interposed columnar cells have a few dark granules, but no mucin. These cells have well developed microvilli and many mitochondria. × 4500.

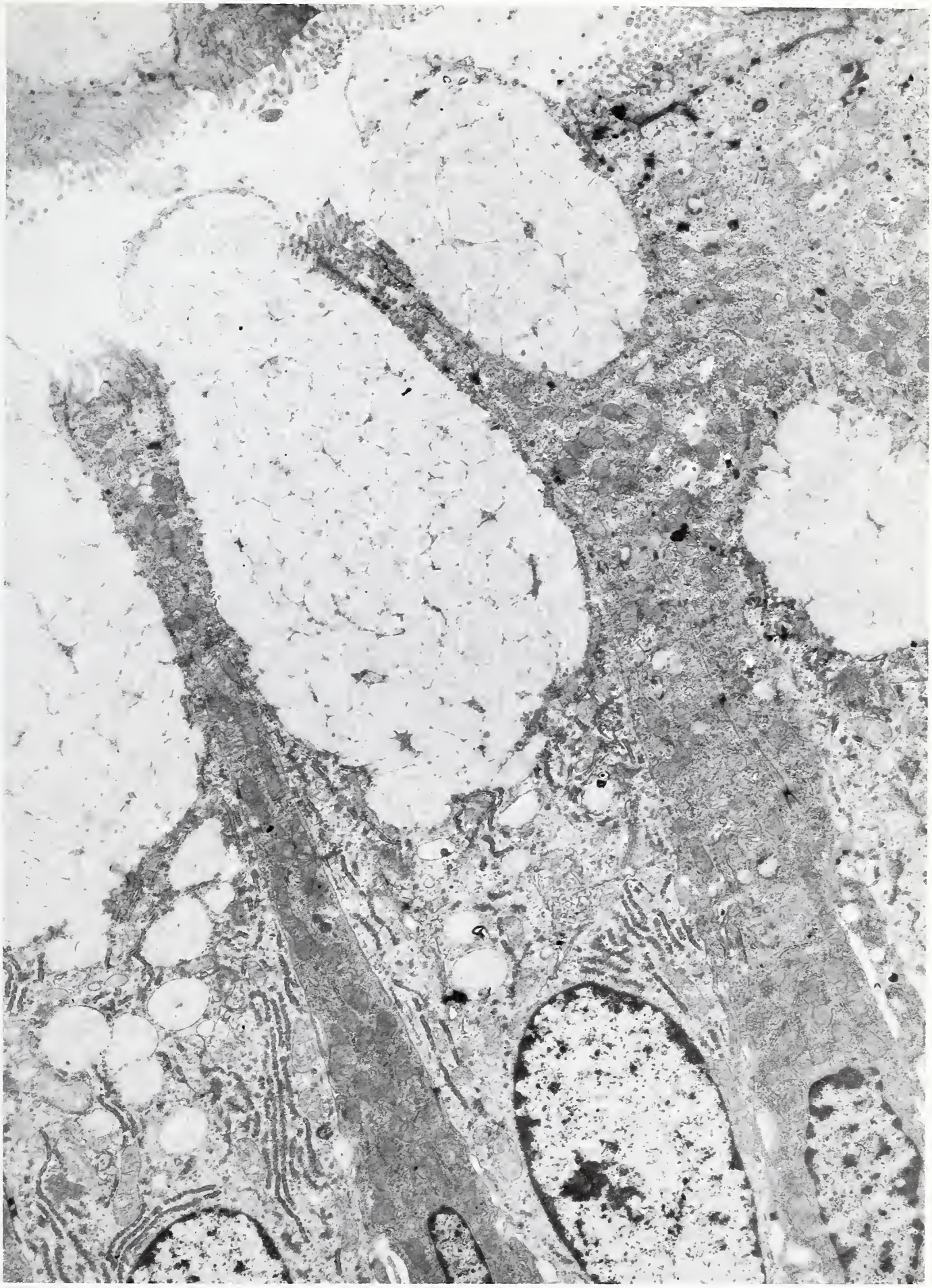

Fig. 78

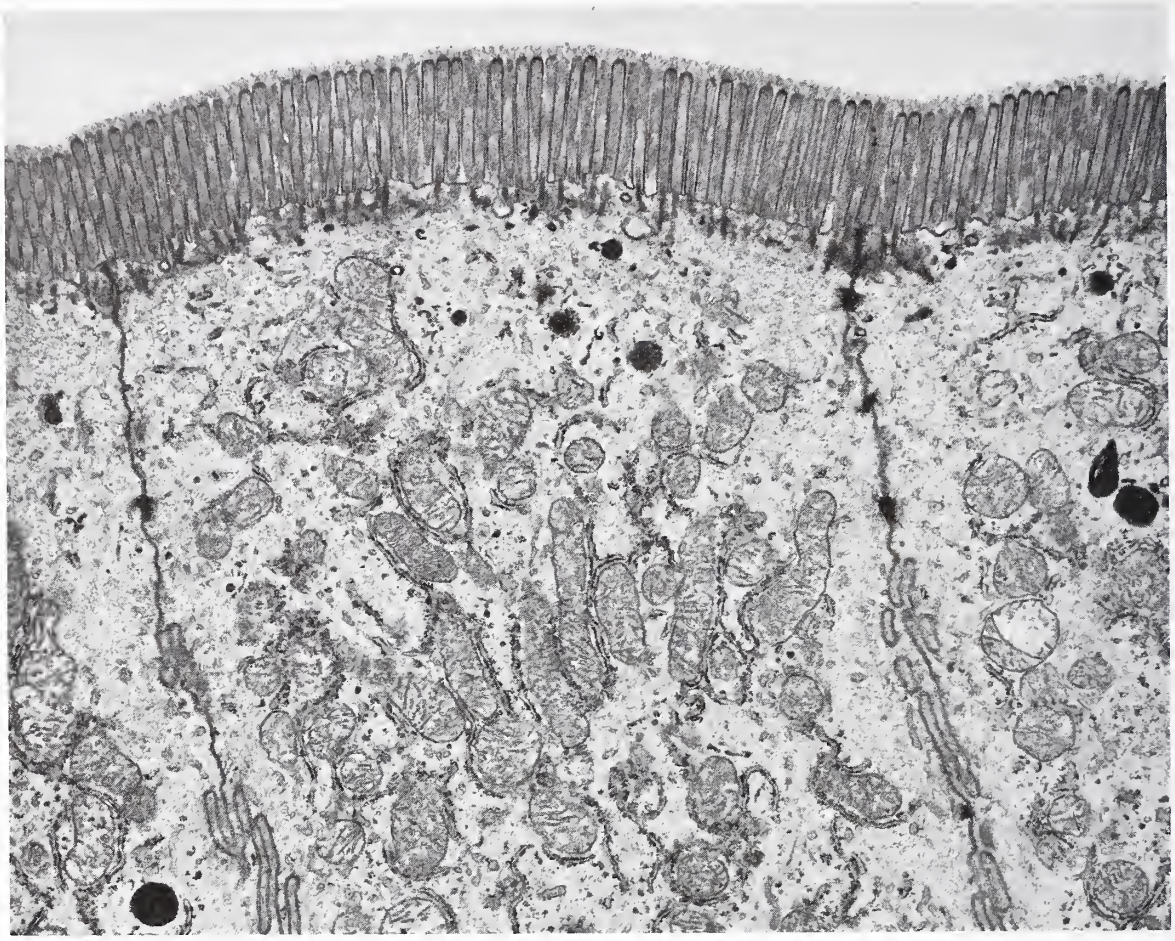

Fig 79

INTESTINAL METAPLASIA

This electron micrograph of the apical portion of columnar cells in a metaplastic gland shows closely arranged, well developed microvilli with terminal webs in the cytoplasm immediately underneath. The lateral cell membrane shows convoluted, interdigitated plication and desmosomes. There are a few dense lipid granules, but no mucin granules are present. × 9900

Metaplastic glands are often hyperplastic, showing low columnar cells and frequent mitoses with a decrease in goblet cells. The microvilli of hyperplastic cells are irregularly developed, more sparse, and shorter than those of regular cells and the terminal webs are irregular, both in length and distribution (fig. 80). Enzymes such as alkaline phosphatase (fig. 81) and aminopeptidase (fig. 82) normally present in the intestinal mucosa, but absent in the gastric mucosa give positive reactions. On occasion, the metaplastic process appears incomplete. Histochemical stains for mucin (pl. II – D) and electron microscopy (fig. 83) reveal that goblet cells may be found among foveolar cells with mixed mucins. These findings support the concept that metaplastic epithelium represents altered foveolar cells.

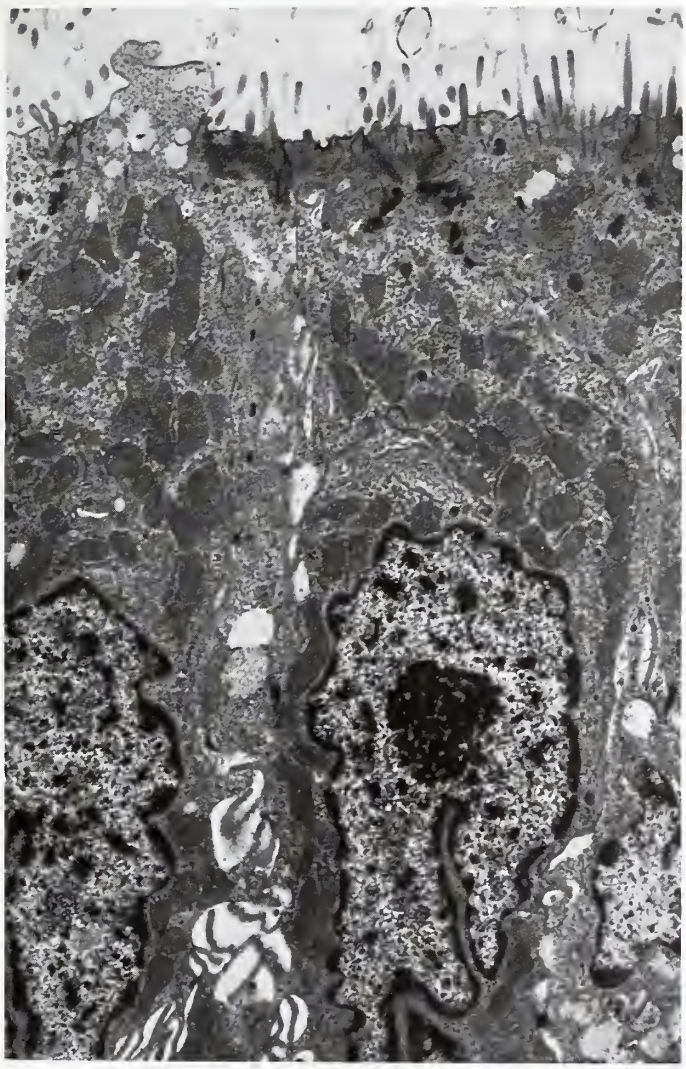

Fig. 80

Fig 80

INTESTINAL METAPLASIA WITH HYPERPLASIA

This electron micrograph of hyperplastic cells in metaplastic glands shows sparse, irregularly developed microvilli, which are longer than those of normal foveolar cells but shorter than those of regular metaplastic cells shown in figure 79. The terminal webs are irregular. The cells are short and contain many mitochondria. × 4500.

Fig. 81

ALKALINE PHOSPHATASE IN METAPLASTIC MUCOSA

This cryostat section of metaplastic mucosa was stained for alkaline phosphatase, using glycerophosphate as substrate according to the method of Gomori. There is a strong positive reaction, particularly in the superficial area. The endothelium of the capillaries is also stained. × 150.

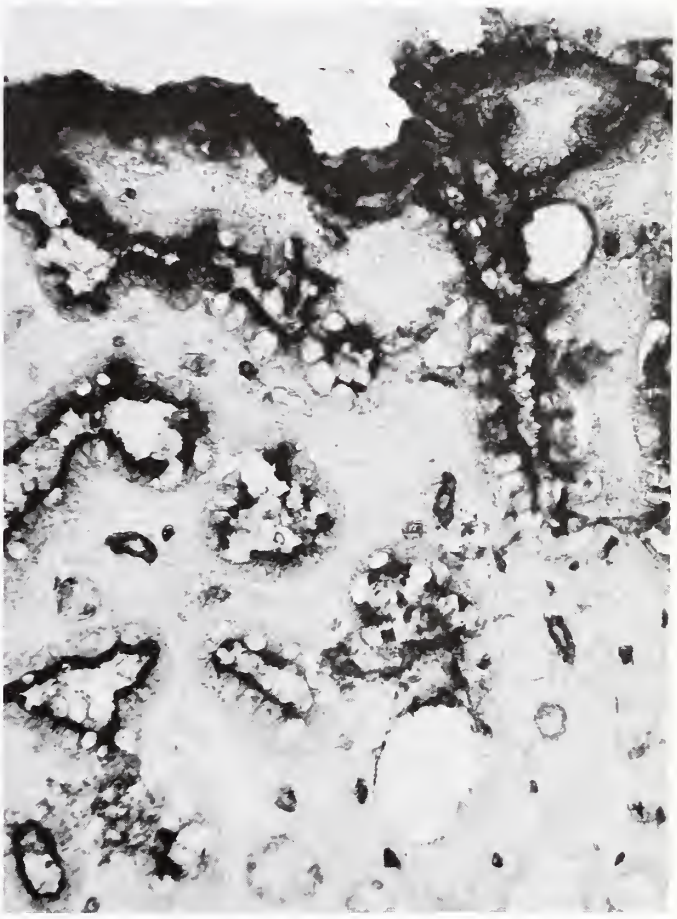

Fig. 81

PLATE II

FUNDIC MUCOSA

A. Periodic acid-Schiff (PAS) stain of the normal fundic mucosa shows dark red glycoprotein in the apical portion of the surface and foveolar cells; and weakly stained neck mucous cells. The parietal cells are PAS negative. × 125.

FUNDIC MUCOSA WITH INTESTINAL METAPLASIA

B. Alcian blue stain at pH 2.5 shows negative staining of the normal fundic glands on the left and strongly stained goblet cells in the metaplastic glands. The intervening columnar cells in the latter are not stained, but their striated border is partly stained blue because of trapped mucin. The bottom portion of the metaplastic glands is hyperplastic. A moderate number of lymphocytes are present in the lamina propria. × 125.

PYLORIC MUCOSA WITH INTESTINAL METAPLASIA

C. Periodic acid-Schiff (PAS) stain reveals the intensely stained normal surface and foveolar cells, and weakly stained normal pyloric gland cells on the top. The metaplastic mucosa on the bottom shows PAS positive mucin in the goblet cells and negative staining of the intervening columnar cells. A weak PAS positive line outlines the striated border of the columnar cells. The cells at the deep portion of the metaplastic glands are hyperplastic and less differentiated. A moderate lymphocytic infiltration is present in the lamina propria. × 125.

PYLORIC MUCOSA WITH INCOMPLETE METAPLASIA

D. This section of pyloric mucosa was stained by a combined periodic acid-Schiff (PAS) alcian blue (AB) technic. The glands on the top are normal and stained only by PAS. The second gland from the bottom shows complete intestinal metaplasia with AB positive goblet cells and negative staining columnar cells. The glands between show AB positive goblet cells and variable red to purple staining of the intervening cells, indicating the presence of both neutral glycoprotein and acid mucin. A mild chronic inflammation is present. × 125.

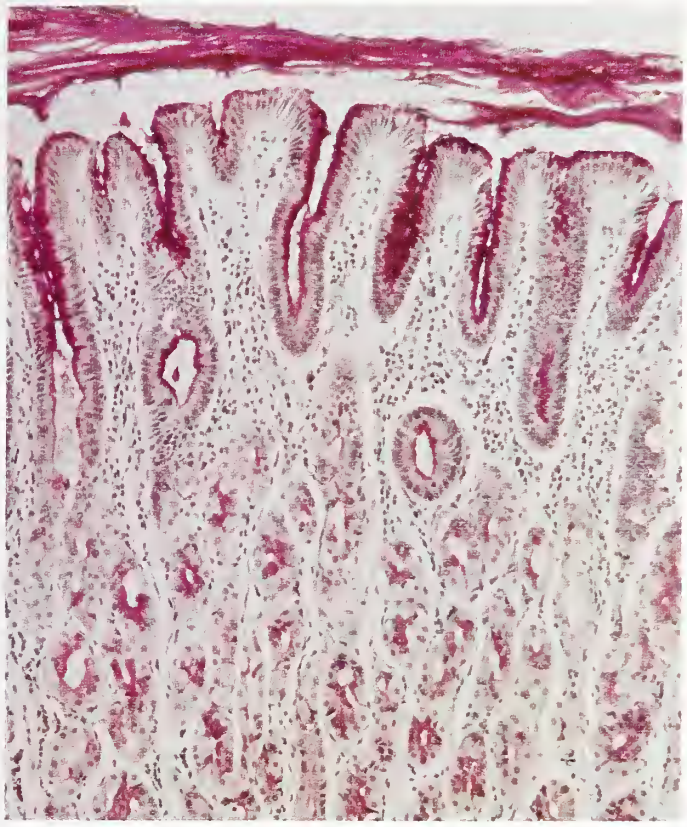

A

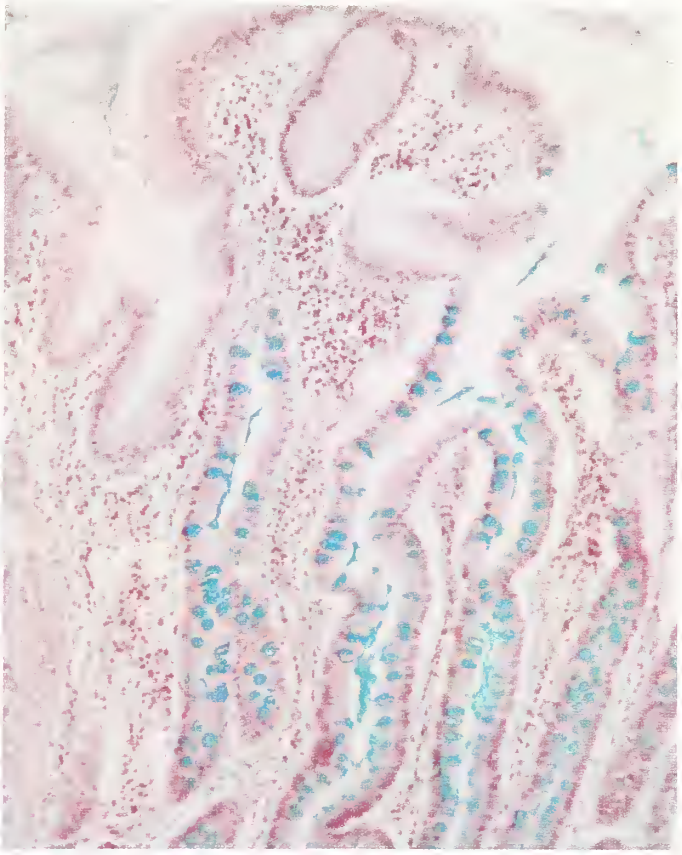

B

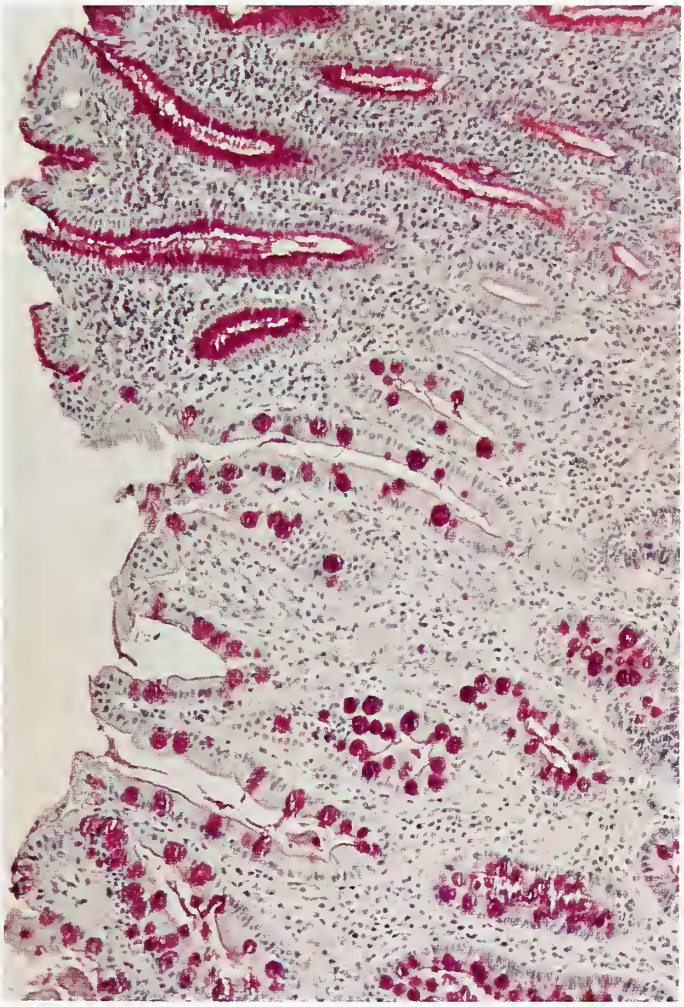

C

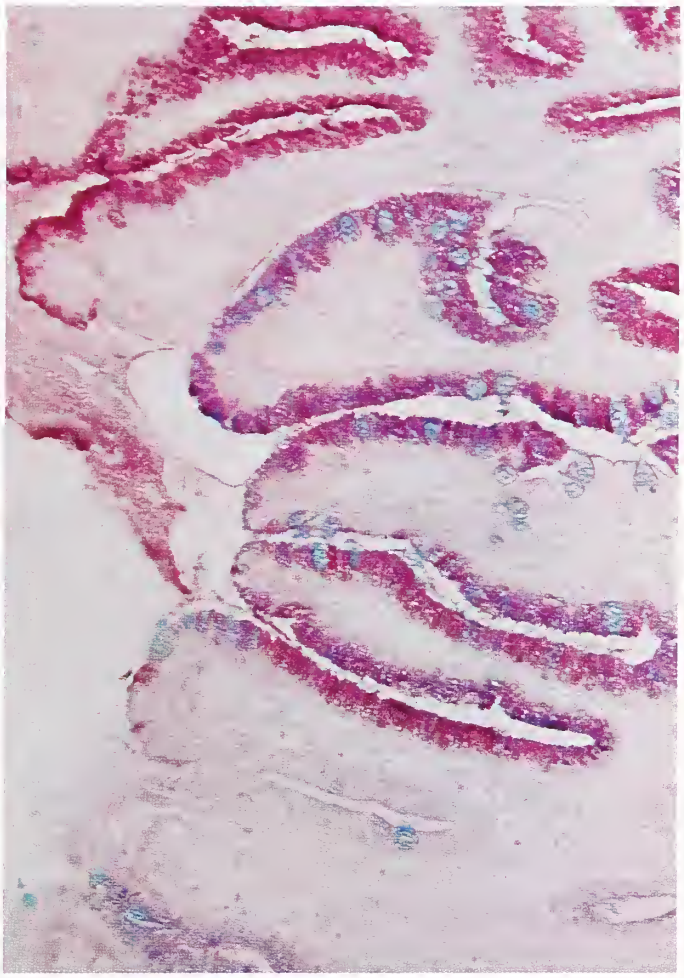

D

PLATE II

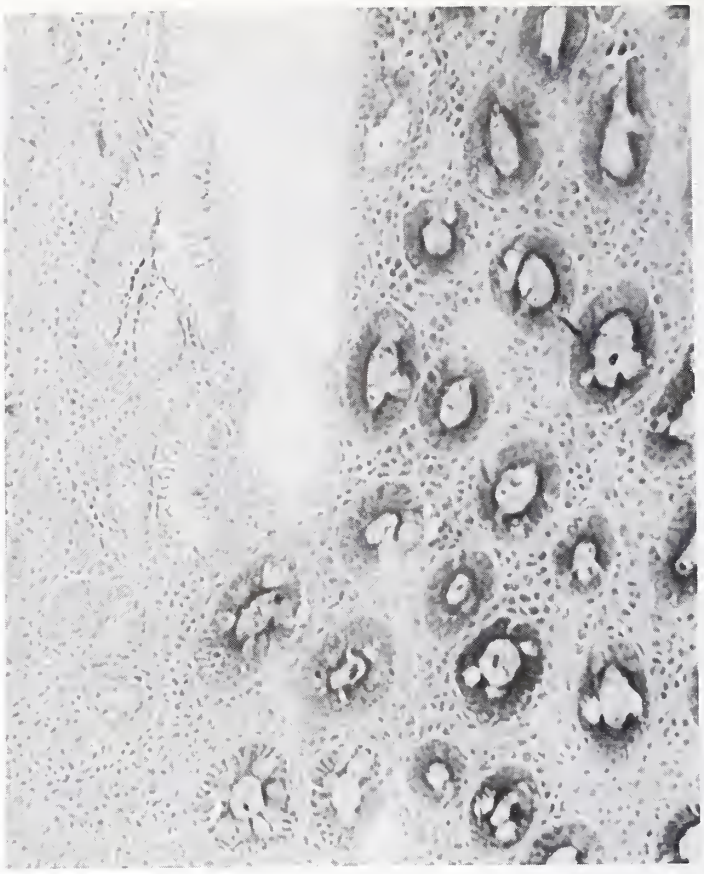

Fig 82

Fig. 82

AMINOPEPTIDASE IN METAPLASTIC MUCOSA

This cryostat section of gastric mucosa was stained for aminopeptidase using L-leucyl-β-naphthylamide hydrochloride as substrate (method of Nachlas et al.). The metaplastic glands show positive reaction, whereas the normal pyloric glands shown on the left are negative. $\times$ 120

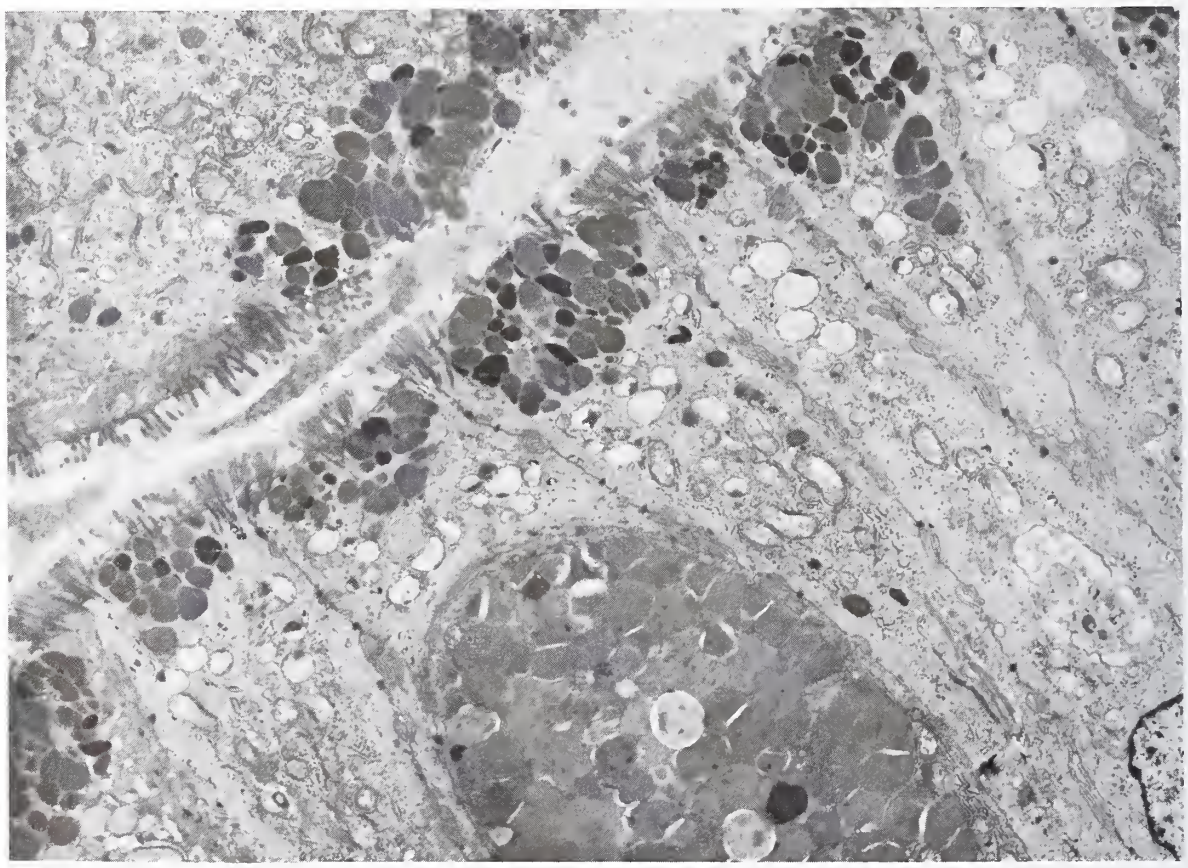

Fig 83

INCOMPLETE INTESTINAL METAPLASIA

An electron micrograph of the foveolar region of a gastric gland shows a goblet cell among the foveolar mucous cells. The apically located mucin granules in the latter are variable in size and density. Some granules resemble those present in goblet cells. The microvilli are more prominent and numerous than those of normal foveolar cells. $\times$ 5000.

References

Bertalanffy, F. D. Mitotic rates and renewal times of the digestive tract epithelia in the rat. Acta Anat. 40:130–148, 1960.

Glass, G. B. J. Introduction to Gastrointestinal Physiology. Englewood Cliffs, N. J.: Prentice-Hall, Inc., 1968.

Goldman, H., and Ming, S.-C. Fine structure of intestinal metaplasia and adenocarcinoma of the human stomach. Lab. Invest. 18:203–210, 1968.

———, and Ming, S.-C. Mucins in normal and neoplastic gastrointestinal epithelium. Histochemical distribution. Arch. Path. 85:580–586, 1968.

Grossman, M. I. The names of the parts of the stomach. Gastroenterology 34:1159–1162, 1958.

Hunt, T. E. Regeneration of the gastric mucosa in the rat. Anat. Rec. 131:193–211, 1958.

Konturek, S. J., and Urban, A. The correlation between gastric acid secretion and histology of fundic and antral gland area. Scan. J. Gastroent. 4:463–468, 1969.

Landboe-Christensen, E. Extent of the pylorus zone in the human stomach. Acta Path. Microbiol. Scand. Suppl. 54:671–692, 1944.

Magnus, H. A. A re-assessment of the gastric lesion in pernicious anemia. J. Clin. Path. 11:289–295, 1958.

Ming, S.-C., Goldman, H., and Freiman, D. G. Intestinal metaplasia and histogenesis of carcinoma in human stomach. Light and electron microscopic study. Cancer 20:1418–1429, 1967.

Morson, B. C. Intestinal metaplasia of the gastric mucosa. Gastroenterologia 86:181–190, 1956.

Nachlas, M. M., Crawford, D. T., and Seligman, A. M. The histochemical demonstration of leucine aminopeptidase. J. Histochem. Cytochem. 5:264–278, 1957.

Oi, M., Oshida, K., and Sugimura, S. The location of gastric ulcer. Gastroenterology 36:45–59, 1959.

Planteydt, H. T., Willighagen, R. G. J. Enzyme histochemistry of gastric carcinoma. J. Path. Bact. 90:393–398, 1965.

Rubin, W., Ross, L. L., Jeffries, G. H., and Sleisenger, M. H. Intestinal heterotopia. A fine structural study. Lab. Invest. 15:1024–1049, 1966.

Taylor, A. L. The epithelial heterotopias of the alimentary tract. J. Path. Bact. 30:415–449, 1927.

Teir, H., and Räsänen, T. A study of mitotic rate in renewal zones of non-diseased portions of gastric mucosa in cases of peptic ulcer and gastric cancer, with observations of differentiation and so-called "intestinization" of gastric mucosa. J. Nat. Cancer Inst. 27:949–971, 1961.

Winawer, S. J., and Lipkin, M. Cell proliferation kinetics in the gastrointestinal tract of man. IV. Cell renewal in the intestinalized gastric mucosa. J. Nat. Cancer Inst. 42:9–17, 1969.

GENERAL REMARKS ON BENIGN TUMORS

Benign tumors of the stomach are infrequent (Plachta and Speer; Ochsner and Janetos). They comprised 22.4 percent (Plachta and Speer) to 4.5 percent (McNeer and Pack) of all gastric tumors. Many small lesions may be easily missed, however, unless careful search is made. At the University of Maryland Hospital, there were 45 (11.0 percent) benign tumors or tumor-like lesions among a total of 395 gastric tumors. The reported incidence, predominant age group, location in the stomach, and size of these tumors are listed in Table VII and the reported numbers of various histologic types appear in Table VIII. Many of these tumors were small—about one-half were less than 2 cm. in diameter—and about one-half of these small tumors were asymptomatic. The frequency with which such asymptomatic small tumors are found depends largely upon the thoroughness of the search. Meissner found 44 leiomyomas in 23 stomachs of 50 consecutive autopsies (46 percent), and Feyrter found 120 myomas in the gastrointestinal tract of 84 of 1,500 unselected autopsies (5.6 percent), whereas the incidence in other reports was 0.18 percent (Table VII).

Polyp is the most common benign tumor in the stomach (Table VIII). If diagnosis is based on roentgenologic or clinical studies, the incidence of polyps will be much higher, as reported by Eklöf who found 176 polyps among 234 cases of benign tumors (75 percent). However, with the obvious exception of peptic ulcer and atrophic gastritis, virtually all other gastric lesions may assume a polypoid configuration (Ottoman and Woodruff). Thus, Huppler and associates noted that of 300 polyps diagnosed clinically, 20 percent actually were other benign lesions and another 20 percent were found to be malignant lesions at the time of surgery. Only half of the small polypoid tumors studied by McNeer and Joly were adenomatous polyps.

Table VII

BENIGN TUMORS OF THE STOMACH

PERCENTAGES OF

THE INCIDENCE, LOCATION, AND SIZE OF TUMORS AND AGE OF PATIENTS

	Incidence			Location		Size		Age
	Autopsies	All Gastric Tumors[T]	Benign Gastric Tumors[T]	Antrum	Body	<2cm.	Max. cm.	
Polyp	0.43[P]	3.1	44.7	51[R]	37[R]	85[M]	11[Mc]	51-80 (80%)
Leiomyoma	0.18-46.0[Me]	2.0	29.4	39	34	9	40	41-60 (48%)
Heterotopic Pancreatic Tissues	0.07[Mc]	0.4	6.4	86	12	76	5	31-50 (71%)
Vascular Tissue Tumor	0.014	0.2	3.3	49	43	16	20	31-60 (63%)
Nervous Tissue Tumor*	0.016	0.16	2.2	27	51	5	32	41-60 (61%)
Lipoma	0.029	0.14	2.0	69	28	25	20	51-70 (53%)

*The true nature of these "nervous tissue tumors" is questionable; many were probably leiomyomas (further discussion in text, p. 248).

Reference Sources
M — Ming & Goldman
Mc — McNeer & Pack
Me — Meissner
P — Plachta & Speer
R — Rosato & Noto
T — See Table VI
Others — Palmer

Leiomyoma is also common and in some reports the most common benign gastric tumor (Stout; Beard et al.). It is probably the most frequently reported tumor (Palmer). The neurogenic tumors are rare (Table VIII). Palmer collected 263 cases reported up to 1950, and concluded that as histologic criteria became better standardized, the benign neurogenic tumors would be the most common of the benign nonepithelial gastric tumors. Stout was of the opinion, on the other hand, that many of the reported neurilemomas of the stomach were erroneously diagnosed and represented leiomyomas. This view was confirmed by Nordenstam and Nordström who found that 5 of 8 tumors originally diagnosed as neurogenic were in fact leiomyomas. At the University of Maryland Hospital, not one neurogenic tumor has been found in the stomach.

Clinical manifestations of benign gastric tumors depend upon the size and location of the lesion and whether overlying ulceration has occurred. Ulcerated tumors may cause symptoms and signs similar to those of peptic ulcer, particularly as to the character of the pain, and their ability to bleed massively. Most of the lesions occur in the antrum and many develop at the pylorus. Pedunculated as well as the sessile tumors at these locations may produce intermittent or progressive obstruction of the pylorus. In most cases, the round, smooth, but sharply delineated contour, the acute angle formed by the edge of the lesion and the surrounding mucosa, the single ulcer at the dome of the tumor, free mobility of the polypoid lesion, and its small size help to distinguish benign from malignant tumor. Exception to these generalizations has been encountered so frequently, however, that final diagnosis and its consequent treatment must be based on the histologic characterization of each lesion.

Table VIII

BENIGN TUMORS OF THE STOMACH

RELATIVE FREQUENCY OF HISTOLOGIC DIAGNOSES

	Beard et al	Marshall	McNeer & Pack	Ochsner & Janetos	Pena & Braasch	Plachta & Speer	Stout	Total	Percent
Polyp	10	37	51	38	19	65	32	252	41.0
Leiomyoma	25	28	9	26	34	69	39	230	37.0
Inflammatory Polyp			4	2		9	14	29	4.7
Heterotopic Tissue	1	12	1	3	2		6	25	4.1
Lipoma	1	2	3	5	3	6	1	21	3.4
Neurogenic Tumor	3		3	2	2	6	3	19	3.0
Eosinophilic Granuloma			3			4	5	12	1.9
Fibroma	1			1		7		9	1.5
Tumor of Developmental Origin	1		1			3		5	
Hemangiopericytoma							4	4	
Glomus Tumor			1				2	3	
Hemangioma				1		2		3	
Lymphangioma				1			2	3	
Granular Cell Tumor							1	1	
Total	42	79	76	79	60	171	109	616	

Note. Carcinoids, unspecified tumors, and bezoars are excluded. The neurogenic tumors reported in these series included the following diagnoses: 7 neurofibromas, 6 neuromas, 2 neurilemomas, 1 ganglioneuroma, 1 paraganglioma, and 2 unspecified.

References

Beard, R. J., Lee, E. C., Haysom, A. H., and Melcher, D. H. Non-carcinomatous tumours of the stomach. Brit. J. Surg. 55:535–538, 1968.

Eklöf, O. Benign tumours of the stomach and duodenum. A clinical and roentgenographic study with special reference to adenomatous polyps and the relation to malignancy. Acta Chir. Scand. Suppl. 291:1–57, 1962.

Feyrter, F. Über die Myome des menschlichen Magen-Darmschlauches. Virchow Arch. Path. Anat. 316:689–707, 1949.

Huppler, E. G., Prietley, J. T., Morlock, C. G., and Gage, R. P. Diagnosis and results of treatment in gastric polyps. Surg. Gynec. Obstet. 110:309–313, 1960.

Marshall, S. F. Symposium on surgery of digestive tract; gastric tumors other than carcinoma, report of unusual cases. Surg. Clin. N. Amer. 35:693–702, 1955.

McNeer, G., and Joly, D. J. The Problem Posed by the Small Polypoid Gastric Tumor, p. 238. In: McNeer, G., and Pack, G. T. Neoplasms of the Stomach. Philadelphia: J. B. Lippincott, 1967.

_____, and Pack, G. T. Benign Tumors of the Stomach. General Considerations, p. 518. In: Neoplasms of the Stomach. Philadelphia: J. B. Lippincott, 1967.

Meissner, W. A. Leiomyoma of the stomach. Arch. Path. 38:207–209, 1944.

Ming, S.-C., and Goldman, H. Gastric polyps. A histogenetic classification and its relation to carcinoma. Cancer 18:721–726, 1965.

Nordenstam, H., and Nordström, S. Benign non-epithelial tumours of the stomach and small intestine. Histologic typing and malignant degeneration. Acta Chir. Scand. 125:139–143, 1963.

Ochsner, S. F., and Janetos, G. P. Benign tumors of the stomach. J.A.M.A. 191:881–887, 1965.

Ottoman, R. E., and Woodruff, J. H., Jr. Polypoid diseases of the stomach. Radiology 64:34–44, 1955.

Palmer, E. D. Benign intramural tumors of the stomach: a review with special reference to gross pathology. Medicine 30:81–181, 1951.

Pena, O., and Braasch, J. W. Benign tumors of the stomach. Lahey Clin. Found. Bull. 17:89–95, 1968.

Plachta, A., and Speer, F. D. Gastric polyps and their relationship to carcinoma of the stomach; review of literature and report of 65 cases. Amer. J. Gastroent. 28:160–175, 1957.

Rosato, F. E., and Noto, J. A. Gastric polyps. Amer. J. Surg. 111:647–650, 1966.

Stout, A. P. Tumors of the Stomach. Fascicle 21, Atlas of Tumor Pathology. Washington: Armed Forces Institute of Pathology, 1953.

INFLAMMATORY LESIONS SIMULATING TUMOR

Inflammatory lesions of the stomach may simulate neoplastic lesions because of their nodularity or localized thickening of the gastric wall. The ulcerative lesions with raised surrounding mucosa may be mistaken for carcinoma. Most inflammatory diseases primarily involve only the gastric mucosa and adjacent submucosa. Occasionally, the inflammatory infiltrates extend into the muscularis externa causing impairment of motility and further simulate malignant tumors.

SPECIFIC INFECTIONS

Syphilis was considered a prominent specific infection in the older literature; its gummatous or nonspecific inflammation caused ulcer, local or diffuse thickening and stiffening of the gastric wall, and rarely a gross pattern of linitis plastica (O'Leary). *T. pallidum* was rarely found in the lesion and diagnosis was made primarily on clinical impressions. It is highly probable that many of those lesions now would not be considered specific infections. This author has not seen a verified case.

Tuberculosis of the stomach is also rare. A recently reported case was a tumor-like lesion involving the greater curvature of the stomach in a 68-year-old woman (Tuchel et al.). With the disappearance of such specific infections simulating tumor, nonspecific gastritis of unknown etiology has gained popularity.

References

Browne, D. C., McHardy, G., and Wilen, C. J. W. Gastric mucosal changes of tuberculosis. Amer. J. Dig. Dis. 9:407–411, 1942.

O'Leary, P. A. Gastric syphilis; data accumulated from eighty-nine cases. Amer. J. Surg. 11:286–293, 1931.

Tuchel, V., Macarie, R., Lauch, E., Fesiuc, P., and Zaharia, M. Gastric tuberculosis simulating a complicated tumor-like form. Digestion 2:237–241, 1969.

EOSINOPHILIC GASTRITIS (EOSINOPHILIC GRANULOMA)

Eosinophilic leukocytes are commonly seen in the lamina propria of the gastric mucosa. They

are scattered and inconspicuous in the normal stomach, but are frequent and easily recognized in many inflammatory lesions. Their mere presence, therefore, does not necessarily imply a specific lesion. In eosinophilic gastritis, the eosinophils are numerous; often the infiltration is massive. Ureles and associates divided the condition into two groups: (1) diffuse eosinophilic gastroenteritis, with intense eosinophilic infiltration throughout the thickness of gastric and intestinal wall and an ill-defined boundary of the involved area; and (2) the circumscribed eosinophil-infiltrated granuloma with a sharply delineated, often polypoid lesion involving mainly the submucosa. The latter lesions had been described earlier by Vaněk, and were subsequently evaluated by Helwig and Ranier under the name of inflammatory fibroid polyp. The clinical and pathologic differences between these two groups are distinct, and some authors considered them to be separate entities (Salm; Swarts and Young). Because of the common denominator of eosinophilic infiltration, others considered them variations of one disease or at least related (Salmon and Paulley; Ureles et al.). From pathologic points of view, these lesions may be appropriately segregated into two groups: eosinophilic gastritis and inflammatory fibroid polyp.

In **eosinophilic gastritis** there is an intense infiltration of eosinophils, often in sheets or masses, and a minor infiltration of plasma cells and lymphocytes (fig. 84; pl. III-A). The histiocytes are inconspicuous and fibrosis is minimal. The muscularis externa and submucosa are heavily infiltrated, causing a grossly thickened and deformed gastric wall. The mucosa is either intact

Fig 84

EOSINOPHILIC GASTRITIS

(Figure 84 and Plate III-A from same case)

This photomicrograph shows massive infiltration of eosinophilic leukocytes in the submucosa. The lymphatics were dilated. Some muscle cells of the muscularis externa are shown at the lower corner. × 140. (Courtesy of Dr. H. T. Enterline, Philadelphia, Pa.)

or ulcerated and the serosa may be affected. The infiltrates tend to aggregate near the blood vessels, and in some cases angiitis may be present. Focal areas of necrosis have also been found. In 25 cases reviewed by Ureles and associates, the stomach was involved in each, usually in the pyloric antrum or pylorus, but the entire organ was rarely involved. In 12 of these cases, similar lesions were also found in the intestines, particularly the duodenum and jejunum. Salmon and Paulley reviewed reports of 136 lesions in 122 patients; 32 were polypoid and 104 were infiltrative lesions. The stomach was involved in 17 of the former and 36 of the latter types. Clinically, the patients were middle-aged, with a male predominance. Gastric symptomatology was related principally to pyloric obstruction and rarely to massive bleeding (Rosenthal). History of allergy or asthma and eosinophilia in the peripheral blood were common in these patients. In the related condition of **allergic granulomatosis,** minute lesions may be found in the gastrointestinal tract (Churg and Strauss). Abell and associates recently reported a case of a 53-year-old man with a long history of asthma, in whom the lesion formed a large nodular mass in the distal portion of the stomach. The author has seen a similar case through the courtesy of Dr. Robert B. Wright, pathologist at the South Baltimore General Hospital. The patient was a 56-year-old man with a long history of asthma. The stomach showed a diffuse thickening of linitis plastica type (fig. 85).

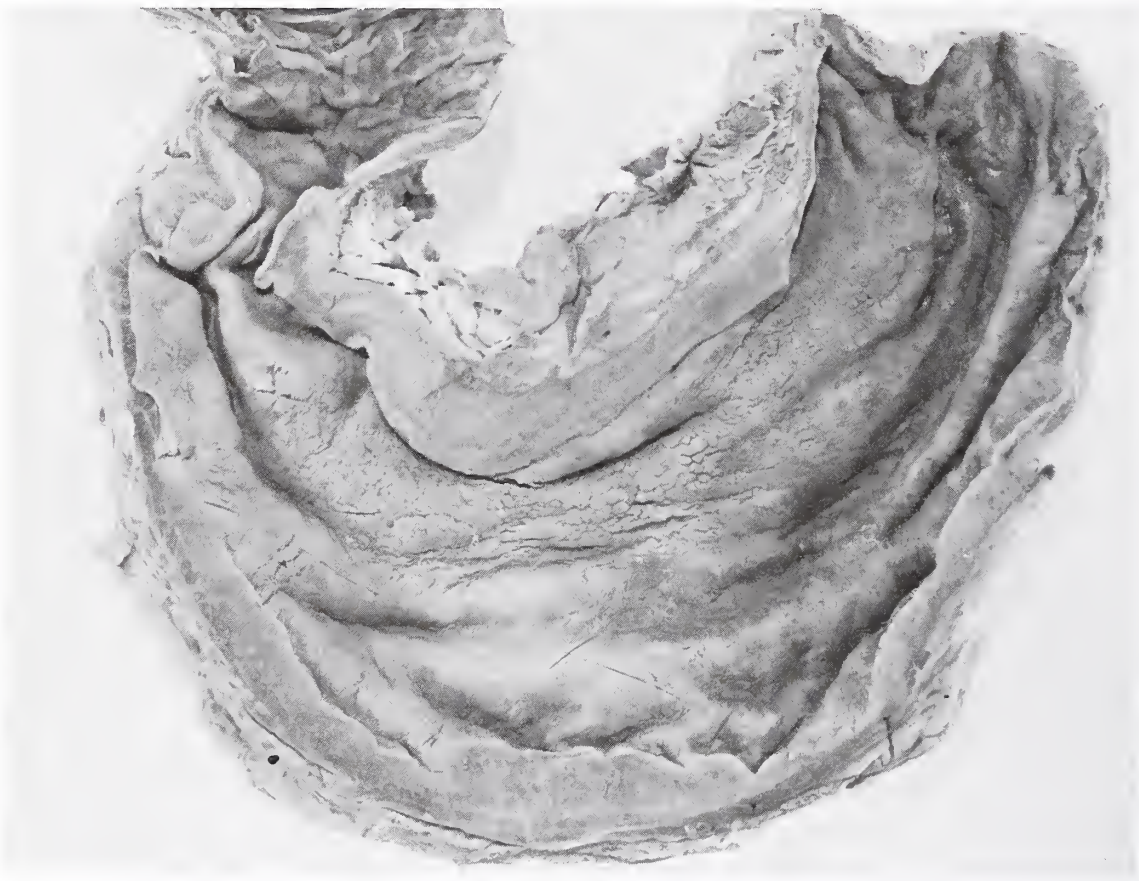

Fig. 85

ALLERGIC GRANULOMATOSIS

(Figures 85 and 86 from same case)

This stomach, from a 56-year-old man with a long history of asthma, is diffusely thickened in the form of linitis plastica. The mucosa is flat, but intact. Inflammatory fibrous tissue penetrates through the whole thickness of the gastric wall into the omentum. (Courtesy of Dr. R. B. Wright, Baltimore, Md.)

Necrotizing granulomas and numerous eosinophils were present in the stomach (fig. 86). Angiitis, mainly venous, was present in a few foci. Similar lesions were also found in the lung, spleen, and peritoneum.

The **inflammatory fibroid polyp** is oval, with a short pedicle, and a smooth surface which is often ulcerated (fig. 87). Intact mucosa is present near its base. The polyp is composed of loose, spindly fibroblasts in which eosinophils, plasma cells, lymphocytes, and histiocytes of varying numbers are present (fig. 88). True granulomas are rare. Many thin-walled blood vessels are scattered throughout the polyp, often surrounded by fibroblasts with long cytoplasmic processes arranged in an onionskin pattern (fig. 89). Reticulum stain reveals rich reticulum fibers which include the perivascular area (fig. 90). Occasional polyps have a dense collagenous stroma. In such cases, plasma cells rather than eosinophils predominate. These polyps occur chiefly in the pyloric antrum, and the pyloric glands are present often in increased numbers at the base of the lesion (fig. 87). The lesion is primarily submucosal, although the deep layer of mucosa and the adjacent muscularis externa may show minor involvement.

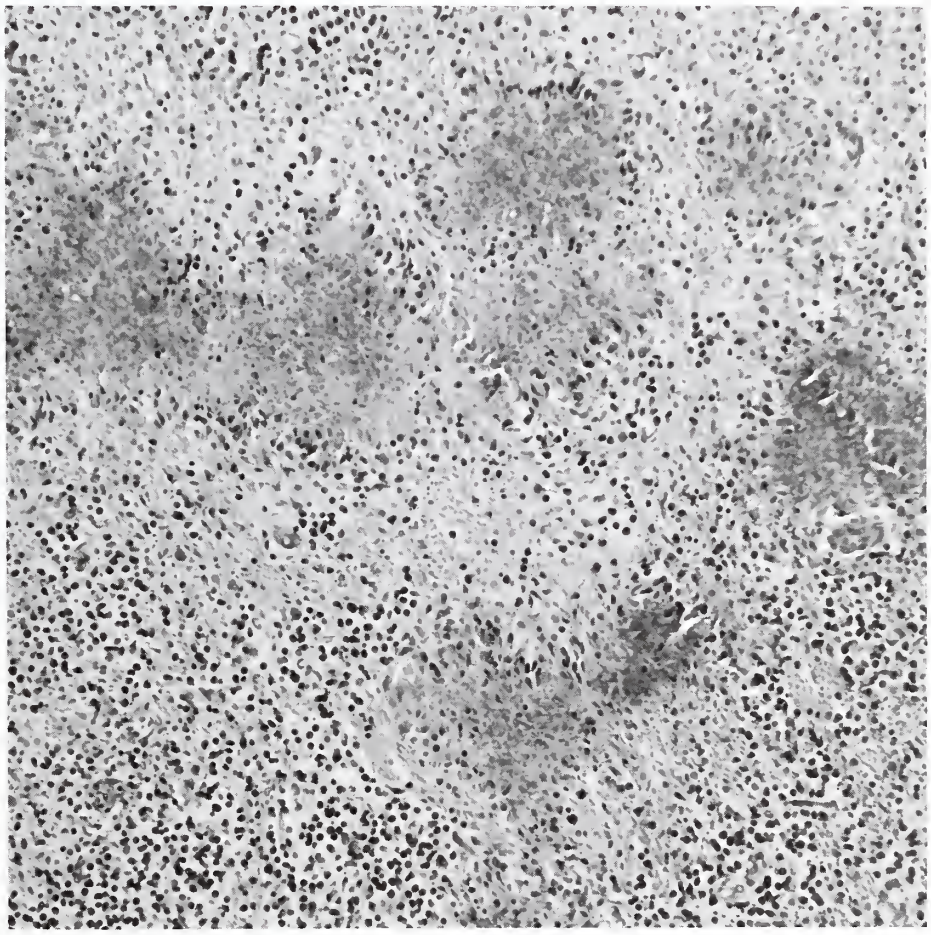

Fig. 86

ALLERGIC GRANULOMATOSIS

(Figures 85 and 86 from same case)

This photomicrograph of the lesion found in the same stomach shown in figure 85 reveals diffuse chronic inflammation in loose fibrous tissue with multiple foci of granulomatous reaction surrounding a zone of coagulative necrosis. The inflammatory cells consist of numerous eosinophils, many plasma cells, and histiocytes. × 134. (Courtesy of Dr. R. B. Wright, Baltimore, Md.)

Fig 87

INFLAMMATORY FIBROID POLYP

This photomicrograph of an inflammatory fibroid polyp from the pylorus illustrates the general configuration of the lesion. The mucosa is ulcerated at the top and on one side. The pedicle is short and, in this plane of section, contains hyperplastic pyloric glands. Small lymphocytic aggregates are present, but the nature of cellular components cannot be seen at this magnification. × 7.4 (Courtesy of The Massachusetts General Hospital, Boston, Mass.)

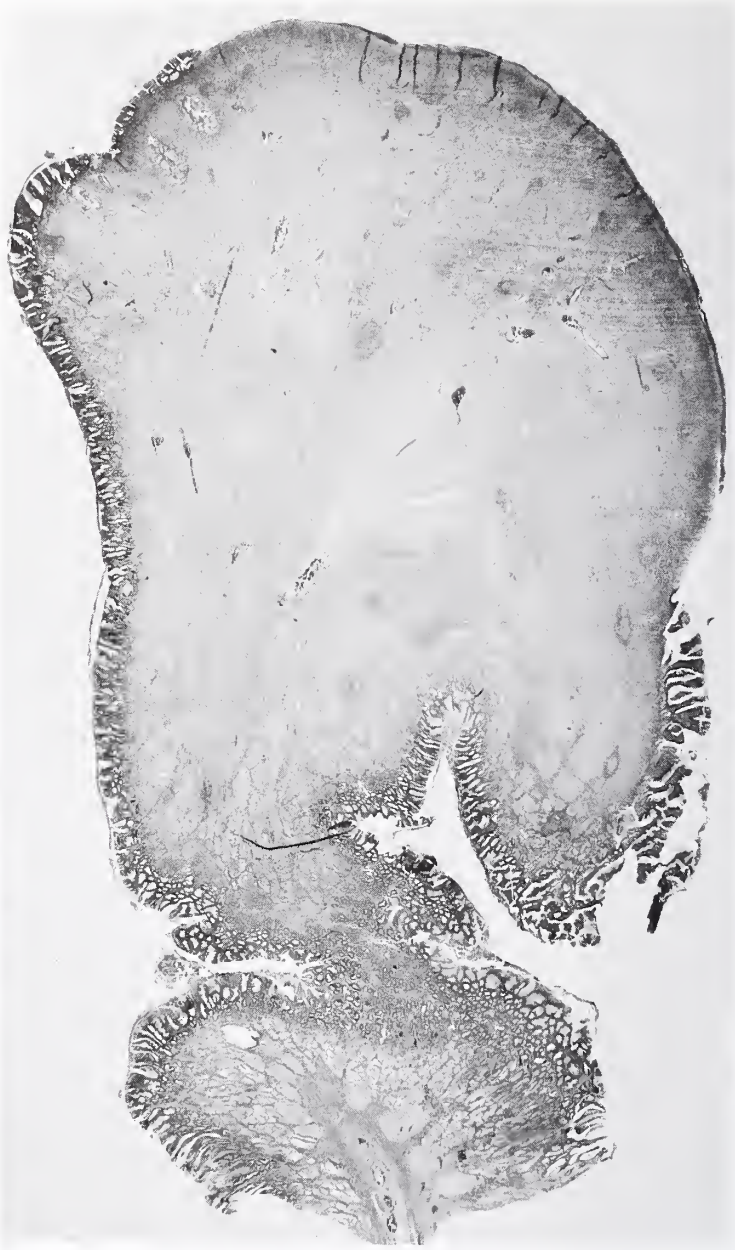

Fig 87

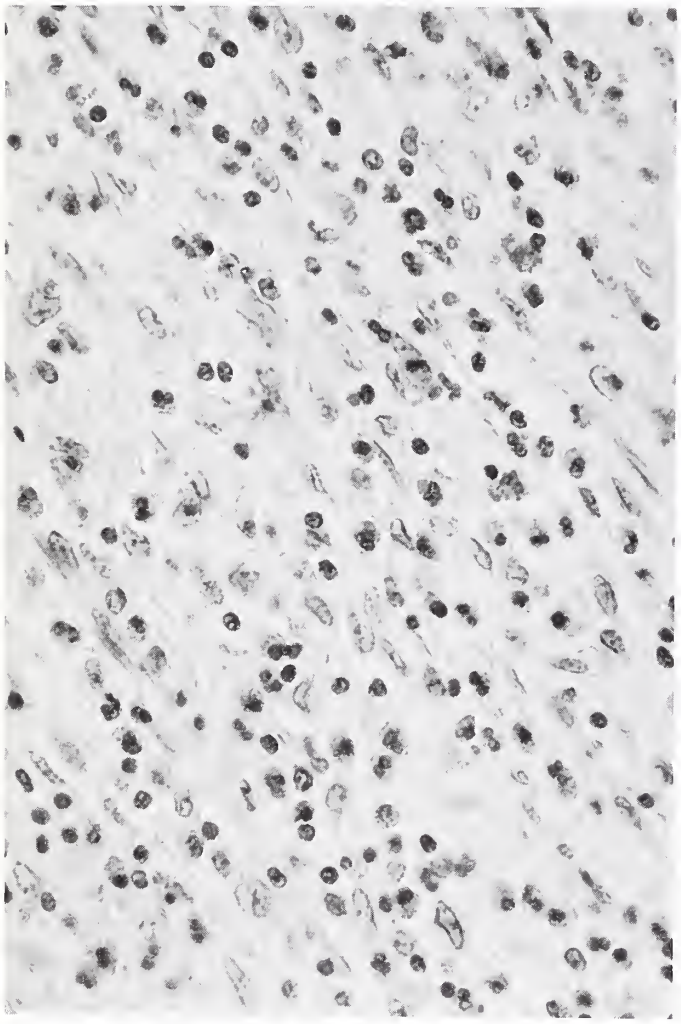

Fig 88

Fig 88

INFLAMMATORY FIBROID POLYP

This photomicrograph of an inflammatory polyp shows loose stroma with elongated fibroblasts and inflammatory cells consisting of lymphocytes, plasma cells, histiocytes, and numerous eosinophils. × 415.

INFLAMMATORY FIBROID POLYP

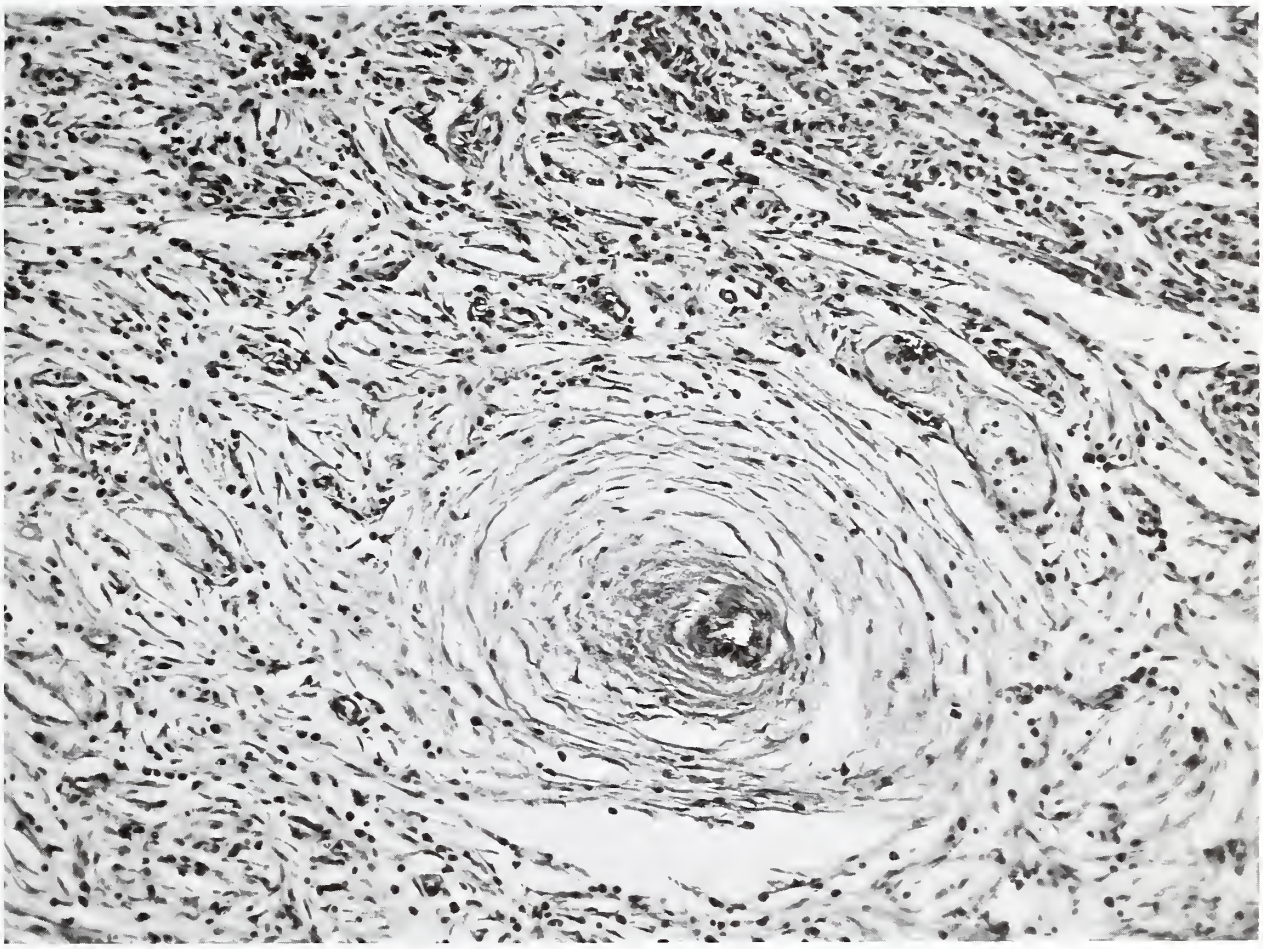

Fig 89

(Figures 89 and 90 from same case)

This photomicrograph shows the perivascular arrangement of elongated fibroblastic cells in an inflammatory fibroid polyp. × 140.

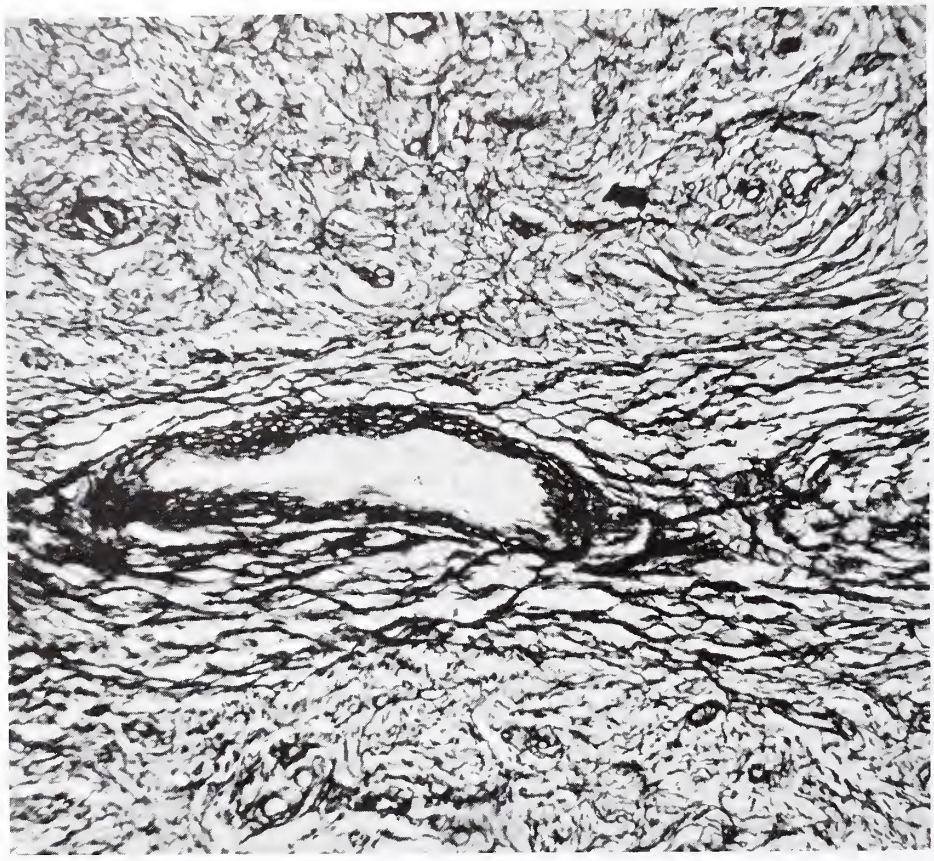

Fig 90

INFLAMMATORY FIBROID POLYP

(Figures 89 and 90 from same case)

This photomicrograph of the same polyp seen in figure 89 shows the perivascular reticulum fibers. Reticulum stain. × 73

Salm found 58 cases in the literature in 1965, with a male to female ratio of 3 to 2. The chief clinical symptom was abdominal pain. Gastric bleeding and anemia were present in some cases. Eosinophilia of the peripheral blood and a history of allergy were generally lacking. The pattern of rich reticulum fibers with perivascular arrangement resembles that seen in hemangiopericytoma (fig. 90). Some of the cases reported to be hemangiopericytomas might be, in fact, inflammatory fibroid polyps (Helwig and Ranier). Sometimes the foci of whorled arrangement of loose fibroblasts were seen without a centrally located vessel; this indicated the neurogenic origin of the lesion to some pathologists (Goldman and Friedman). While the nerve plexus might be involved in the inflammatory process, definite evidence for nerve tissue origin of the polyp is lacking. Pathologic characteristics strongly favor the inflammatory nature of these lesions and their chronological aspects appear older than the changes seen in eosinophilic gastritis. Intermediate lesions between the two have been observed and serve to establish the relationship between these two conditions. Since eosinophils may be present in other gastric lesions, careful evaluation of their significance is necessary. Burkhart and Wilkinson reported two cases of an eosinophilic lesion of the stomach. As it turned out, one patient, a 27-year-old Negro woman, had a scirrhous carcinoma in the stomach which was diagnosed two and one-half years after the original report. Tumor cells were found in the previous specimen when the case was reviewed.

References

Abell, M. R., Limond, R. V., Blamey, W. E., and Martel, W. Allergic granulomatosis with massive gastric involvement. New Eng J Med 282 665–668, 1970.

Burkhart, C. R., and Wilkinson, R. H., Jr. Inflammatory pseudotumors of the stomach. Follow-up report and correction. Cancer 21 1052–1054, 1968.

Churg, J., and Strauss, L. Allergic granulomatosis, allergic angiitis, and periarteritis nodosa. Amer J Path 27 277–301, 1951.

Goldman, R. L., and Friedman, N. B. Neurogenic nature of so-called inflammatory fibroid polyps of the stomach. Cancer 20 134–143, 1967.

Helwig, E. B., and Ranier, A. Inflammatory fibroid polyps of the stomach. Surg Gynec Obstet 96 355–367, 1953.

Rosenthal, I. I. Eosinophilic granuloma of the stomach. J Mount Sinai Hosp N Y 30:519–522, 1963.

Salm, R. Gastric fibroma with eosinophilic infiltration. Gut 6 85–91, 1965.

Salmon, P. R., and Paulley, J. W. Eosinophilic granuloma of the gastro-intestinal tract. Gut 8 8–14, 1967.

Swarts, J. M., and Young, J. M. Primary infiltrative eosinophilic gastritis, enteritis and peritonitis. Clinical and pathological manifestations of hypersensitivity. Gastroenterology 28 431–452, 1955.

Ureles, A. L., Alschibaja, T., Lodico, D., and Stabins, S. J. Idiopathic eosinophilic infiltration of the gastrointestinal tract, diffuse and circumscribed, a proposed classification and review of the literature, with two additional cases. Amer J Med 30 899–909, 1961.

Vaněk, J. Gastric submucosal granuloma with eosinophilic infiltration. Amer J Path 25:397–411, 1949.

GRANULOMATOUS GASTRITIS

Nonspecific granulomas in the stomach composed of epithelioid cells and giant cells without central necrosis (fig. 91) have often been reported as cases of gastric sarcoid. Sirak reviewed 12 cases in the literature and reported a case of disseminated sarcoidosis in a 27-year-old man in whom the stomach was diffusely thickened, simulating linitis plastica. In four of

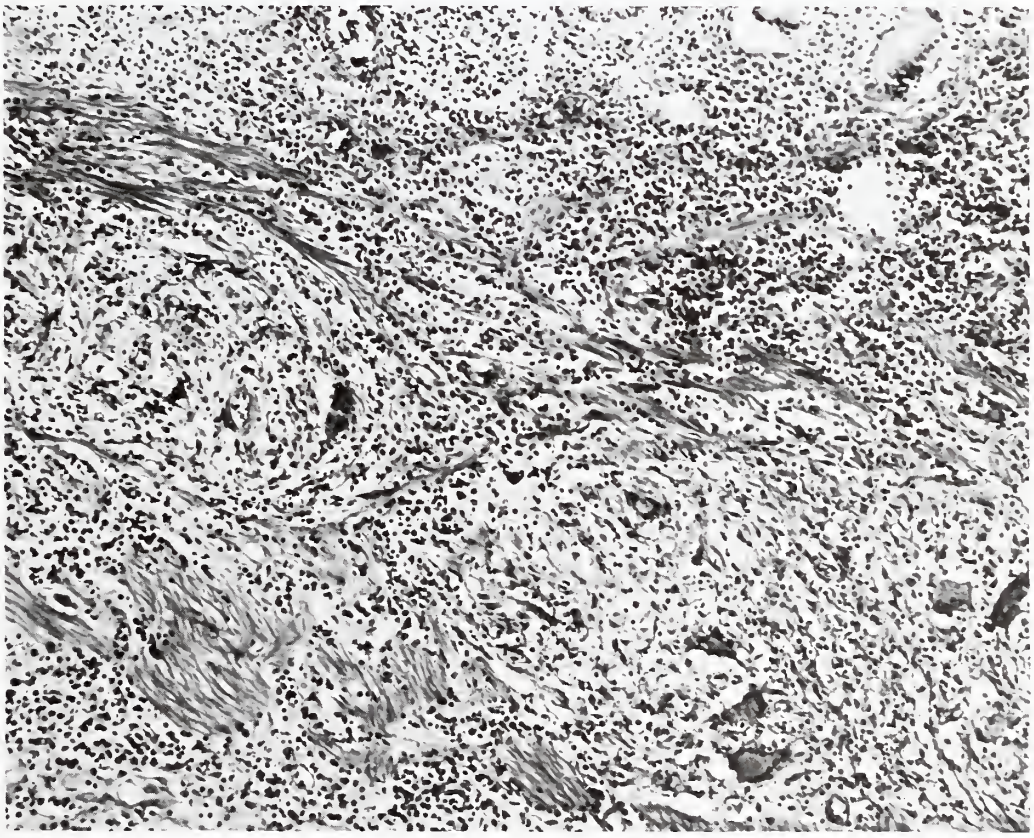

Fig 91

SARCOIDOSIS

This photomicrograph reveals rather poorly defined sarcoid granulomas and chronic inflammation in an ulcerative lesion of the pyloric antrum. The patient was a 43-year-old woman with sarcoidosis involving the skin and lymph nodes. × 105

these 13 cases, granulomas were found only in the stomach, and in two others there was intestinal involvement suggestive of Crohn's disease. In one case there was a carcinoma in the same stomach (Bauer). Longcope and Freiman noted the rarity of gastric involvement in generalized sarcoidosis and Engle pointed out the nonspecificity of asteroid and Schaumann bodies which had once been considered characteristic of sarcoid granuloma. Under these circumstances, the relationship between gastric granulomas and other granulomatous diseases appeared uncertain.

This problem was studied by Fahimi and associates who, in 1963, reviewed the reported cases of granulomatous diseases involving the stomach and divided them into three groups based primarily on the extent of the lesion: 17 cases of disseminated sarcoidosis; 6 cases of Crohn's disease; and 32 cases of isolated granulomatous gastritis. The granulomas were alike in all these cases; the clinical manifestations of the gastric diseases consisted mainly of upper abdominal pain, vomiting, and weight loss. Pathologically, the diseases involved principally the pyloric antrum with thickening of the gastric wall and narrowing of the lumen. Superficial erosion or ulcer occurred less frequently. Granulomas were present in the regional lymph nodes in many cases. Differentiation among these three groups rested not on the pathologic characteristics but on the demonstration of granulomatous lesions in other organs. Gastric involvement had not been reported as the first manifestation of disseminated sarcoidosis, and, conversely, long follow-ups of isolated granulomatous gastritis had revealed no involvement of other organs. Most cases of Crohn's disease deteriorated further after gastrectomy (Laing et al.). Fahimi and associates also noted an age difference between them: almost all cases of Crohn's disease and two-thirds of sarcoidosis occurred in patients under 39 years of age, whereas 81 percent of the patients with isolated granulomas were over 40 years of age. Roentgenologically, the gastric lesions might simulate malignant tumor. The presence of multinucleated giant cells in gastric washings is helpful in the diagnosis of granulomatous disease of the stomach (Goldgraber et al.). But, as pointed out by Bennington and associates, such giant cells may be difficult to differentiate from malignant cells.

References

Bauer, J. T. Granuloma (sarcoid) of stomach (report of case associated with carcinoma.) Bull. Ayer Clin. Lab. 4: 35–43, 1951.

Bennington, J. L., Porus, R., and Ferguson, B. Cytology of gastric sarcoid. Report of a case. Acta Cytol. 12: 30–36, 1968.

Engle, R. L., Jr. Sarcoid and sarcoid-like granulomas. A study of twenty-seven post-mortem examinations. Amer. J. Path. 29:53–69, 1953.

Fahimi, H. D., Deren, J. J., Gottlieb, L. S., and Zamchek, N. Isolated granulomatous gastritis. Its relationship to disseminated sarcoidosis and regional enteritis. Gastroenterology 45:161–175, 1963.

Goldgraber, M. B., Kirsner, J. B., and Raskin, H. F. Nonspecific granulomatous disease of the stomach. A clinical pathological study. Arch. Int. Med. 102.10–24, 1958.

Laing, R. R., Dunn, G. D., and Klotz, A. P. Crohn's disease of the stomach. Gastroint. Endosc. 16:168–172, 1970.

Longcope, W. T., and Freiman, D. G. A study of sarcoidosis based on a combined investigation of 160 cases including 30 autopsies from the Johns Hopkins Hospital and Massachusetts General Hospital. Medicine 31:1–132, 1952.

Sirak, H. D. Boeck's sarcoid of the stomach simulating linitus plastica. Report of a case and comparison with twelve recorded cases. Arch. Surg. 69:769–784, 1954.

BENIGN LYMPHOID HYPERPLASIA (PSEUDOLYMPHOMA)

At the base and margins of a peptic gastric ulcer, prominent lymphocytic reaction may be seen (fig. 92). The areas so involved are usually focal. Occasionally, the lymphoid tissue is massive, forming nodular elevations around the ulcer or, less frequently, a mass or plaque without gross ulceration. These lesions may be easily mistaken for malignant lymphoma which may account for the high rate of cure among reported cases of lymph-

Fig. 92

PEPTIC ULCER WITH LYMPHOCYTIC INFILTRATION

This is the base of a 2 cm. peptic ulcer of the antrum in a 42-year-old man. It shows a massive lymphocytic reaction and many small blood vessels. Neutrophils are present in the area of necrosis. In other areas, not shown, there were lymphoid nodules with germinal centers in some foci and marked fibrosis with scanty inflammatory cells in others. × 105.

omas of the stomach. Berry and Mathews reevaluated 12 cases diagnosed as gastric lymphosarcoma; six were reclassified as pseudolymphomas. Valdés-Dapena and associates analyzed 20 cases of gastric lymphoma followed for three years or more; features suggestive of pseudolymphoma were found in 4 of 10 living patients and in 1 of 10 patients who died of recurrent disease. The characteristics of pseudolymphoma have been described by Faris and Saltzstein, and by Jacobs. Grossly, the lesion is single and usually ulcerated. Some ulcers may attain a large size, up to 14 cm. (Berry and Mathews). In some cases the ulcer is sharply delineated with overhanging margins.

The tissue surrounding the ulcer is raised and often nodular. Some lesions are manifest as a nodular mass or enlarged rugae. Multiple nodules are not found. True lymphomas, on the other hand, are often multiple; the small tumor nodules are usually covered by an attenuated mucosa, whereas the large ones may be ulcerated with thick rolled-up borders. Further details of lymphoma are described on pages 231 – 238.

Microscopically, the most prominent feature is a nodular arrangement of lymphoid tissue, often with germinal centers (fig. 93). Fibrosis is usually prominent at the periphery and often extends deeply into the muscularis. In addition, mature lymphocytes, neutrophils, and eosinophils are usually present near the mucosal surface, and plasma cells and histiocytes are easily found in the areas between the nodules (fig. 94). Regional lymph nodes are either normal or hyperplastic. The follicular pattern of the lesion should be distinguished from that of a follicular lymphoma, which occurs infrequently in the stomach (Kay; Naqvi et al.). The cells in the follicles of the latter are homogeneous and immature. The other types of lymphoma have a homogeneous cell population which often extends deeply into the muscularis and show scanty or no evidence of inflammatory components such as plasma cells, histiocytes, and fibrous tissue. On occasion, differentiation between pseudolymphoma and lymphoma may be difficult. In any

Fig. 93

BENIGN LYMPHOID HYPERPLASIA
(PSEUDOLYMPHOMA)

(Figures 93 and 94 from same case)

This photomicrograph of an ulcerated raised lesion from the stomach in a 32-year-old woman shows a massive lymphocytic infiltration forming a nodular pattern. Germinal centers are present in many nodules. The mucosa is focally eroded and markedly atrophic. Fibrosis is present in the surrounding area. The regional lymph nodes were normal. The patient was well six years later. × 12.

case, it is wise to evaluate the complete picture, particularly the histologic appearance of lymph nodes, and not rely solely on the microscopic characteristics of the gastric lesion.

Fig. 94

BENIGN LYMPHOID HYPERPLASIA (PSEUDOLYMPHOMA)

(Figures 93 and 94 from same case)

These cells were present in the area between the nodules shown in figure 93. Mature lymphocytes predominate. Plasma cells and histiocytes are also present; one of the latter is binucleated. × 690.

References

Berry, G. R., and Mathews, W. H. Gastric lymphosarcoma and pseudolymphoma. Reappraisal of 12 cases of gastric lymphosarcoma. Canad. Med. Ass. J. 96:1312–1316, 1967.

Faris, T. D., and Saltzstein, S. L. Gastric lymphoid hyperplasia. A lesion confused with lymphosarcoma. Cancer 17:207–212, 1964.

Jacobs, D. S. Primary gastric malignant lymphoma and pseudolymphoma. Amer. J. Clin. Path. 40:379–394, 1963.

Johnson, A. G., and Sowerbutts, J. G. Pseudolymphoma of the stomach. Brit. J. Surg. 55:81–83, 1968.

Kay, S. Lymphoid tumors of the stomach. Surg. Gynec. Obstet. 118:1059–1066, 1964.

Naqvi, M. S., Burrows, L., and Kark, A. E. Lymphoma of the gastrointestinal tract: Prognostic guides based on 162 cases. Ann. Surg. 170:221–231, 1969.

Valdés-Dapena, A., Affolter, H., and Vilardell, F. The gradient of malignancy in lymphoid lesions of the stomach. Gastroenterology 50:382–389, 1966.

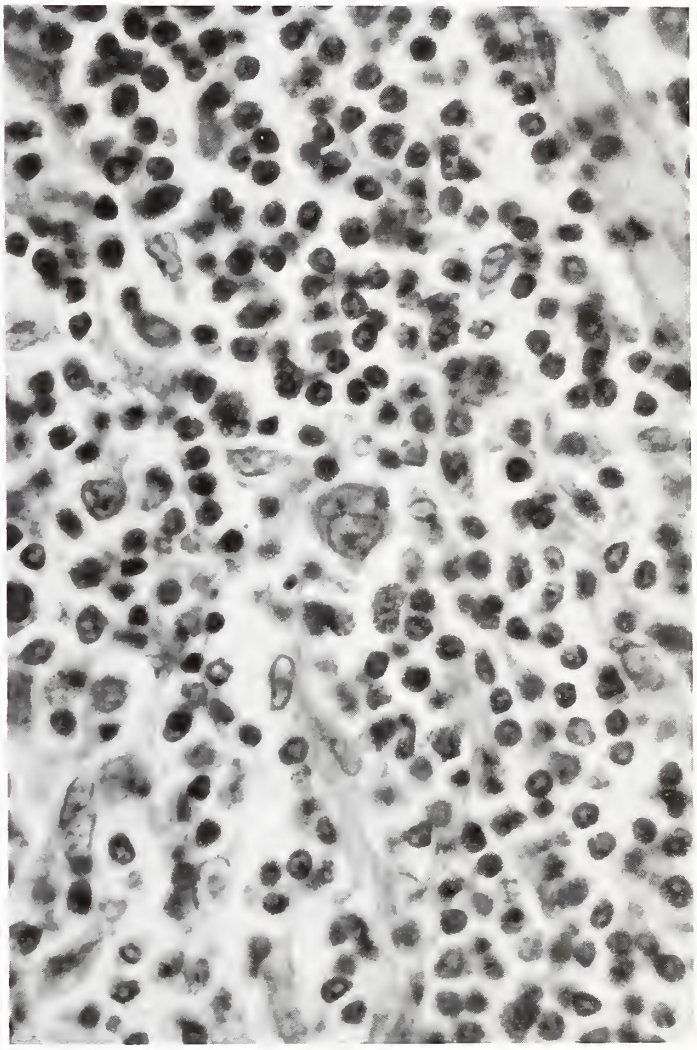

Fig. 94

TUMORS AND TUMOR-LIKE LESIONS OF ENTODERMAL ORIGIN

HYPERPLASTIC GASTROPATHY

The term "chronic hyperplastic gastritis" was popularized by Schindler and has been applied to many conditions showing thickening and prominent rugosity of the gastric mucosa. It is an unfortunate term because of the lack of specific histologic features and the nonspecificity of its gross appearances. It is well recognized that prominent rugosity of the gastric mucosa can be caused not only by inflammatory diseases, but also by neoplasms, including carcinoma, lymphoma, and metastatic tumors. Furthermore, increased rugosity may also be produced by a thickened submucosa which may appear normal (fig. 95), edematous, inflamed, or infiltrated by tumor cells.

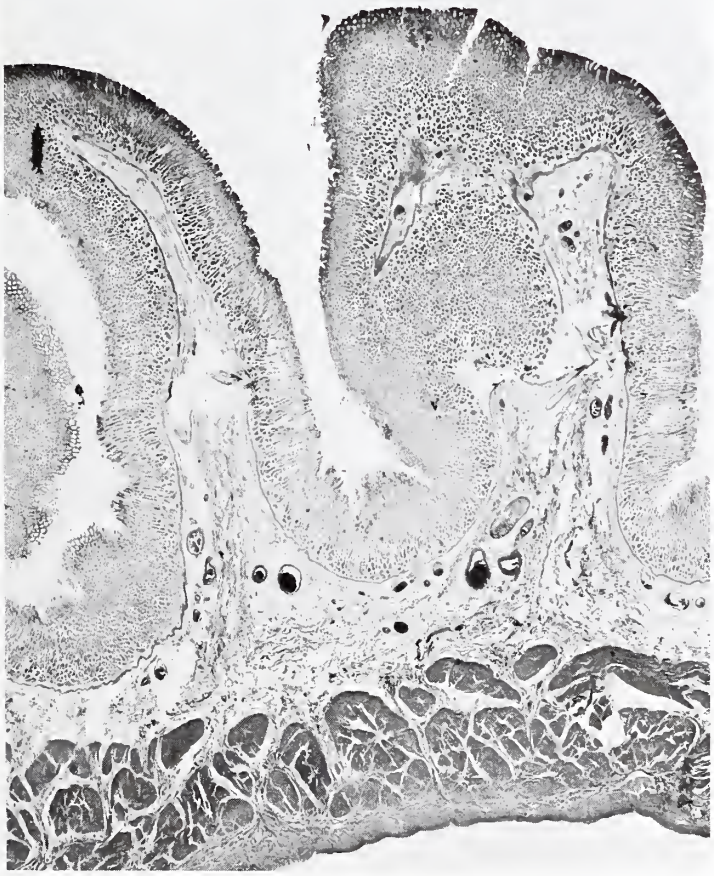

Fig 95

Schindler divided chronic hypertrophic gastritis into three histologic types: (1) the interstitial type with marked inflammatory infiltration in the lamina propria; (2) the proliferative type with prominent surface epithelium but normal deep glands; and (3) the glandular type with increased length and number of glands. The latter two types showed mild or no interstitial inflammation. For this reason, in recent years mere descriptive terms such as hypertrophic gastropathy, giant hypertrophy of gastric mucosa, and giant rugosity have been applied to these latter conditions. Pathologically, only when the thickened mucosa is composed of an excessive number of glandular cells, it assumes a specific entity; hence, the term **hyperplastic gastropathy** is adopted.

Identification of hyperplastic gastropathy dates back to 1888, when Ménétrier described it in detail. He interpreted the abnormally thickened rugae as polyps and called the condition *polyadénomes en nappe* and the circumscribed polyps *polyadénome polypeux*.

Fig. 95

LARGE RUGAE WITH NORMAL MUCOSA

This is a photomicrograph of a stomach resected surgically for so-called chronic hyperplastic gastritis because of prominent rugal folds. These folds were formed by redundant submucosa and normal mucosa. × 7 4

Grossly, the gastric mucosal folds are markedly enlarged resembling ruffled cloth or cerebral convolutions. When localized, they simulate neoplasm (Sussman et al.). The enlarged folds, which follow the normal rugal patterns of the stomach, are least evident in the prepyloric region and along the lesser curvature, a feature which distinguishes it from neoplasm (fig. 96). Occasionally, the uneven hyperplasia results in focal nodularity, often mistakenly interpreted as polyposis.

Microscopically, the hyperplastic mucosa shows one of three main types:

1. Mucous cell type, in which the hyperplasia involves the mucous surface and foveolar cells, whereas the glands proper are atrophic or normal. There is often prominent cystic dilatation of glands (fig. 97).

2. Glandular type, in which the hyperplasia involves the glands proper with a marked increase of parietal and chief cells, whereas the foveolae are short and mucous cells are either normal or reduced (fig. 98).

3. Mixed type, in which the hyperplasia involves both the mucous and specialized cells.

Interstitial inflammation, focal cystic dilatation of the glands, and intestinal metaplasia are sometimes present, particularly in the mucous cell type.

Hyperplastic gastropathy has created much interest recently because of its varied physiologic and clinical manifestations. In cases with hyperplasia of glands, the hypersecretory activity of the gastric mucosa resulted in high acidity of the gastric juice and peptic ulceration. It is best exemplified by **Zollinger-Ellison syndrome** as-

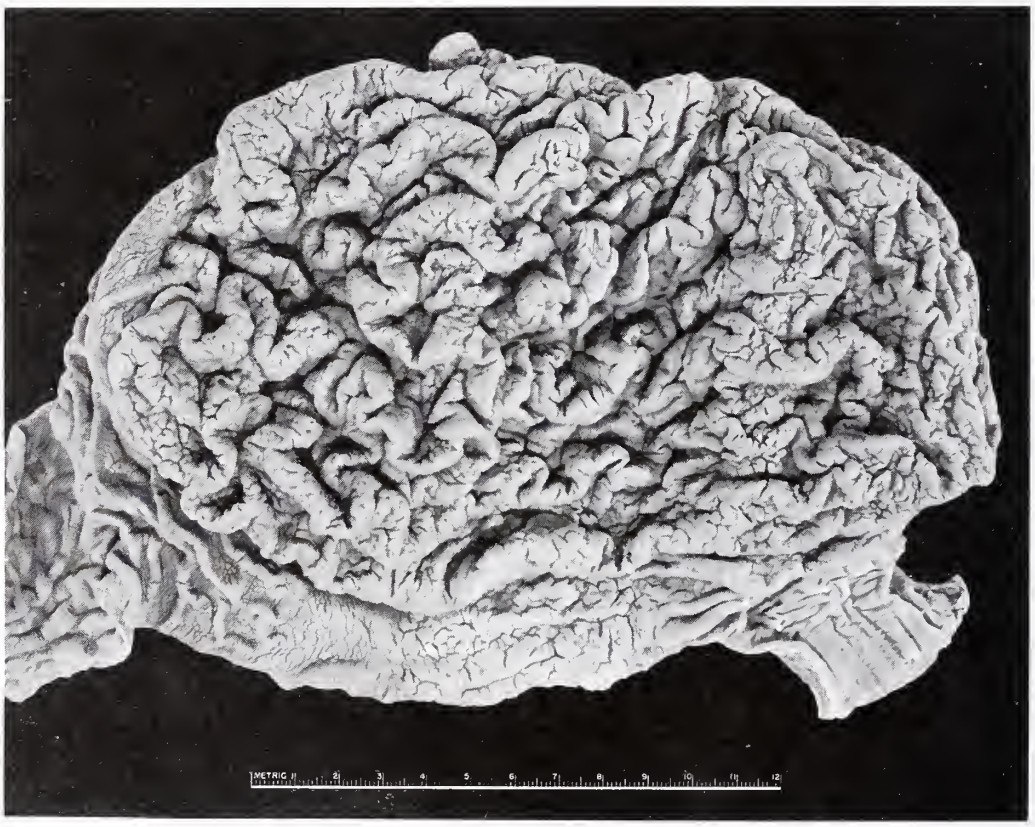

Fig 96

HYPERPLASTIC GASTROPATHY

This stomach was opened along the lesser curvature. Markedly enlarged rugal folds in a branching pattern generally parallel the longitudinal axis of the stomach. They measure up to 1 cm. in width and 1 cm. in height above the depressed furrows. The rugae in the pyloric antrum are normal. The mucosa along the lesser curvature (lower border) has a cobblestone surface, but no large folds. This was an incidental finding at autopsy in a 41-year-old man.

sociated with tumors of the islets of Langerhans (figs. 98, 99). These clinical and pathologic findings have also been seen in cases without islet cell tumors (Reese et al.; Stempien et al.), but associated with tumors of other endocrine glands (Murphy et al.). While the presence of substances with gastrin-like actions in some islet cell tumors is thought to be responsible for the gastric hypersecretion, no explanation has been offered for the increase of secretory cells. Schlaeger and associates had noted a similar mucosal thickening and rigidity in the duodenum and jejunum, and Zollinger and Moore called attention to intestinal rather than gastric symptoms in some cases with islet cell tumors. Thus, endocrine stimulation of the digestive mucosa appears to be generalized.

The opposite clinical manifestation is hypo-secretion with achlorhydria or low acidity of the gastric juice (Brown and Van Pelt). Some of these patients had hypoproteinemia (Butz; Kenney et al.), apparently due to the loss of serum albumin into the gastric secretion, as shown by Citrin and associates. The gastric mucosa in these cases showed hyperplasia of mucous cell type with variable degrees of cyst formation and chronic inflammation, and loss of parietal and chief cells (Brown

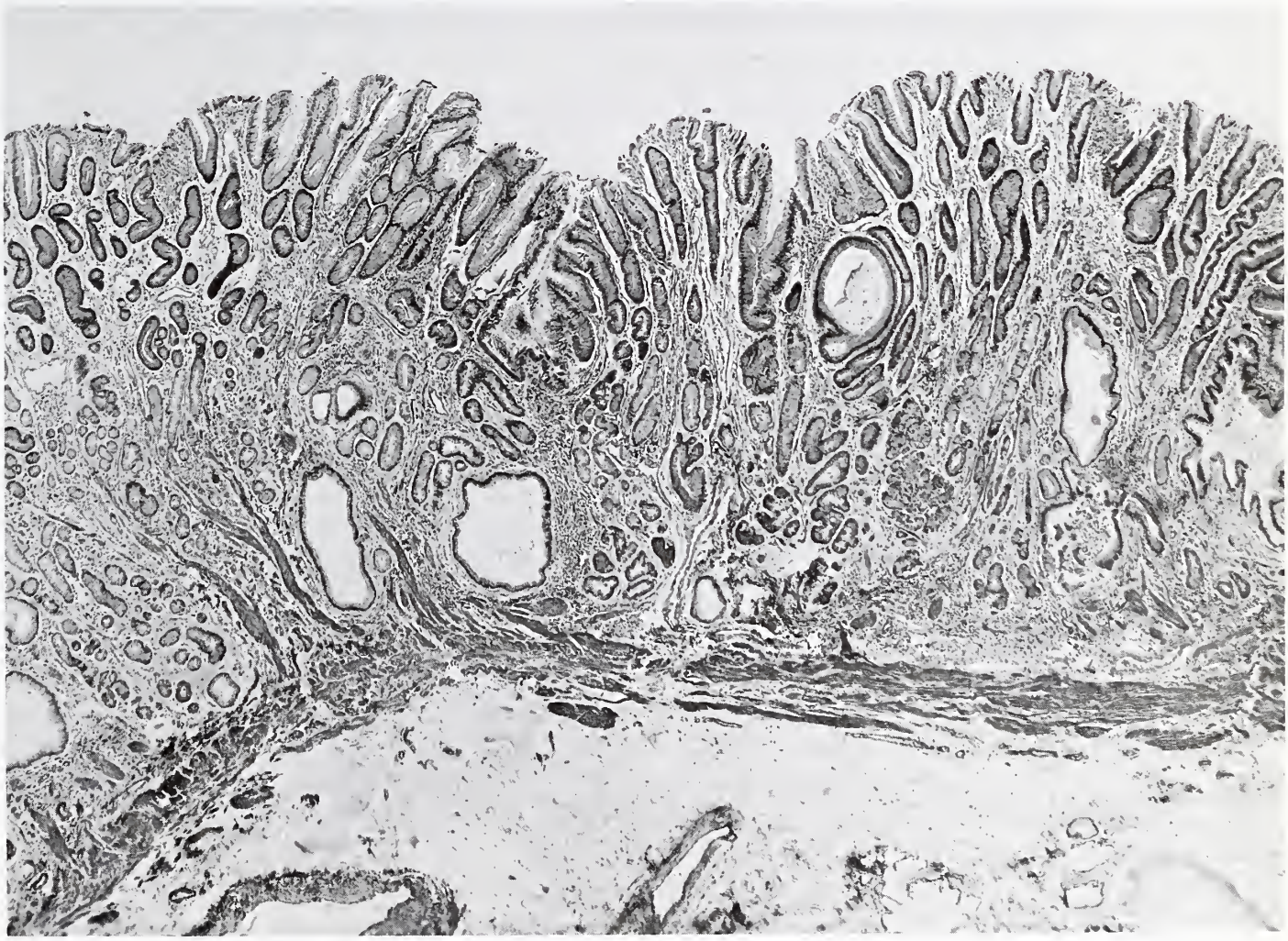

Fig. 97

MUCOUS CELL HYPERPLASIA

This photomicrograph of a section from a surgically resected stomach shows marked hyperplasia of the mucous surface and foveolar cells, but the underlying glands are atrophic or show cystic dilatation. The lamina propria shows focal chronic inflammation and mild fibrosis. × 30.

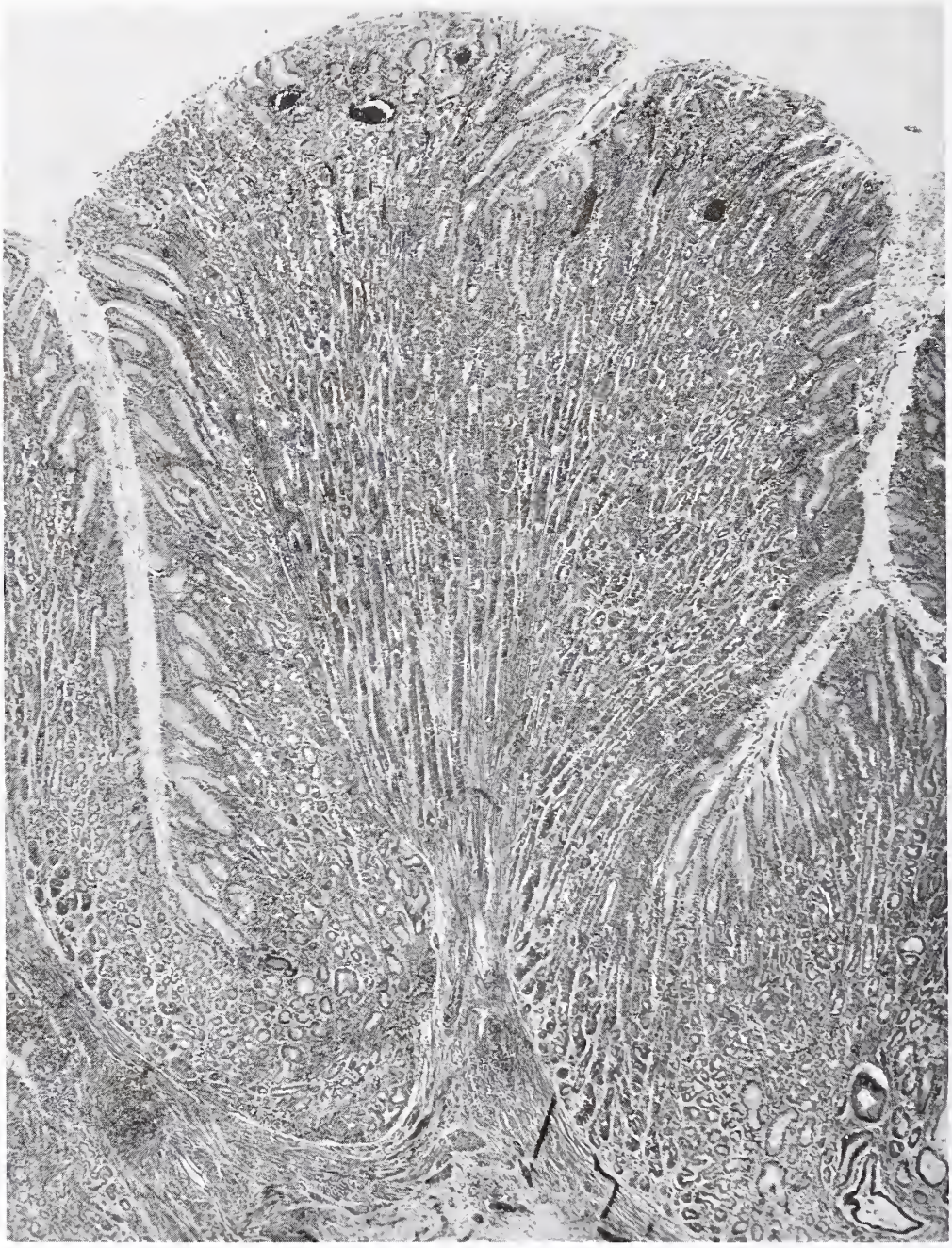

Fig 98

GLANDULAR HYPERPLASIA IN ZOLLINGER-ELLISON SYNDROME

This is a photomicrograph of a markedly hyperplastic stomach from a 39-year-old man with Zollinger-Ellison syndrome. The mucosa of the fold shown in the center is about six times thicker than the normal appearing mucosa bordering it. Hyperplasia involves the glands with numerous parietal cells, whereas the superficial and foveolar portions remain normal. × 25.

and Van Pelt). In many cases, however, the specialized secretory cells were considered to be normal (Butz). This latter syndrome has been most frequently called Ménétrier's disease; however, the gastric lesions of the two cases described by Ménétrier were incidental findings at autopsy without known gastric complaints, and his illustrations appear to show hyperplasia of mixed type. Irrespective of the secretory conditions of the stomach, all the reported patients were adults, mostly males 40 to 60 years of age. Other than ulcer symptoms, complaints were not specific;

many patients had upper abdominal pain, nausea, and vomiting Weight loss was noted in some patients The giant rugae seen on roentgenogram should be distinguished from those due to tumor infiltration. When diagnosing hyperplastic gastropathy by biopsy, the specimen should include the whole thickness of gastric mucosa because the superficial mucosa may appear normal.

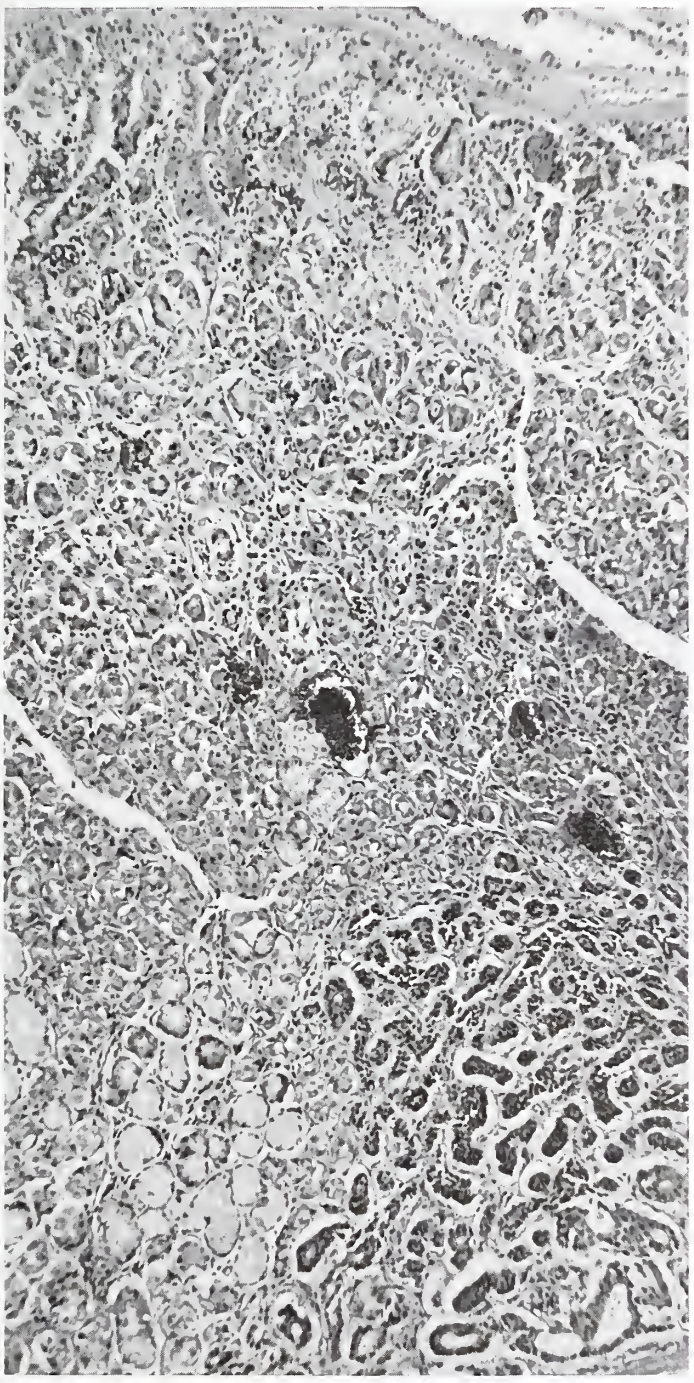

Fig. 99

ZOLLINGER-ELLISON SYNDROME

A 38-year-old man had a malignant islet cell tumor of the pancreas which metastasized to regional lymph nodes and to the gastric mucosa, the latter is shown in the right lower corner of this photomicrograph. The gastric mucosa otherwise shows a marked glandular hyperplasia with increased parietal cells and reduced mucous cells. A few pyloric glands are seen in the deep mucosa. × 90

References

Brown, W G., and Van Pelt, M W Hypertrophic hyposecretory gastropathy A case report Cancer 23 1163–1170, 1969

Butz, W C Giant hypertrophic gastritis A report of fourteen cases Gastroenterology 39 183–190, 1960.

Citrin, Y., Sterling, K., and Halsted, J A The mechanism of hypoproteinemia associated with giant hypertrophy of the gastric mucosa New Eng. J Med 257.906–912, 1957

Kenney, F. D., Dockerty, M B., and Waugh, J M Giant hypertrophy of gastric mucosa A clinical and pathological study. Cancer 7 671–681, 1954

Ménétrier, P Des polyadénomes gastriques et de leurs rapport avec le cancer de l'estomac. Arch. Physiol. Norm. Path 1.32–55, 1888

Murphy, R T., Goodsitt, E., Morales, H., and Bilton, J L. Peptic ulceration with associated endocrine tumors; collective review and report of a case. Amer J. Surg 100: 764–778, 1960

Reese, D F., Hodgson, J R., and Dockerty, M B Giant hypertrophy of the gastric mucosa (Menetrier's disease): A correlation of the roentgenographic, pathologic, and clinical findings. Amer. J. Roentgen. 88.619–626, 1962

Schindler, R Gastritis, p 48 New York: Grune & Stratton, 1947

Schlaeger, R., LeMay, M., and Wermer, P. Upper gastrointestinal tract alterations in adenomatosis of the endocrine glands Radiology 75.517–530, 1960.

Stempien, S J., Dagradi, A E., Reingold, I M., Heiskell, C L., Goodman, J R., Bloom, A., and Weaver, D S. Hypertrophic hypersecretory gastropathy. Analysis of 15 cases and a review of the pertinent literature. Amer J. Dig Dis. 9:471–493, 1964.

Sussman, H M., Weingarten, B., and Mossberg, S M. Localized gastric mucosal hypertrophy simulating tumor. Amer J Dig Dis 10.710–718, 1965.

Zollinger, R M., and Moore, F. T. Zollinger-Ellison syndrome comes of age. Recognition of the complete clinical spectrum and its management. J.A.M.A. 204.361–365, 1968

TUMOR-LIKE LESIONS AND CYSTS OF DEVELOPMENTAL ORIGIN

HETEROTOPIC TISSUE

Heterotopic tissue derived from the distal end of the foregut may be found in the gastric wall. The most commonly identified tissue is pancreatic. Busard and Walters reviewed 543 cases of **heterotopic pancreatic tissue**; the tissue was widely scattered in the abdominal organs, with about 60 percent in the stomach or duodenum. Palmer reviewed 215 cases of aberrant pancreas in the stomach; 85 percent were located at the pylorus or in the antrum, and in about one-fourth of the cases it caused pyloric obstruction. The heterotopic tissue usually formed a single disklike mass with ill-defined borders; a polypoid mass was rare. In 90 percent of cases, the resultant tumor was small and less than 2 cm. in size. A central depression on the mucosal surface characterized the gross and roentgenologic features. Microscopically, pancreatic tissue is usually located in the submucosa (fig. 100). Islets of Langerhans are present in many cases (fig. 101). Many of the ducts are dilated and Brunner-type glands may be present (fig. 102). In rare instances, only **Brunner's glands** were present as in a case

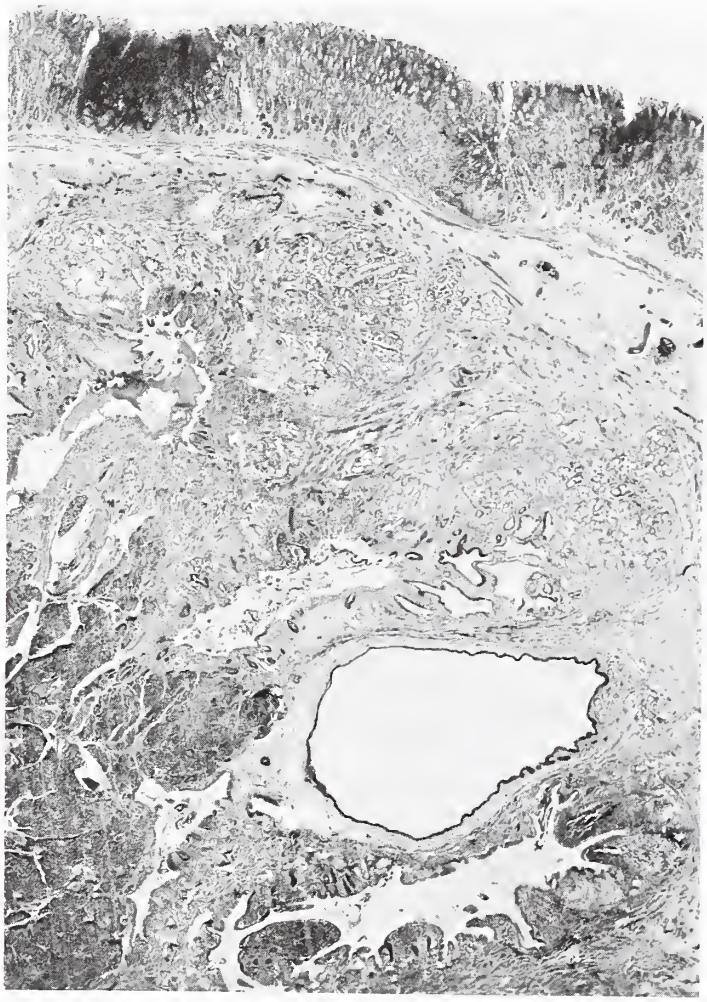

Fig 100

HETEROTOPIC PANCREAS AND BRUNNER'S GLANDS

(Figures 100 – 102 from same case)

This photomicrograph of a submucosal nodule in the anterior wall of the stomach measured 2.5 x 2.5 x 1.5 cm. It shows pancreatic tissue (lower half), dilated ducts, and Brunner's glands (upper half) in the submucosa. Islets of Langerhans are also present. This 46-year-old patient suffered from a duodenal ulcer. × 11. (Courtesy of Dr. R. J. Furie and Dr. R. J. Thomas, Frederick, Md.)

Fig. 101

HETEROTOPIC PANCREAS

(Figures 100 – 102 from same case)

Higher magnification of the same specimen shown in figure 100 reveals exocrine pancreatic acini and an islet of Langerhans. × 110. (Courtesy of Dr. R. J. Furie and Dr. R. J. Thomas, Frederick, Md.)

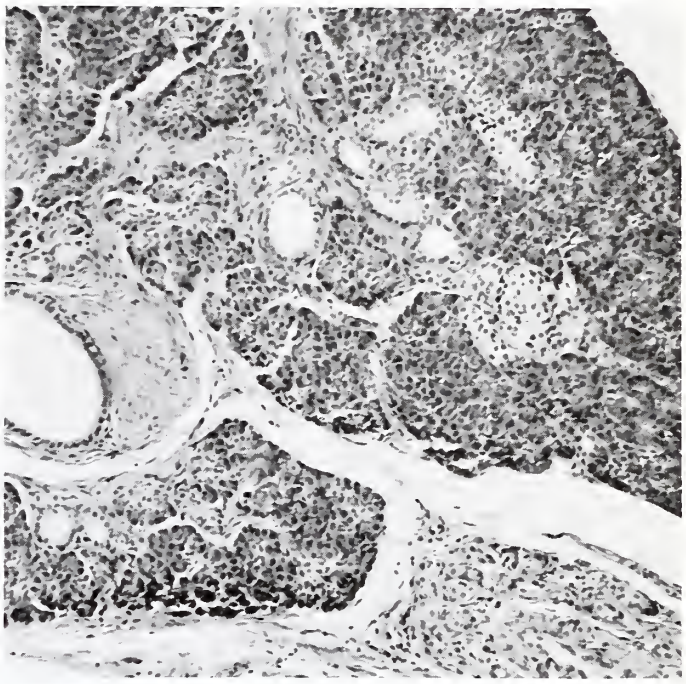

Fig. 101

Fig. 102

HETEROTOPIC PANCREAS AND BRUNNER'S GLANDS

(Figures 100 – 102 from same case)

In this photomicrograph pancreatic acini are seen in the upper field and Brunner's glands in the lower field. × 110. (Courtesy of Dr. R. J. Furie and Dr. R. J. Thomas, Frederick, Md.)

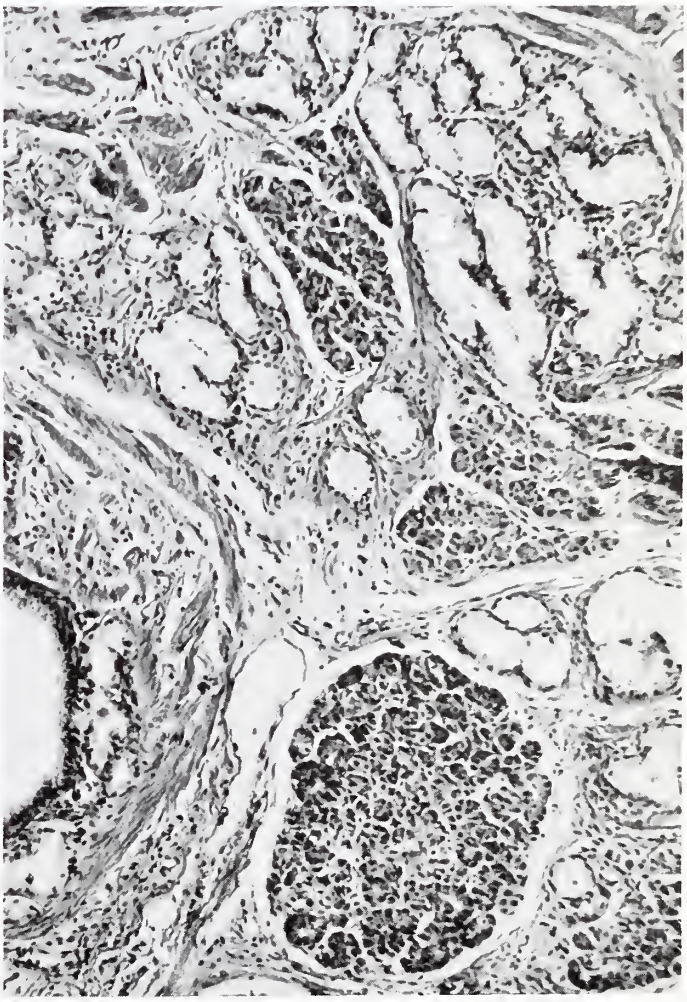

Fig. 102

reported by Berant and associates. Ducts lined by cuboidal or columnar cells, often appearing in a disarrayed muscularis, were the main finding in other cases (fig. 103). In such instances, the term **adenomyoma** has been applied, although often small islands of pancreatic tissue and Brunner's glands are also present (Goldberg and Margulis). Similar lesions were called myoepithelial hamartomas by Clarke, which is a misnomer since the tumor is not composed of myoepithelial cells but of smooth muscle cells and heterotopic epithelial tissue. Goldfarb and associates documented a case of carcinoma originating from the heterotopic pancreas and causing pyloric obstruction. Ciliated and squamous epithelium, apparently from the displaced proximal foregut, rarely forms a mass in the upper stomach. Gensler and associates reported such a finding in a 46-year-old woman with a large cystic intramural mass in the fundus.

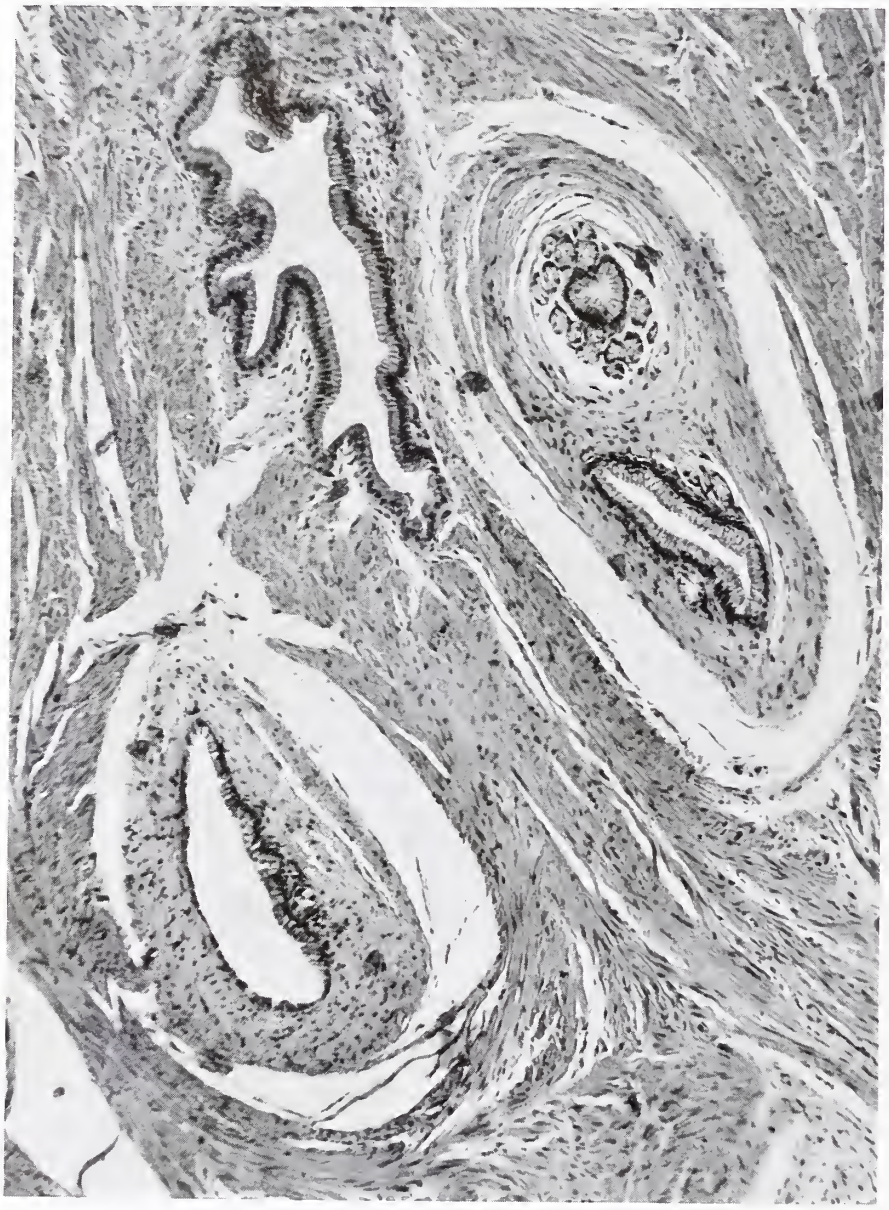

Fig. 103

HETEROTOPIC PANCREAS (ADENOMYOMA)

This is a photomicrograph of the thickened muscularis propria of pyloric antrum causing obstruction in a 61-year-old woman. It shows ducts and a few mucous glands in the disarrayed muscularis. × 95.

DUPLICATION CYST

Gastric duplications forming cystic or tubular masses, with or without communication with the digestive tract, may occur anywhere along the foregut. Those located principally in the thorax have been discussed in the section on tumors of the esophagus. Lewis and associates reviewed 39 recorded cases of gastric duplication cysts located along the stomach; 25 were in children and 14 in adults, with ages ranging from newborn to 67 years. In 36 cases, the duplication cyst formed a spherical cystic mass and in three the formation was tubular. The cysts ranged from 1.3 to 10 cm. in size, and were located primarily along the greater curvature or in the distal third of the stomach, compressing the gastric wall. Only six of the 39 cases showed communication of the cyst with the lumen of stomach or intestine. Abrami and Dennison reported a case in a 1-day-old infant with duplication cysts of the lower esophagus and duodenum as well as the stomach. At The Massachusetts General Hospital, a 5-year-old girl was found to have a duplication cyst of the stomach, connected by a fistulous tract with accessory pancreatic tissue (fig. 104). The majority of duplication cysts were lined by normal appearing gastric mucosa and muscularis, and a few were lined by columnar or atrophic epithelium (fig. 105). It has been postulated that duplication cysts originate as remnants of embryonal diverticula or from the fusion of longitudinal folds of the stomach during embryonic life (Bremer).

Fig. 104

DUPLICATION CYST

This cyst in a 5-year-old girl was attached to a tongue of accessory pancreas, which projected from the mid-portion of a normal pancreas, shown on the left. The cyst wall is composed of gastric mucosa and thick muscularis. (Courtesy of Dr. Benjamin Castleman, Boston, Mass.; also fig. 2 of case 17-1964, Clinical Pathological Conference, Massachusetts General Hospital. New Eng. J. Med. 270:736–742, 1964.)

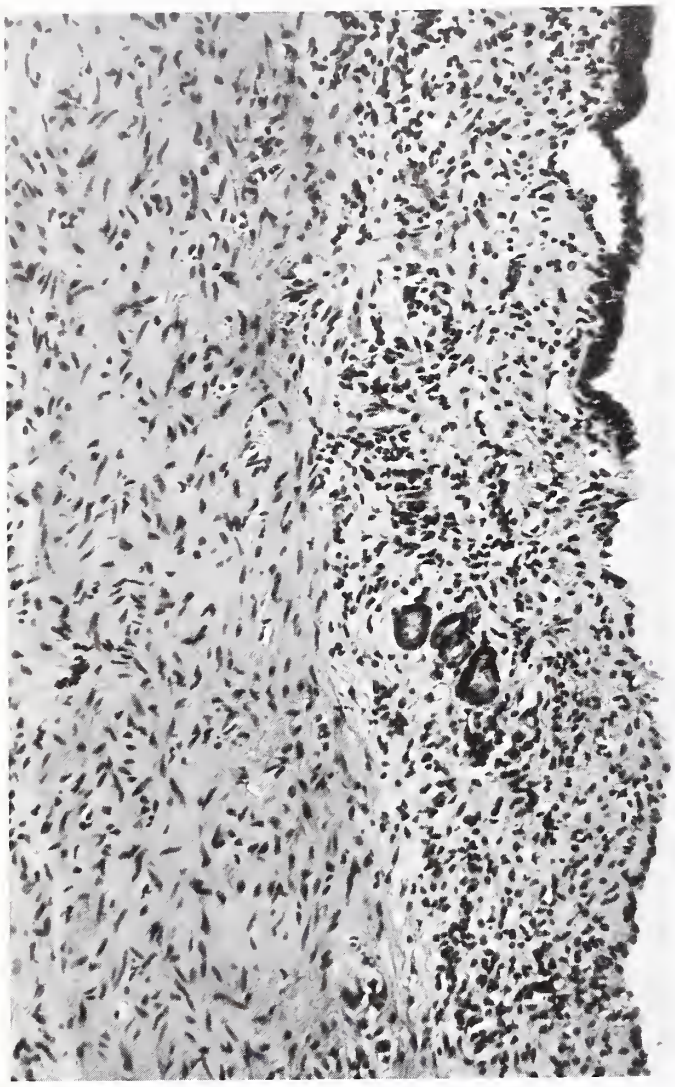

Fig. 105

DUPLICATION CYST

This photomicrograph of a duplication cyst of the stomach in an 18-month-old girl shows that the cyst is lined by columnar cells. A few pyloric glands are present in the mucosa. × 168.

References

Abrami, G., and Dennison, W. M. Duplication of the stomach. Surgery 49:794–801, 1961.

Berant, M., Aviad, I., and Jacobs, J. Heterotopic duodenal mucosa in the stomach. Amer. J. Dis. Child. 110:566–569, 1965.

Bremer, J. L. Diverticula and duplications of the intestinal tract. Arch. Path. 38:132–140, 1944.

Busard, J. M., and Walters, W. Heterotopic pancreatic tissue. Report of a case presenting symptoms of ulcer and review of the recent literature. Arch. Surg. 60:674–682, 1950.

Clarke, B. E. Myoepithelial hamartoma of the gastrointestinal tract. A report of eight cases with comment concerning genesis and nomenclature. Arch. Path. 30:143–152, 1940.

Clinical Pathological Conference, Massachusetts General Hospital, Case 17–1964. New Eng. J. Med. 270:736–742, 1964.

Gensler, S., Seidenberg, B., Rifkin, H., and Rubinstein, B. M. Ciliated lined intramural cyst of the stomach. Case report and suggested embryogenesis. Ann. Surg. 163:954–956, 1966.

Goldberg, H. I., and Margulis, A. R. Adenomyoma of the stomach. Report of a case. Amer. J. Roentgen. 96:382–387, 1966.

Goldfarb, W. B., Bennett, D., and Monafo, W. Carcinoma in heterotopic gastric pancreas. Ann. Surg. 158:56–58, 1963.

Lewis, P. L., Holder, T., and Feldman, M. Duplication of the stomach. Report of a case and review of the English literature. Arch. Surg. 82:634–640, 1961.

Palmer, E. D. Benign intramural tumors of the stomach: a review with special reference to gross pathology. Medicine 30:81–181, 1951.

BENIGN EPITHELIAL POLYPS

Polyp is a gross descriptive term applied to any lesion which projects from the mucosal surface into the lumen of the stomach. Its true nature rests on its histologic characteristics. It is well recognized that many inflammatory lesions may thicken the mucosa or submucosa to such a degree that a polypoid mass results. A polyp thus formed is properly named inflammatory polyp. It is also known that many benign and malignant neoplasms may assume a polypoid form. In this section, only polyps of epithelial origin will be discussed. There has been much discussion concerning the relationship of these polyps to carcinoma. Unfortunately, opinions have often been based on the statistical association of these two conditions rather than on histogenetic evaluation. Thus, epithelial polyps have been regarded as precancerous due to the presence of an independent carcinoma in the same stomach.

Ming and Goldman evaluated the histologic features of 90 polyps removed from 49 patients and concluded that there were two distinct histologic types; one large group of polyps had no malignant potential, and the other much smaller group showed a tendency to develop invasive carcinoma within the polyp. The first group of polyps were considered regenerative and nonneoplastic, and the second group were called adenomatous because of their neoplastic nature. Gross characteristics of these tumors, to be discussed later, coincide well with the roentgenologic features of the two groups of polyps discussed by Marshak and Feldman; they referred to one group as benign adenomatous polyps and the other as villous adenomas with high malignant potentiality.

In addition to these two major types of polyps, other kinds also occur in the stomach. Although minor overlaps of histologic features may be found, epithelial polyps of the stomach may be readily classified into the following types:

1. Hyperplastic adenomatous polyp
2. Papillary adenoma
3. Familial polyposis
4. Hamartomatous polyp
5. Heterotopic adenomatous polyp
6. Mucosal nodule

HYPERPLASTIC ADENOMATOUS POLYP

These polyps are the most common type seen in the stomach, comprising 80 to 90 percent of all polyps. They are composed almost entirely of hyperplastic mucous cells. Grossly, these polyps are small, seldom over 2 cm. in diameter (figs. 106–108). The smaller ones are sessile, but the larger polyps may be pedunculated. Their contour is round or oval and their surface is smooth or slightly lobulated. Hemorrhage and superficial ulceration of the tip of the polyp are sometimes present. Polyps occur anywhere in the stomach. When located in the fundic mucosa, they are often situated on a rugal fold (fig. 106), a commonly observed feature in the roentgenogram (fig. 109). The surrounding mucosa may appear normal (fig. 106) or atrophic (fig. 107). Multiplicity occurs in about one-third of the cases.

Fig. 106

HYPERPLASTIC ADENOMATOUS POLYPS

These small, round or oval polyps are typical of hyperplastic adenomatous polyps. Several are located on the rugal folds. Their surface is smooth unless superficially ulcerated. (Courtesy of Beth Israel Hospital, Boston, Mass.)

When multiple polyps are present, the term polyposis is often used, but there is no agreement on what minimal number of polyps is necessary to be classified as polyposis. According to Dedichen and Helsingen, the minimal number of polyps was three, and McNeer and associates required six, but in most reports no number was specified. Some authors have also applied the term polyposis to large rugal folds. Therefore, the term polyposis should be limited to the familial type.



Fig. 107

HYPERPLASTIC ADENOMATOUS POLYPS

This surgically resected stomach contains several polyps. Some are in the fundic mucosa, shown on the right. The small ones are sessile and their surface is smooth. The larger ones have a short stalk and their surface is slightly lobulated. The gastric mucosa is atrophic. (Courtesy of Dr. Benjamin Castleman, Boston, Mass.; also fig. 1 from Monaco, A. P., Roth, S. I., Castleman, B., and Welch, C. E. Adenomatous polyps of the stomach. A clinical and pathological study of 153 cases. Cancer 15:456–467, 1962.)



Fig. 108

HYPERPLASTIC ADENOMATOUS POLYPS

These round, smooth polyps situated in the antral mucosa are 1 to 1.5 cm. in diameter. The one shown at the center is partly ulcerated. The mucosa between the polyps is normal. (Courtesy of Beth Israel Hospital, Boston, Mass.)

Fig. 109

Fig. 109

HYPERPLASTIC ADENOMATOUS POLYP

A single polyp (arrow), situated on a rugal fold, is shown in this roentgenogram of the stomach

Microscopically, hyperplastic adenomatous polyps are composed predominantly of hyperplastic foveolar cells, forming dilated tubular structures, many of which are not connected with the deep glands and some of which are cystic (figs. 110–112). These hyperplastic cells form a single layer and are regularly arranged. Their nuclei are basal and small and the cytoplasm contains a large amount of mucus secretion (fig. 113). Mitoses are rare and there is little or no atypism. In the small sessile lesions, normal glands are present at their base (fig. 110). In the larger polyps, the fundic glands are absent, but many normal appearing pyloric glands may be seen (fig. 114). There is usually a mild to moderate degree of chronic inflammation, and proliferation of fibrous and muscular tissue. The latter appears to have originated from the adjacent muscularis mucosae. Intestinal metaplasia is absent in many polyps, and mild and focal in others. Chronic inflammation and atrophy are usually seen in the surrounding mucosa. Independent carcinoma coexisted in 7 percent of Ming and Goldman's cases. These histologic characteristics indicate an exuberant, but benign, proliferation of mucous cells and suggest the possibility of a reparative rather than a neoplastic process. This view is supported by the observation of Marshak and Feldman that, with rare exceptions, polyps of this type remained stationary in both size and configuration. For these reasons, these polyps had previously been called regenerative polyps (Ming and Goldman). Since this aspect is by no means certain, hyperplastic polyp, as a descriptive term, is perhaps more appropriate. These polyps are innocuous in themselves and a simple polypectomy is sufficient for cure. Whether single or multiple, they are stationary and there is no evidence of malignant transformation. When new polyps develop in the same stomach, they are generally of the same type. Careful roentgenologic follow-up and surgical exploration are indicated, however, because of the possibility of coexisting carcinoma. Marshak and Feldman suggested an initial reexamination of the patient in three months and further examination every nine months to one year.

Fig 110

HYPERPLASTIC ADENOMATOUS POLYP

This sessile polyp from the fundic mucosa measured 7 mm. in diameter and was composed primarily of hyperplastic mucous cells of the unusually deep foveolae. Focal cystic dilatation is present. The glands in the periphery of the polyp and in the contiguous mucosa on the right are normal; those shown on the left are atrophic. A mild, superficial chronic inflammation is present. × 10

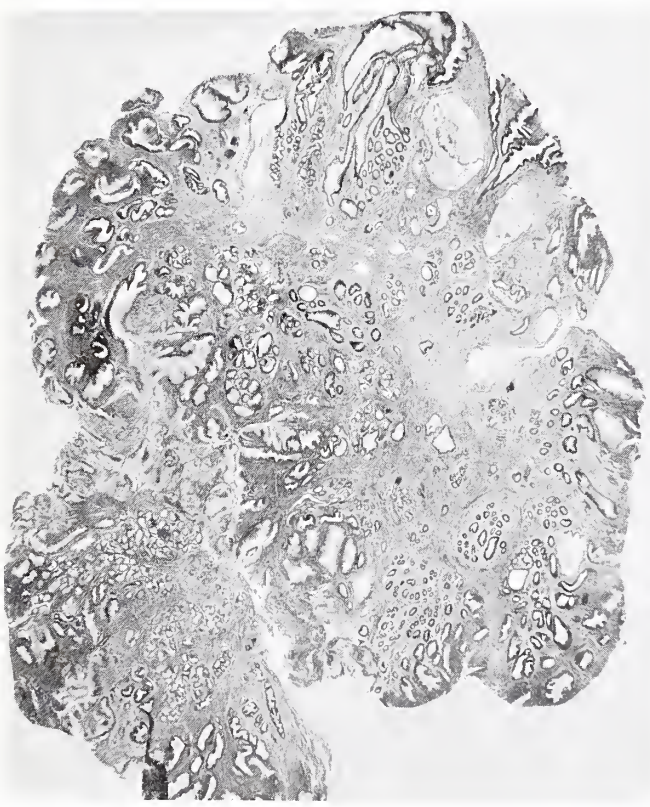

Fig 111

Fig 111

HYPERPLASTIC ADENOMATOUS POLYP

(Figures 111 and 114 from same case)

This polyp from the pyloric antrum measured 1 6 cm. in diameter. The outer half of the polyp is composed of hyperplastic foveolar mucous cells with focal cyst formations. The inner portion is composed of small glands. There is chronic inflammation and fibrosis in the interstitium. Similar changes were present in the surrounding mucosa. × 5 (Courtesy of Beth Israel Hospital, Boston, Mass.)

HYPERPLASTIC ADENOMATOUS POLYP

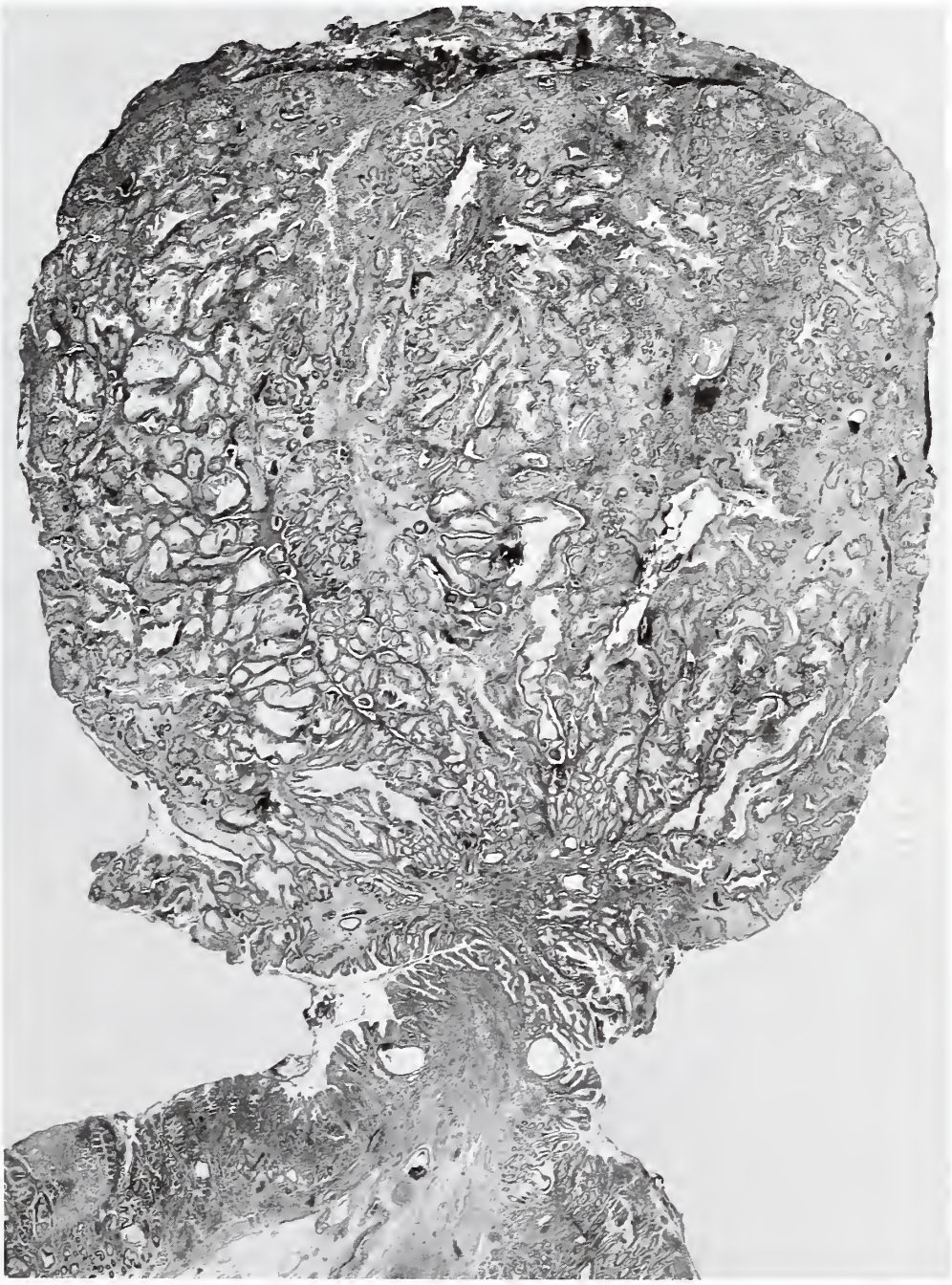

Fig 112

(Figures 112 and 113 from same case)

This pedunculated polyp from the pyloric antrum of a 73-year-old man measured 2 cm. in diameter. It is composed of dilated glandular structures lined by hyperplastic mucous cells. Cystic dilatation of the foveolae is also present in the stalk and adjacent mucosa. Chronic inflammation is present in the stroma of the polyp as well as the surrounding mucosa. The top of the polyp is superficially eroded and hemorrhagic. × 6

Fig 113

HYPERPLASTIC ADENOMATOUS POLYP

(Figures 112 and 113 from same case)

This photomicrograph of the mucous cells in the same polyp as figure 112 shows their regular arrangement. The nuclei are basal and small and the cytoplasm contains a large amount of mucus. Chronic inflammation is present in the stroma. × 140

Fig. 113

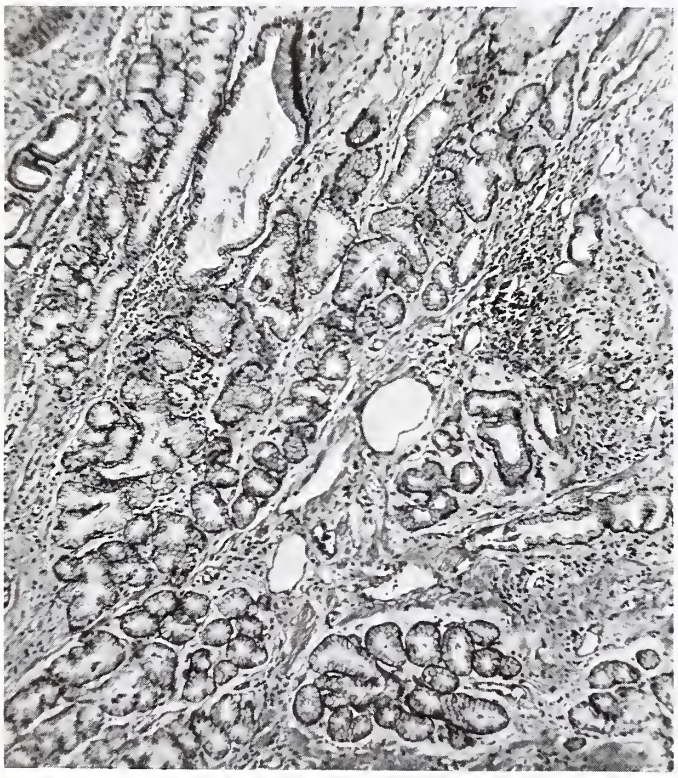

Fig. 114

Fig. 114

HYPERPLASTIC ADENOMATOUS POLYP

(Figures 111 and 114 from same case)

This photomicrograph reveals that the small glands in figure 111 are identical with normal pyloric glands in their histologic appearance. The interstitial tissue is focally infiltrated by lymphocytes. × 80 (Courtesy of Beth Israel Hospital, Boston, Mass.)

PAPILLARY ADENOMA* (VILLOUS ADENOMA)

This type of polyp is characterized by its papillary configuration. It closely resembles the villous adenomas of the colon and rectum, both pathologically and behaviorally. In 1951, Walk reviewed 51 published cases and reported two additional cases. Only 18 percent of the lesions were under 2 cm. in diameter and one-half were larger than 4 cm. Malignant changes were noted in 25 to 72 percent of these lesions. Metastases were present in 4 of 33 surgical cases. This type of tumor has received little attention in recent years. Ming and Goldman found 10 lesions in 49 cases of gastric polyps, and Marshak and Feldman found 8 among 138 polypoid lesions examined roentgenologically. In the former report, the polyps had been simply called adenomatous, although their papillary nature was recognized.

Grossly, these adenomas usually have a broad base, but pedicles may also be present. Their contour is irregular or trabeculated, with thin or broad papillary projections separated by deep fissures (figs. 115, 116). These features are

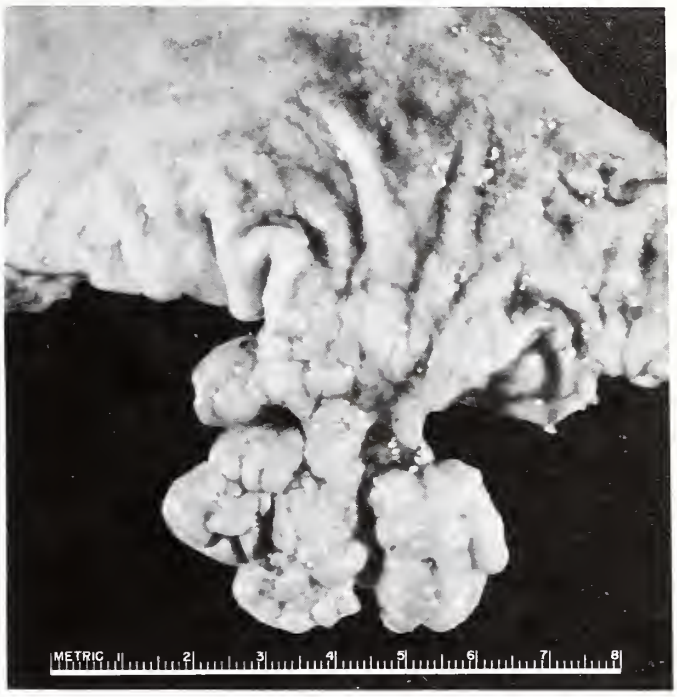

Fig. 115

PAPILLARY ADENOMA

This polyp, from the fundic mucosa in a 65-year-old woman, measured 4 x 4 x 3.8 cm. with a 2 x 2 cm. base. The papillary areas are separated by deep fissures. (Courtesy of Beth Israel Hospital, Boston, Mass.; also fig. 4 from Ming, S.-C., and Goldman, H. Gastric polyps. A histogenetic classification and its relation to carcinoma. Cancer 18:721–726, 1965.)

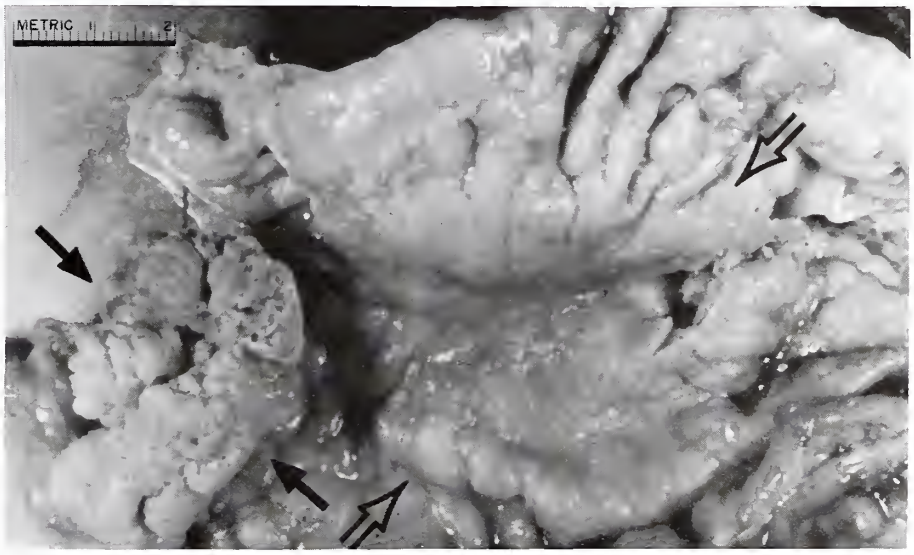

Fig. 116

PAPILLARY ADENOMA

(Figures 116, 117, 119, and 121 from same case)

This stomach was removed from an 83-year-old woman. At the lesser curvature, 2 cm. from the pylorus, there is a 4.5 x 2.7 cm. papillary adenoma (between solid arrows). Proximal to the adenoma, there is a plaquelike carcinoma measuring 6 cm. in diameter (between open arrows).

represented roentgenologically by their irregular outline and linear and spotty radiopacity caused by the deposition of barium within the adenoma (fig. 117), sometimes described as a soap bubble appearance (Shauffer and O'Connor). Over 80 percent of the adenomas were larger than 2 cm. in diameter, and a few as large as 15 cm. in greatest dimension have been reported, suggesting that they originate in a large field of gastric mucosa.

Microscopically, the papillary or villous pattern is apparent (figs. 118, 119). In the depth of fissures, normal or hyperplastic mucosal cells are sometimes seen, suggesting a multicentric origin of the adenoma (fig. 118). In these areas, the neoplastic cells of the adenoma end abruptly at the junction with normal foveolar cells (fig. 120). In other areas, the adenoma appears to originate from the metaplastic glands (fig. 121). The cells lining the villous projections are poorly differentiated and pleomorphic, with hyperchromatic nuclei, frequent mitoses, and decreased secretory activity (fig. 122). Of the 10 adenomas studied by Ming and Goldman, marked cellular dysplasia and disorderly arrangement compatible with preinvasive carcinoma were seen in two tumors and frankly invasive carcinoma was noted in two others. Invasive carcinoma may show a large amount of mucus secretion (fig. 123). Normal gastric glands may be found at the base of the adenoma (figs. 118, 119). The adjacent mucosa often shows foveolar cell hyperplasia and foci of intestinal metaplasia. Inflammation is not prominent, either in the adenoma or in the surrounding mucosa. Independent gastric carcinoma was present in 30 percent of Ming and Goldman's cases. The gross and histologic appearances of these adenomas are so strikingly different from those of the hyperplastic adenomatous polyps that the distinction between them can readily be made. Their sinister potential is also obvious and a more radical approach is required in their clinical management. The adenomas should be examined carefully for evidence of invasive carcinoma in them; if invasion is absent, a sleeve resection including the whole thickness of adjacent gastric wall or partial gastrectomy is appropriate, depending on the size of the lesion, and if invasion is present, lymph node dissection should be included. The possibility of an independent carcinoma coexisting with adenoma should also be kept in mind.

Fig. 117

PAPILLARY ADENOMA

(Figures 116, 117, 119, and 121 from same case)

This roentgenogram illustrates the irregular outline of the papillary adenoma shown in figure 116. Linear and spotty opacities are caused by barium trapped in the crevices.

PAPILLARY ADENOMA

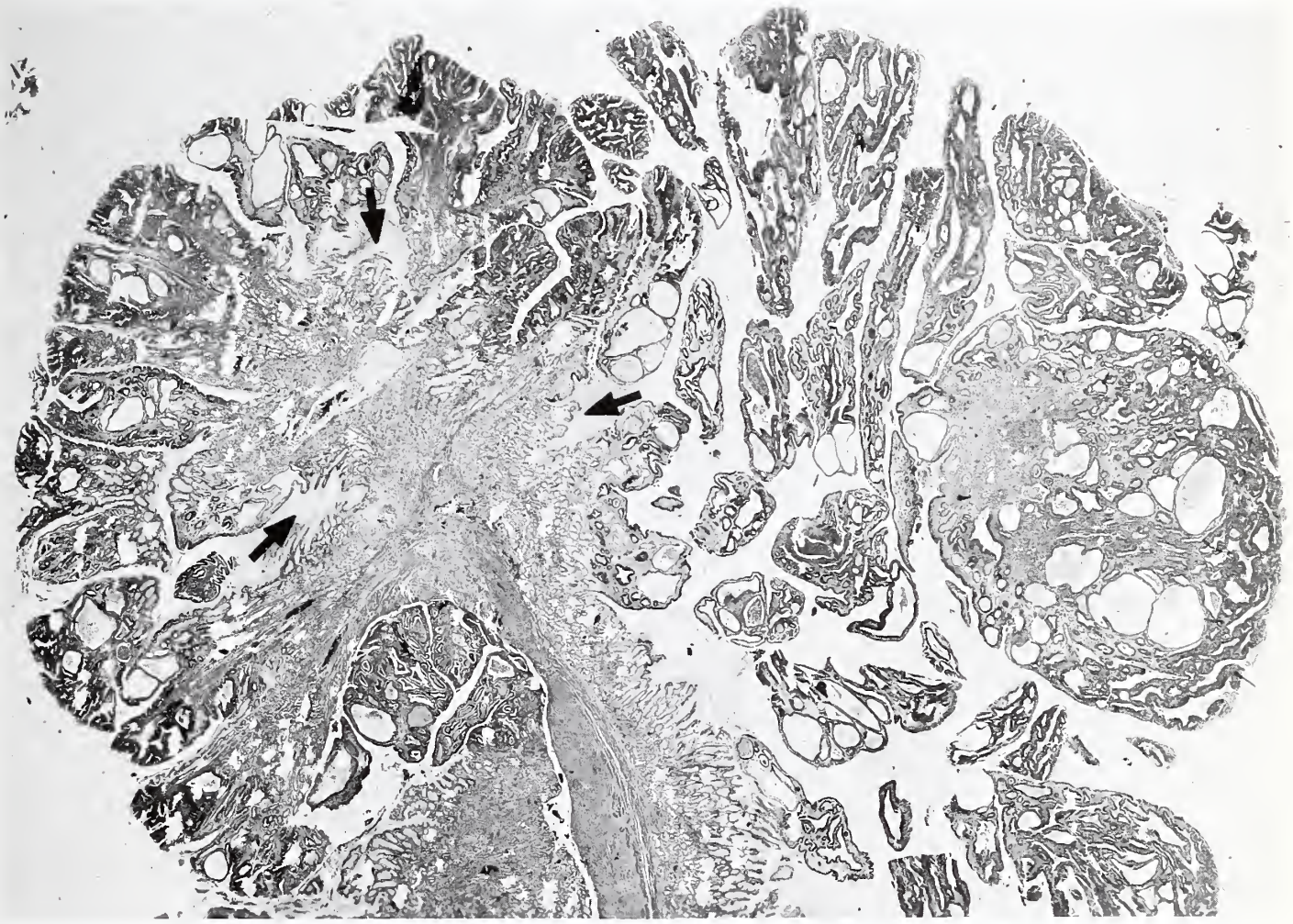

Fig. 118

(Figures 118, 120, and 122 from same case)

This photomicrograph of a portion of a sessile adenoma, measuring 3 cm. in diameter, illustrates the papillary pattern of the lesion. Normal gastric mucosa is seen between the papillary projections (shown at lower border) and at the bottom of narrow crevices (arrows). × 8 (Courtesy of Beth Israel Hospital, Boston, Mass.)

PAPILLARY ADENOMA

Fig. 119

(Figures 116, 117, 119, and 121 from same case)

This photomicrograph of the adenoma seen in figure 116 shows its villous pattern. Remnants of normal pyloric glands and metaplastic glands are seen at the base of the adenoma. × 13

Fig. 120

(Figures 118, 120, and 122 from same case)

This photomicrograph of the same adenoma shown in figure 118 illustrates the abrupt transition from normal mucous cells on the right to neoplastic cells on the left. × 103. (Courtesy of Beth Israel Hospital, Boston, Mass.)

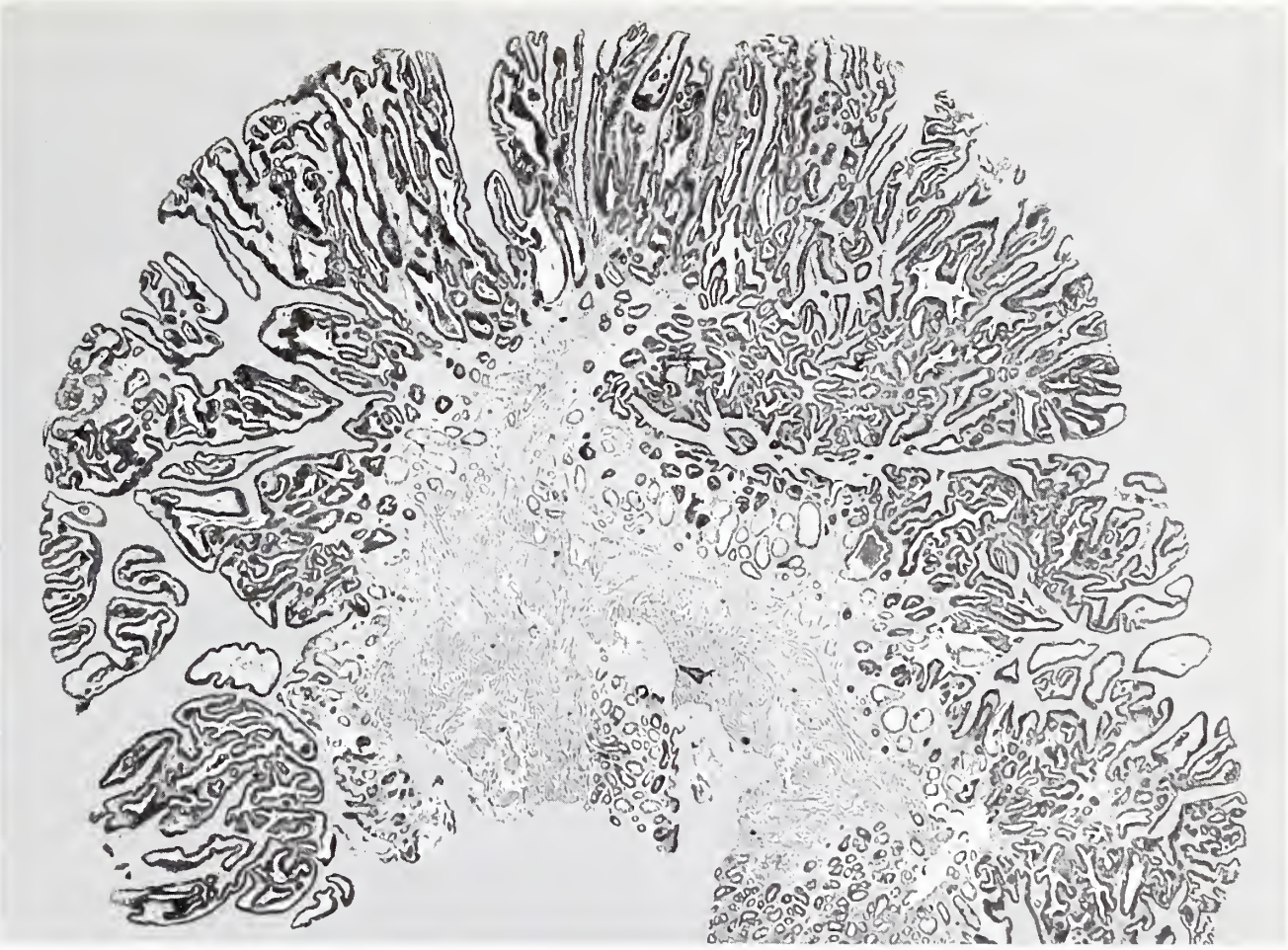

Fig 119

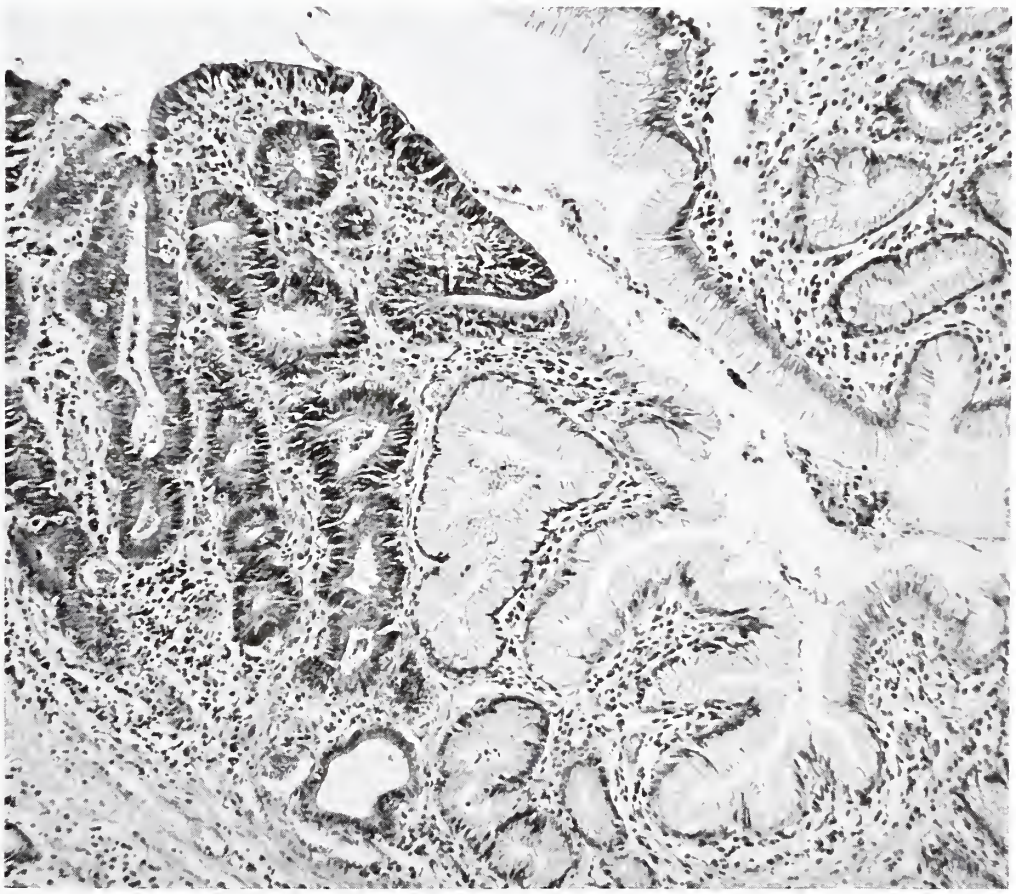

Fig 120

PAPILLARY ADENOMA

Fig. 121

(Figures 116, 117, 119, and 121 from same case)

This photomicrograph shows the structures at the base of the adenoma seen in figure 119. The neoplastic cells of the adenoma are continuous with the glands showing intestinal metaplasia. There are normal pyloric glands at the left lower border. × 140.

Fig. 122

(Figures 118, 120, and 122 from same case)

The neoplastic cells of the adenoma in figure 118 are illustrated in this photomicrograph. They are pleomorphic and pseudostratified. Their nuclei are hyperchromatic and vary in size and location. The cytoplasm is darkly stained and contains no mucus secretion. This appearance suggests in situ malignant alteration, but there was no invasive carcinoma in this adenoma. × 230. (Courtesy of Beth Israel Hospital, Boston, Mass.)

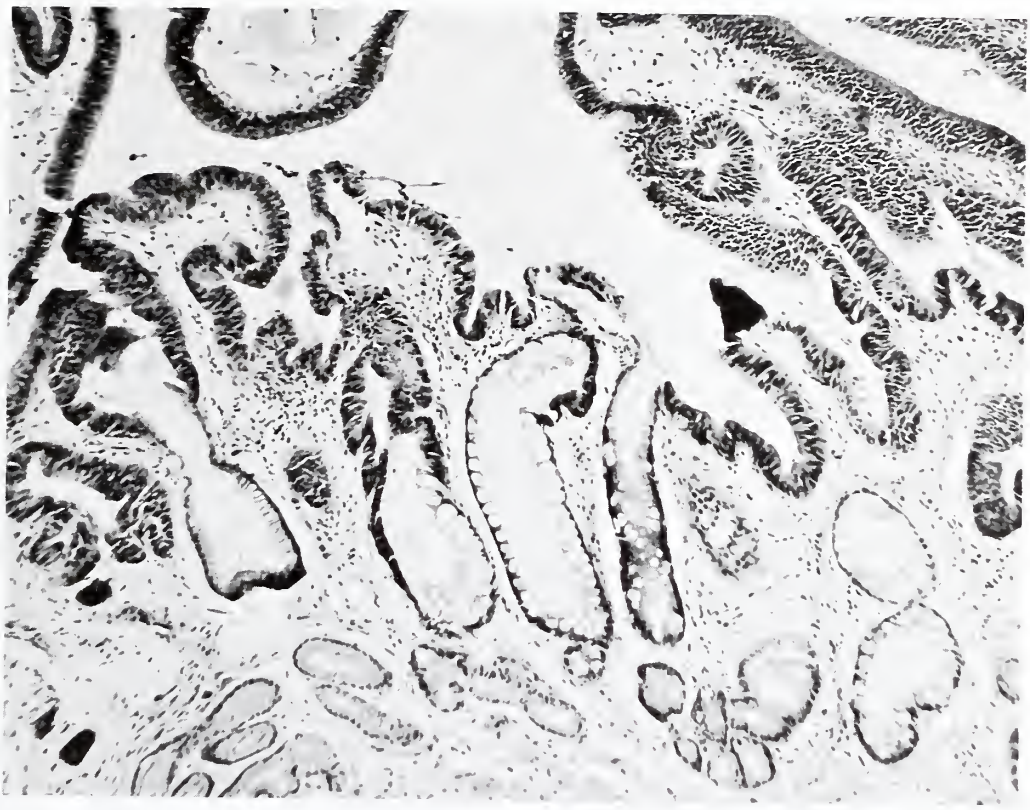

Fig. 121

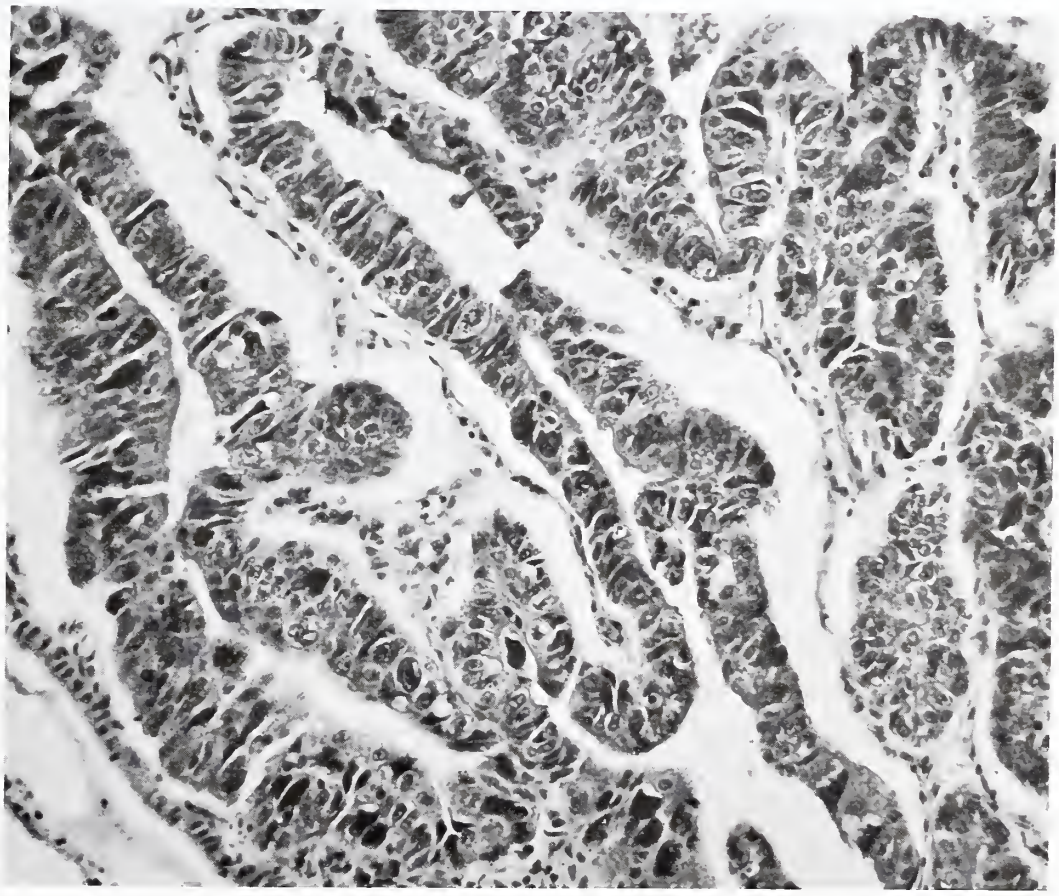

Fig. 122

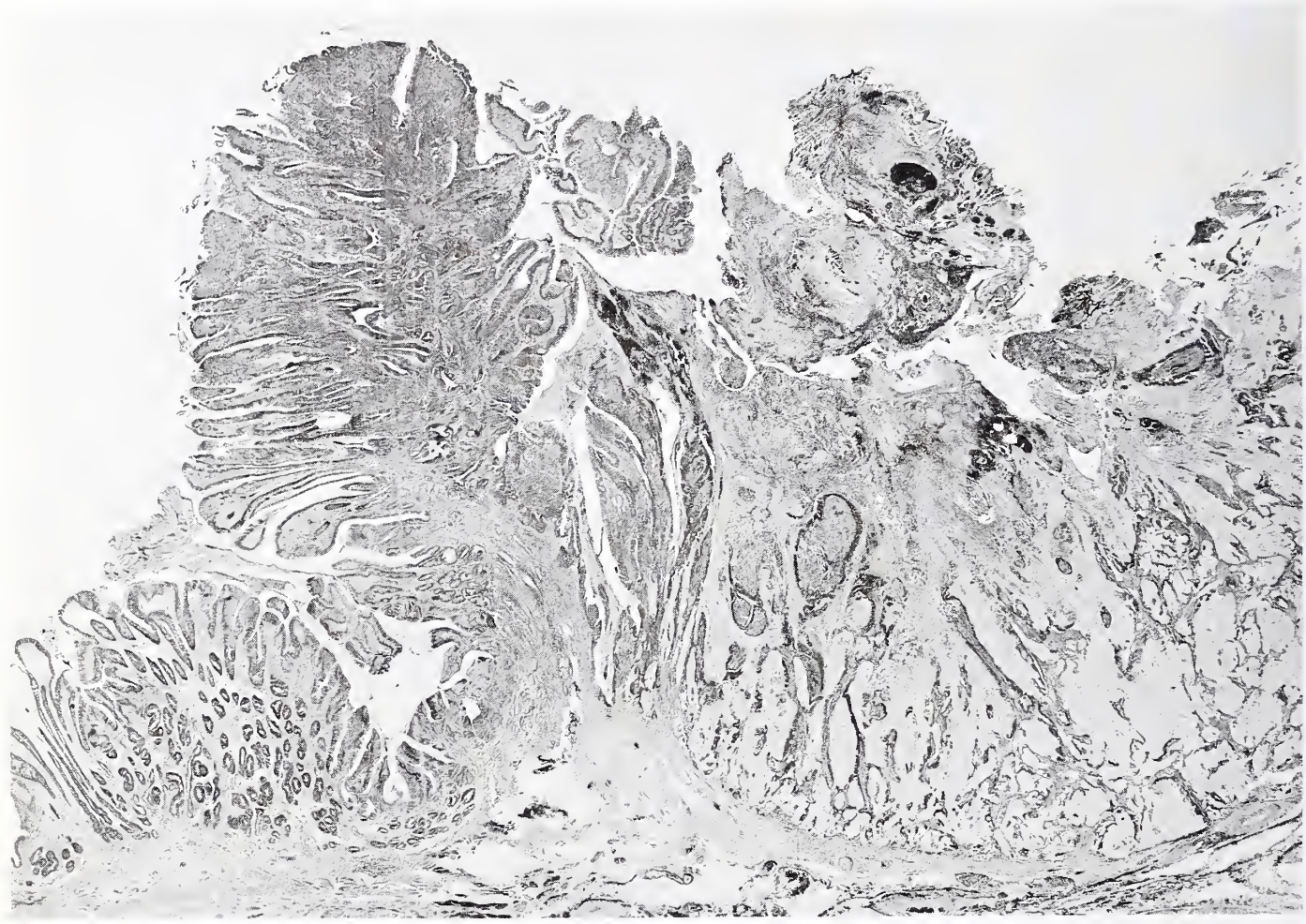

Fig 123

PAPILLARY ADENOMA WITH CARCINOMA

This photomicrograph of a tumor, removed from the pyloric antrum of a 64-year-old man, shows the remnant of a papillary adenoma on the left; it continues to the right with a mucinous carcinoma that extends through the muscularis mucosae. × 13. (Courtesy of Beth Israel Hospital, Boston, Mass.)

FAMILIAL POLYPOSIS

Boley and associates reported multiple gastric and colonic polyps in two sisters, 11 and 16 years of age. Yonemoto and associates reported three patients with polyps in the entire gastrointestinal tract; two were siblings 9 and 10 years of age and one was an 11-year-old girl. Total colectomy was performed on these patients because of the known high incidence of malignancy associated with colonic polyposis. The gastric lesions were treated conservatively since biopsies had disclosed only hyperplastic changes without evidence of malignancy. The malignant potential of these gastric polyps is unknown. Gastric polyps also occur in other genetically controlled conditions. In Peutz-Jeghers syndrome, gastrointestinal polyposis is accompanied by mucocutaneous pigmentation. The polyps in this syndrome are hamartomatous in their histologic appearance; further discussion appears in the next section. In Gardner's syndrome, gastrointestinal polyps are associated with osseous and soft tissue tumors. Most of the polyps reported were in the intestines, and carcinoma of colon and rectum was relatively frequent (Shiffman). Gastric polyps have also been reported (Yaffee). Of 51 members

of one family first studied by Gardner and Richards, 13 had died, five with carcinoma of the colon or rectum and one with carcinoma of the stomach. In Cronkhite-Canada syndrome, there was diffuse polyposis in the gastrointestinal tract and ectodermal changes, including hyperpigmentation of skin, alopecia, and onychatrophia (Jarnun and Jensen). Histologic features of polyps in these latter syndromes have not been adequately reported.

HAMARTOMATOUS POLYP

These polyps are composed not only of epithelial elements but also bundles of smooth muscle cells. The best known examples are the polyps in **Peutz-Jeghers syndrome.** Of 182 cases of this syndrome reviewed by Bartholomew and associates, polyps were present in the small intestine in 96 percent, colon in 29 percent, rectum in 30 percent, and stomach in 24 percent of cases. Gastric polyps are either sessile or pedunculated in this syndrome. The larger ones are often lobulated; each lobule shows a structure similar to that of the smaller polyps with hyperplastic mucous cells on the surface and normal appearing glands in the center (figs. 124, 125). Bundles of

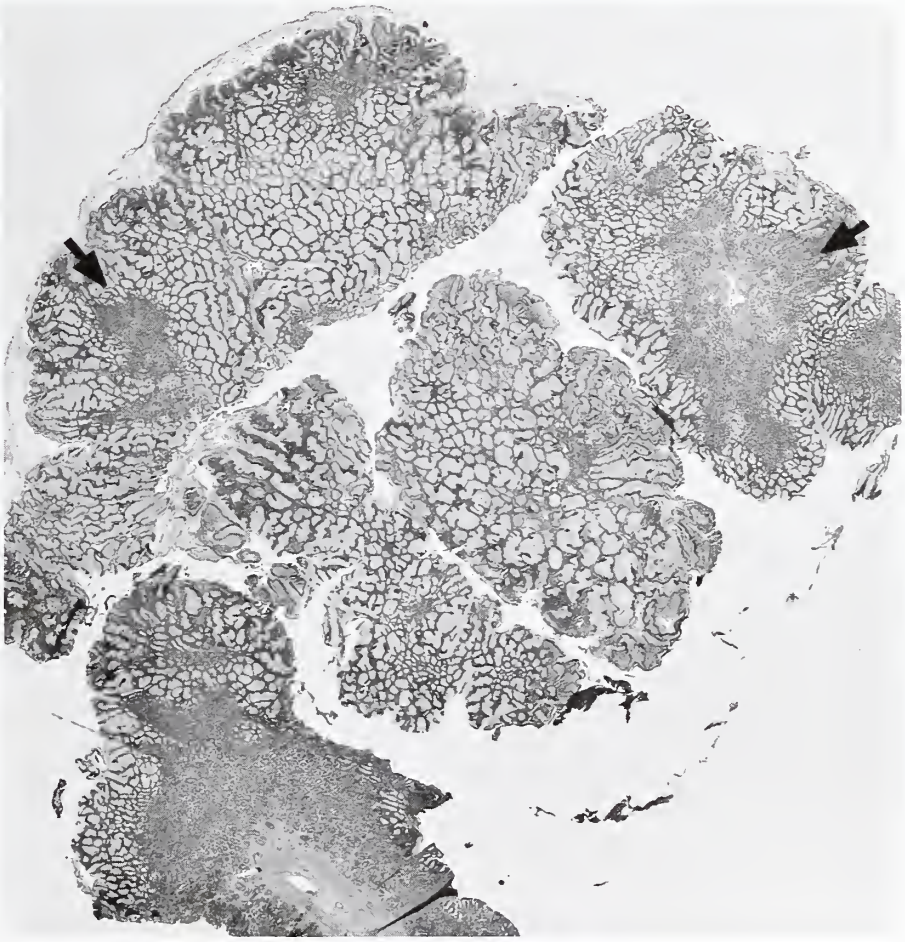

Fig. 124

HAMARTOMATOUS POLYP (PEUTZ-JEGHERS SYNDROME)

(Figures 124 – 126 from same case)

Eight polyps were removed from the stomach and intestine of a 16-year-old girl with Peutz-Jeghers syndrome: 2. gastric; 1. duodenal; 4. jejunal; and 1. ileal. This photomicrograph of the larger of the gastric polyps, measuring 1.5 cm. in diameter, reveals its lobular pattern, the prominent adenomatous hyperplasia of the foveolar cells, and the normal appearing glands in the solid portions at the center of the lobules (arrows). × 13. (Courtesy of Dr. R. C. Boylan, San Jose, Calif.)

smooth muscle extend from the muscularis mucosa at the base of the polyp into the lobules and between the glands (fig. 125). Polyps in the small intestine have a similar pattern, with prominent proliferating villi; they contain all the cellular elements normally present in the intestine (fig. 126). Many intestinal polyps were considered malignant because glandular elements present under bundles of muscularis were interpreted as invasion into the submucosa. This latter feature has now been recognized to be the result of participation of muscle in the formation of these polyps; no case with metastasis had been recorded when Rintala reviewed this problem in 1959. Subsequently, metastasizing carcinomas have been reported in the stomach and intestines (Olansky and Achord; Payson and Moumgis). Whether these carcinomas originated from the benign polyps or independently is not clear.

Fig. 125

HAMARTOMATOUS POLYP
(PEUTZ-JEGHERS SYNDROME)

(Figures 124 – 126 from same case)

A higher magnification of the same polyp (from area marked by arrow on right in figure 124) shows hypertrophic foveolar cells and normal glands in the center containing chief cells and parietal cells. Narrow bundles of muscle are present between the glands. × 134. (Courtesy of Dr. R. C. Boylan, San Jose, Calif.)

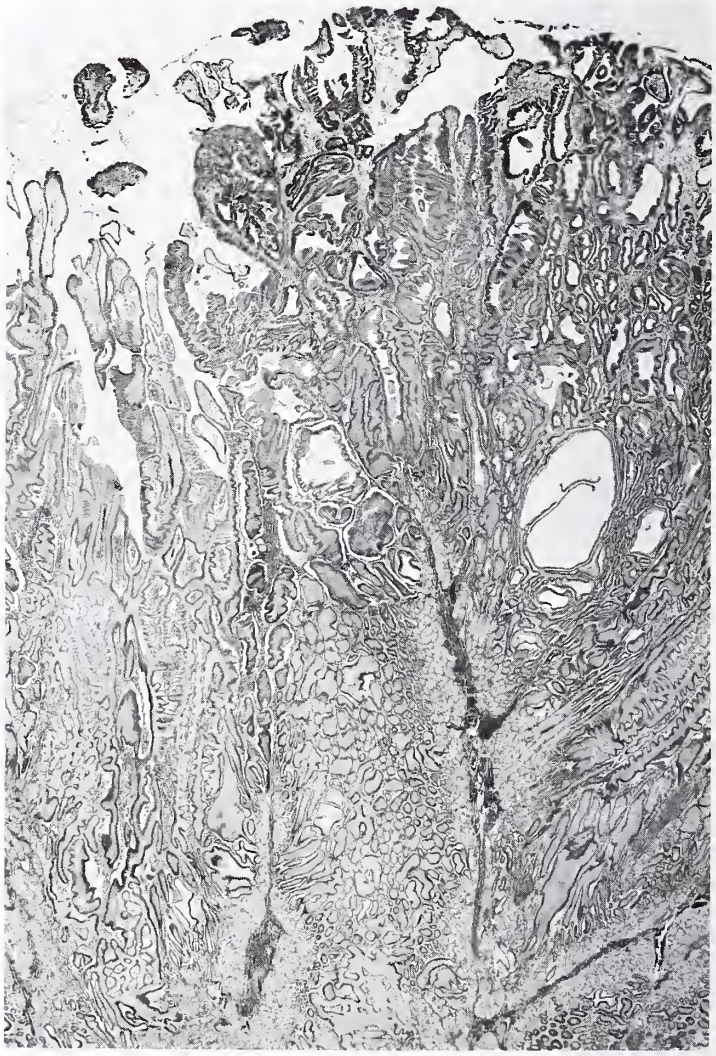

Fig. 126

HAMARTOMATOUS POLYP
(PEUTZ-JEGHERS SYNDROME)

(Figures 124 – 126 from same case)

This photomicrograph of a 5 cm. duodenal polyp, removed from the same girl, reveals marked hyperplasia of villi with focal cystic dilatation of the superficial portion of the glands. Many normal Brunner's glands are shown deep in the polyp. × 9.5 (Courtesy of Dr. R. C. Boylan, San Jose, Calif.)

HETEROTOPIC ADENOMATOUS POLYP

SYNONYMS AND RELATED TERMS. Brunner gland adenoma; ectopic pancreas; adenomyoma.

Heterotopic pancreas occasionally presents itself as a nipple-like projection above the mucosal surface; most lesions are intramural, however. **Adenomas of Brunner's glands** occur most frequently in the first portion of the duodenum, but some occur heterotopically at the pylorus or in the antrum of the stomach (fig. 127). They are composed of normal appearing Brunner's glands, forming masses separated by bands of smooth muscle fibers (fig. 128). Cystic areas may be found in these adenomas (Williams and Michie). Its histologic appearance is compatible with the hamartomatous nature of the lesion. It may be differentiated from the hamartomatous duodenal polyp of Peutz-Jeghers syndrome by the absence of prominent hyperplasia of the superficial mucosa.

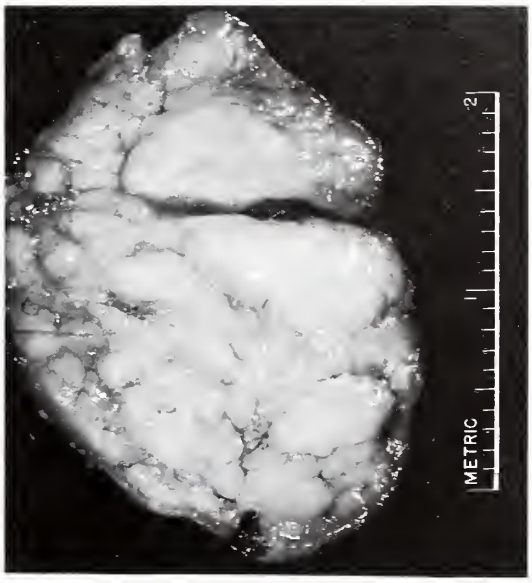

Fig. 127

HETEROTOPIC ADENOMATOUS POLYP (BRUNNER'S GLAND ADENOMA)

This photograph shows the nodular appearance of the cut surface of a bisected polypoid mass in the pylorus. It is covered by a thin mucosa, shown best at the lower border of the polyp. (Courtesy of The Massachusetts General Hospital, Boston, Mass.)

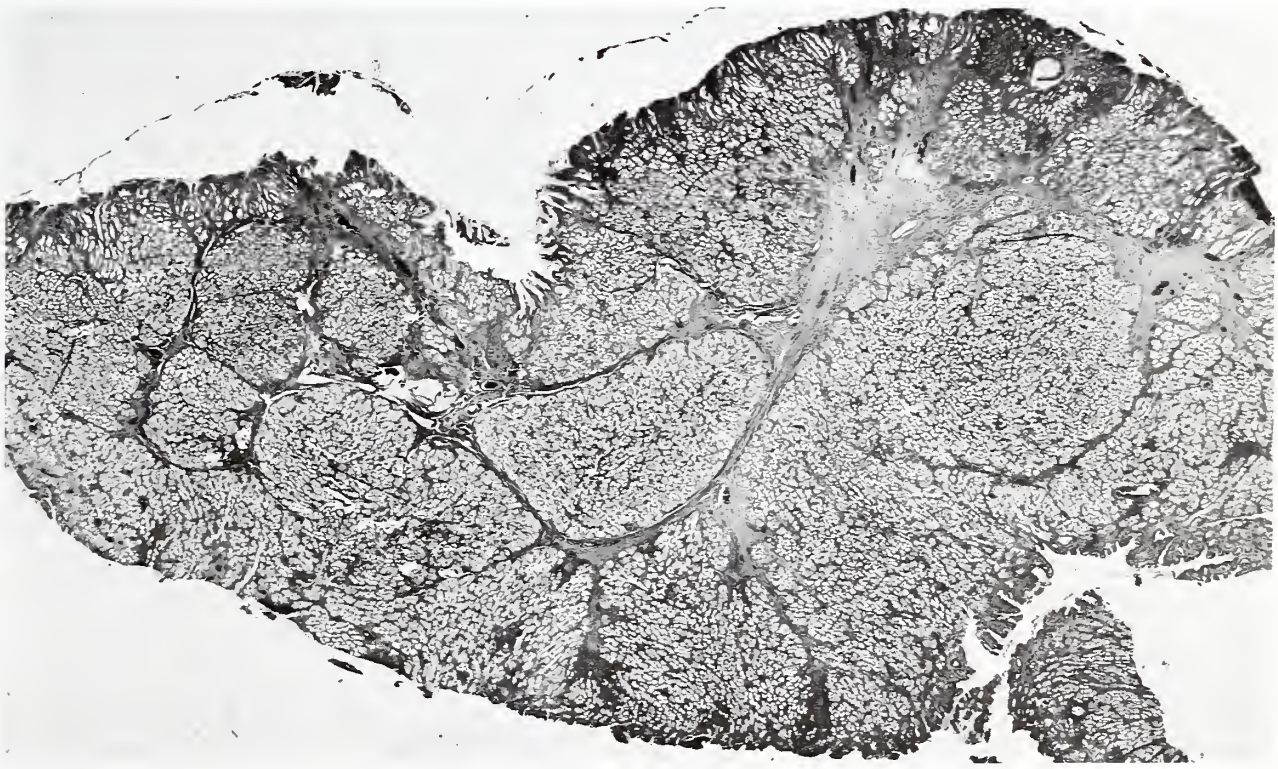

Fig. 128

HETEROTOPIC ADENOMATOUS POLYP (BRUNNER'S GLAND ADENOMA)

This photomicrograph of a 4.5 x 3.5 x 1.5 cm. polyp, found in the pyloric region of a 71-year-old man, shows masses of normal appearing Brunner's glands separated by bands of muscularis mucosae. × 7.4. (Courtesy of Beth Israel Hospital, Boston, Mass.)

MUCOSAL NODULE

Occasionally, a small sessile polyp simulates the histologic appearance of normal gastric mucosa. Its polypoid appearance is a result of atrophy of the surrounding mucosa. Thus, these nodules are really **pseudopolyps**. The superficial portions of mucosa in hyperplastic gastropathy may have a similar appearance. Examination of the whole thickness of the mucosa with muscularis mucosae present is essential in order to exclude the latter possibility.

RELATIONSHIP OF EPITHELIAL POLYPS TO CARCINOMA

Epithelial polyps of the stomach are rare. They are important nonetheless because of their close relationship to carcinoma. Many studies in the literature deal with this relationship and the opinions may be summarized as follows: (1) Gastric polyps are premalignant lesions with a high incidence of cellular atypism and frequent occurrence of carcinomatous changes within them; (2) the malignant potential of the polyps is correlated with the size and number of polyps; and (3) independent carcinomas occur frequently in the stomach with polyps.

Gastric carcinoma coexisting with polyp was present in 6 of 49 cases (12 percent) in Ming and Goldman's series, in 11 of 45 cases (24 percent) of Berg's series, in 4 of 24 cases (16 percent) at the University of Maryland Hospital (fig. 116), and in 35 percent of Tomasulo's series. These findings suggest that the gastric mucosa which gives rise to polyps is also suitable soil for development of carcinoma. The histologic abnormalities frequently present in such a mucosa support this view. The question of malignant transformation within a polyp is a different matter. Although many reports affirm this possibility, others such as Plachta and Speer found no evidence for it. Berg, and Monaco and associates studied this problem histologically. Berg found carcinoma in the polyp in 2 of 19 cases with single polyps, in 1 of 15 cases with multiple polyps, and in 4 of 11 cases which had independent carcinomas. Monaco and associates noted marked cellular atypism and changes compatible with carcinoma in situ in 10 percent of polyps larger than 2 cm. in diameter, but none of these changes were evident in the smaller polyps. The absence of metastasis in follow-up studies indicated a biologically benign course despite the morphologically malignant appearance. Ming and Goldman noted two distinctly different groups of polyps which might be readily differentiated from each other both grossly and histologically. These groups have been renamed hyperplastic adenomatous polyps and papillary adenomas. The former revealed no evidence of malignant potential and the latter showed carcinomatous changes in 40 percent of cases studied. A similar observation has been made by Tomasulo. It was also noted that most hyperplastic polyps and only a small number of papillary adenomas were less than 2 cm. in diameter, thus confirming the findings of others regarding the relationship between malignant potential and size of the polyps. This discrepancy in size suggests a difference in the area of initial development of these lesions, rather than progression from the hyperplastic polyp to papillary adenoma by progressive enlargement, since the former is stationary. It seems likely that papillary adenoma arises from a sizable field of gastric mucosa, probably multicentrically as noted above. It should be pointed out, however, that size alone should not be relied upon too heavily, since polypoid carcinomas may be small. A similar conclusion was reached by Marshak and Feldman based on gross morphologic features of polyps roentgenologically.

This classification of polyps may be readily applied to clinical practice. Hyperplastic adenomatous polyps once confirmed histologically may be treated conservatively by simple polypectomy,

whereas papillary adenomas require a more radical surgical approach, such as sleeve resection or partial gastrectomy because of the possibility of malignant changes in them. Furthermore, a widely excised specimen will allow detailed pathologic evaluation and if a focus of invasive carcinoma is present, lymph node dissection will be necessary. The gastric mucosa between the polyps must be examined carefully for coexisting but independent carcinoma. The role performed by frozen sectioning of the polyp also becomes clearer. What is important to recognize is not the presence of cellular atypism or carcinoma in situ in the polyp which by itself does not influence the outcome of the treatment (Monaco et al.; Tomasulo), but its histologic classification or overt malignancy. The initial goal of frozen section is to distinguish the adenoma from other types of polyps. If the lesion is an adenoma, then the entire lesion should be carefully examined for evidence of invasive carcinoma which determines the extent of surgical resection.

References

Bartholomew, L. G., Moore, C. E., Dahlin, D. C., and Waugh, J. M. Intestinal polyposis associated with mucocutaneous pigmentation. Surg. Gynec. Obstet. 115:1–11, 1962.

Berg, J. W. Histological aspects of the relation between gastric adenomatous polyps and gastric cancer. Cancer 11:1149–1155, 1958.

Boley, S. J., McKinnon, W. M. P., and Marzulli, V. F. The management of familial gastrointestinal polyposis involving stomach and colon. Surgery 50:691–696, 1961.

Bremer, E. H., Battaile, W. G., and Bulle, P. H. Villous tumors of the upper gastrointestinal tract. Clinical review and report of a case. Amer. J. Gastroent. 50:135–143, 1968.

Dedichen, H., and Helsingen, N., Jr. Polyposis ventriculi. Acta Chir. Scand. Suppl. 357:209–212, 1966.

Gardner, E. J., and Richards, R. C. Multiple cutaneous and subcutaneous lesions occurring simultaneously with hereditary polyposis and osteomatosis. Amer. J. Hum. Genet. 5:139–147, 1953.

Jarnun, S., and Jensen, H. Diffuse gastrointestinal polyposis with ectodermal changes. A case with severe malabsorption and enteric loss of plasma proteins and electrolytes. Gastroenterology 50:107–118, 1966.

Marshak, R. H., and Feldman, F. Gastric polyps. Amer. J. Dig. Dis. 10:909–935, 1965.

McNeer, G., Joly, D. J., and Berg, J. W. The Significance of Adenomatous Polyps, p. 56. In: McNeer, G., and Pack, G. T. Neoplasms of the Stomach. Philadelphia: J. B. Lippincott, 1967.

Ming, S.-C., and Goldman, H. Gastric polyps. A histogenetic classification and its relation to carcinoma. Cancer 18:721–726, 1965.

Monaco, A. P., Roth, S. I., Castleman, B., and Welch, C. E. Adenomatous polyps of the stomach. A clinical and pathological study of 153 cases. Cancer 15:456–467, 1962.

Olansky, S., and Achord, J. L. The problem of carcinoma in the Peutz-Jeghers syndrome. Southern Med. J. 62:827–829, 1969.

Payson, B. A., and Moumgis, B. Metastasizing carcinoma of the stomach in Peutz-Jeghers syndrome. Ann. Surg. 165:145–151, 1967.

Plachta, A., and Speer, F. D. Gastric polyps and their relationship to carcinoma of the stomach. Review of literature and report of 65 cases. Amer. J. Gastroent. 28:160–175, 1957.

Rintala, A. The histological appearance of gastrointestinal polyps in the Peutz-Jeghers syndrome. Acta Chir. Scand. 117:366–373, 1959.

Shauffer, I. A., and O'Connor, S. J. Villous tumor of the stomach. Radiology 86:734–735, 1966.

Shiffman, M. A. Familial multiple polyposis associated with soft-tissue and hard-tissue tumors. J.A.M.A. 179:514–522, 1962.

Tomasulo, J. Gastric polyps. Histologic types and their relationship to gastric carcinoma. Cancer 27:1346–1355, 1971.

Walk, L. Villous tumor of the stomach. Clinical review and report of two cases. Arch. Intern. Med. 87:560–569, 1951.

Williams, A. W., and Michie, W. Adenomatosis of the stomach of Brunner gland type. Brit. J. Surg. 45:259–263, 1957.

Yaffee, H. S. Gastric polyposis and soft tissue tumors. A variant of Gardner's syndrome. Arch. Derm. 89:806–808, 1964.

Yonemoto, R. H., Slayback, J. B., Byron, R. L., and Rosen, R. B. Familial polyposis of the entire gastrointestinal tract. Arch. Surg. 99:427–434, 1969.

MALIGNANT EPITHELIAL TUMORS

ADENOCARCINOMA

SYNONYMS AND RELATED TERMS: **Papillary adenocarcinoma; mucus producing adenocarcinoma; sclerosing adenocarcinoma;** scirrhous carcinoma, linitis plastica

Adenocarcinoma of the stomach often reveals the features of both the original gastric and metaplastic intestinal type cells. In either instance, mucous cells are the most important constituent. The role of intestinal metaplasia regarding the histogenetic process of gastric carcinoma has been much discussed. Recent studies, including ultrastructural and histochemical investigations, have made important contributions concerning this relationship, but have not resolved it satisfactorily. The etiology of gastric carcinoma is still unknown. Epidemiologic investigations in recent years have not yielded significant additions to our knowledge. New information is rapidly accumulating in the experimental field as the result of the discovery of a number of carcinogens which are effective on the gastric mucosa when given orally.

The major clinical problem remains one of early diagnosis because the occurrence of symptoms has not proved to be a reliable signal. Several possible reasons are suggested: Spaciousness of the organ permits the tumor to enlarge and penetrate before symptoms are manifest; the common occurrence of minor gastric discomfort blunts the alertness of the patient as well as the physician; the tumor may be located in a symptomatically silent area; and, finally, the degree of clinical manifestations does not necessarily indicate the extent of the disease. The relationship between the pathologic features of the tumor and the prognosis have been variously studied, but there is still need for a comprehensive clinical pathologic correlative study, particularly of the early stages in order to understand the biologic behavior of this tumor.

EPIDEMIOLOGY AND GEOGRAPHIC INCIDENCE. The incidence of gastric carcinomas in the general population and among all cancers in man varies greatly; it is particularly high in Japan, Chile, Finland, and Iceland, and very low in many parts of the African Continent (fig. 11). Haenszel, and Wynder and associates have made extensive reviews of the subject. The high incidence of gastric carcinoma among certain nationals tends to be maintained after emigration to other countries; thus, the Japanese in British Columbia (MacDonald) and Hawaii (Quisenberry) have a 2 to 3 times higher incidence of gastric carcinoma than other ethnic groups in these areas. That it has an environmental rather than genetic basis is shown by the decreasing incidence in the Japanese as they migrate further away from their homeland and in subsequent generations. In general, gastric carcinoma is more prevalent in areas of higher latitude. In the United States, a higher incidence was found in the northern states from North Dakota to Michigan. In some countries, it is more frequent in rural than urban areas. In the United States, the difference is not evident, possibly because of the large number of immigrants in the cities. Gastric carcinoma occurs more frequently in people of low socioeconomic status and in those with occupations requiring physical strength. Men are more often affected than women (fig. 129); the variance reaches its peak in the 55 to 65-year-old age group (Griffith). Unlike esophageal carcinoma, the sex difference of patients with gastric carcinoma in different countries varies only slightly. All the variations in incidence of gastric carcinoma mentioned above may be explained on the basis of dietary habits and total food intake. In the United States and many other countries, a continuing decreasing trend in incidence of gastric carcinoma is evident, particularly among women (fig. 130). Efforts to elicit the factors involved, such as the changing nature of foods consumed, have not been rewarding.

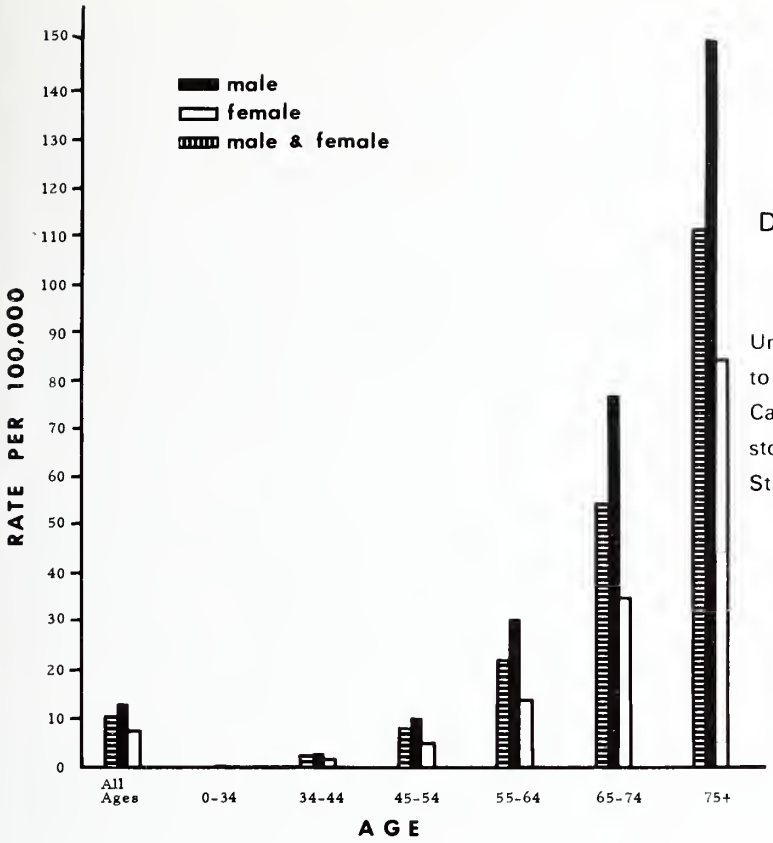

Fig. 129

Fig. 129

DEATH RATE DUE TO GASTRIC CARCINOMA ACCORDING TO SEX AND AGE

In this graph the death rate per 100,000 population in the United States due to gastric carcinoma is presented according to sex and age. (World Health Organization. 1963 data. Causes of death. Malignant neoplasms of oesophagus, of stomach, of intestine and of rectum. WHO Epidem. Vital Statist. Rep. 18:261–288, 1965.)

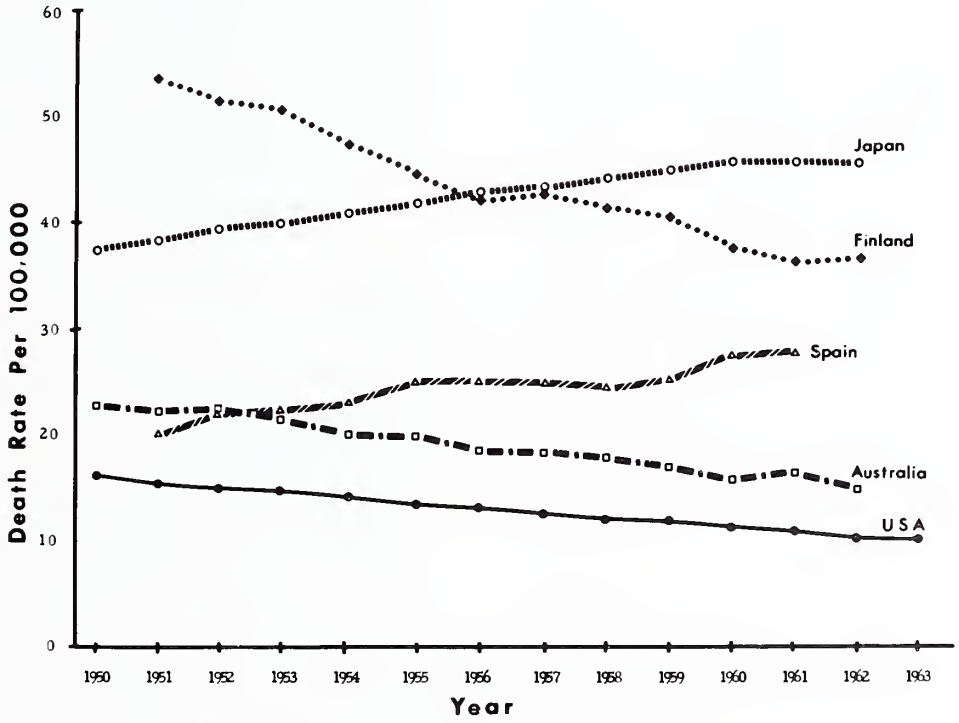

Fig. 130

DEATH RATE DUE TO GASTRIC CARCINOMA

In this graph the yearly crude death rate per 100,000 population is indicated for selected countries from 1950 to 1963. (World Health Organization. Causes of death. Malignant neoplasms of oesophagus, of stomach, of intestine and of rectum. WHO Epidem. Vital Statist. Rep. 18:261–288, 1965.)

References

Griffith, G. W. The sex ratio in gastric cancer and hypothetical considerations relative to aetiology. Brit. J. Cancer 22: 163–172, 1968.

Haenszel, W. Epidemiology of Gastric Cancer, p. 3. In: McNeer, G., and Pack, G. T. Neoplasms of the Stomach. Philadelphia. J. B. Lippincott, 1967.

MacDonald, W. C. Gastric cancer among the Japanese of British Columbia: dietary studies. Canad. Cancer Conf. 6:451–459, 1966.

Quisenberry, W. G. Cancer epidemiology in the Pacific areas. Acta Un. Int. Cancr. 20:763–767, 1964.

Sigurjonsson, J. Occupational variations in mortality from gastric cancer in relation to dietary differences. Brit. J. Cancer 21:651–656, 1967.

Stukonis, M., and Doll, R. Gastric cancer in man and physical activity at work. Int. J. Cancer 4:248–254, 1969.

World Health Organization. 1963 data. Causes of death. Malignant neoplasms of oesophagus, of stomach, of intestine and of rectum. WHO Epidem. Vital Statist. Rep. 18:261–288, 1965.

Wynder, E. L., Kmet, J., Dungal, N., and Segi, M. An epidemiological investigation of gastric cancer. Cancer 16: 1461–1496, 1963.

ETIOLOGIC FACTORS. Genetic control over the development of gastric carcinoma has been suggested by observations of increased incidence among close relatives (Macklin), but not in spouses (Woolf). On the other hand, there has been no noticeably high incidence of gastric carcinoma among monozygotic twins as compared with that among dizygotic twins (Hauge and Harvald). Additional evidence for genetic influence is found in a higher incidence of gastric carcinoma in patients with blood group A than those with other blood groups; however, that difference is small as pointed out in many studies (McConnell). Thus, genetic factors appear to play only a minor role; more importance has been attributed to exogenous factors. Some factors, such as tobacco and alcohol, which are considered important in esophageal carcinogenesis, have not been found significant in gastric carcinogenesis. The soil in regions showing a high incidence of gastric carcinoma is low in limestone and high in organic substances, such as peat in Wales and the Netherlands (Wynder et al.). Soil conditions, which might contribute to the high incidence of esophageal carcinoma in the Transkei region of South Africa, are apparently insignificant for the stomach because the incidence of gastric carcinoma there is very low.

The most significant exogenous factors in gastric carcinogenesis are probably related to dietary habits. The nature of foodstuffs rather than its temperature, spicy ingredients, or methods of cooking has been correlated with the prevalence of gastric carcinoma. Wynder and associates reported that patients with this disease have a high intake of starchy foods, such as rice and potatoes, and a low intake of fresh fruits and vegetables. In Iceland, the high incidence of gastric carcinoma has been related to the use of smoked foods; when rats were fed this type of food, tumors were produced in various organs, but not in the stomach (Dungal). The carcinogenic property of smoked food has been attributed to the presence of polycyclic hydrocarbons, particularly 3,4-benzpyrene, which were found to be higher in home-smoked than in commercially smoked foods (Thorsteinsson). Merliss noted significant amounts of asbestos fibers in talc and postulated that this contaminant might be related to the occurrence of gastric carcinoma in Japanese consuming the talc-treated rice. Whatever carcinogens are present in food, the amount consumed, in terms of total caloric intake, has been presumed to account for the difference in incidence of gastric carcinoma among persons of different sex, age, occupation, and economic status in the same population. Also suggested as a higher risk factor is the possible relationship with the use of purgatives (Graham et al.).

References

Dungal, N. The special problem of stomach cancer in Iceland. With particular reference to dietary factors. J.A.M.A. 178:789–798, 1961.

———. Stomach cancer in Iceland. Canad. Cancer Conf. 6:441–449, 1966.

Graham, S., Lilienfeld, A. M., and Tidings, J. E. Dietary and purgation factors in the epidemiology of gastric cancer. Cancer 20: 2224–2234, 1967.

Hauge, M., and Harvald, B. Malignant growth in twins. Acta Genet. 11: 372–378, 1961.

Macklin, M. T. Inheritance of cancer of the stomach and large intestine in man. J. Nat. Cancer Inst. 24:551–571, 1960.

McConnell, R. B. The Genetics of Gastrointestinal Disorders. p. 50. London, New York. Oxford University Press, 1966.

Merliss, R. R. Talc-treated rice and Japanese stomach cancer. Science 173: 1141–1142, 1971.

Thorsteinsson, T. Polycyclic hydrocarbons in commercially and home-smoked food in Iceland. Cancer 23:455–457, 1969.

Woolf, C. M. The incidence of cancer in the spouses of stomach cancer patients. Cancer 14: 199–200, 1961.

Wynder, E. L., Kmet, J., Dungal, N., and Segi, M. An epidemiological investigation of gastric cancer. Cancer 16: 1461–1496, 1963.

EXPERIMENTAL CARCINOGENESIS. Adenocarcinomas of the stomach are rare in animals. Oettlé noted an infiltrating and metastasizing epithelial tumor occurring with high frequency in a laboratory colony of *Rattus (Mastomys) natalensis* in South Africa. The tumors were classified as adenocarcinomas until recently when Snell and Stewart demonstrated argyrophil granules in the tumor cells. Although argentaffin granules were not found, the tumor is now considered a carcinoid. Previously, oral administration of most carcinogens had resulted in the induction of carcinoma in the alimentary tract except for the glandular portion of the stomach. Howes and de Oliveira, in 1948, produced adenomatous lesions in the stomach of the rat by implantation of threads impregnated with 20-methylcholanthrene within the gastric wall. Some of the lesions were interpreted as adenocarcinoma. Hare, and Stewart and their colleagues induced similar lesions in the stomach of the rat by injecting an aqueous suspension of 20-methylcholanthrene into the submucosa of the stomach. The adenomatous proliferation often had the gross appearance of an umbilicated lesion or a diverticulum. These lesions were considered precancerous. These investigators accepted as carcinomas only those lesions showing penetration of glandular elements through the entire gastric wall, and this was a rare occurrence. This criterion of experimental gastric malignancy has been accepted by most investigators. A breakthrough in experimental gastric carcinogenesis was made in 1961 when Stewart and associates reported adenocarcinomas in the stomachs of four and precancerous lesions in the stomachs of 23 of 47 autopsied rats which had been fed N,N'-2,7-fluorenylene-bisacetamide.

In recent years, a number of carcinogens have been used to induce adenocarcinomas in the glandular stomachs of rats, mice, and other animals by either an intramural implantation or by feeding in the diet or drinking water or through a tube. Japanese researchers have been particularly active in these investigations. Carcinogens which have been effective include 7,12-dimethylbenz(a)-anthrace (Grant), N-methyl-N'-nitro-N-nitroso-guanidine (Sugimura et al.), acetyl-methylnitro-sourea (Druckrey et al.), and 4-nitroquinoline 1-oxide and its related substances (Mori et al.). Majima and associates implanted 4-nitroquinoline 1-oxide in a beeswax pellet to induce an ulcer prior to the development of carcinoma. Some chemicals, such as N-nitroso-N-alkylurethanes, produced squamous cell carcinomas of the esophagus and forestomach and adenomatous lesions of the glandular stomach without invasion (Schoental). The combined implantation and oral administration of carcinogens was found to be more effective in inducing gastric lesions in rats than each method alone (Odashima). The carcinogenic substances of fungal origin, such as aflatoxin (Butler and Barnes) and elaiomycin (Schoental), and ionizing radiation, given either as whole body or local radiation (Hirose; Nowell et al.; Upton et al.), have also been used to induce gastric tumors. While most investigators adhere to Stewart and associates' criteria of carcinoma based on invasiveness, some researchers such as Mori and

associates and Saito and associates relied on cellular atypism. Stewart (1971) questioned the reliability of the latter approach since atypical gastric glands were common in experimental animals and did not necessarily imply neoplasia. Another difficulty often encountered in experimental animals is the induction of malignant tumors in other organs which cause death of the animal before the biologic behavior of gastric tumors is fully manifested. Recently, Druckrey and associates produced exclusively gastric adenocarcinoma in rats fed a low dose of acetylmethylnitrosourea. Such experiments will allow adequate study of the biologic potential of gastric tumors. Examples of experimentally produced adenocarcinomas in the stomach of the rat are illustrated in figures 131 through 134.

Experimental carcinoma of the glandular stomach occurs chiefly in the pyloric portion. The acid-secreting mucosa is resistant to carcinogenic stimulation, even when the carcinogen is implanted in its vicinity, as noted by Hare and his coworkers. Stewart and associates observed the absence of chronic gastritis, intestinalization, ulcer, or polyp formation in the initial stages when the stomach of the mouse was injected with 20-methylcholanthrene. Recent studies employing chemical carcinogens or ionizing radiation noted

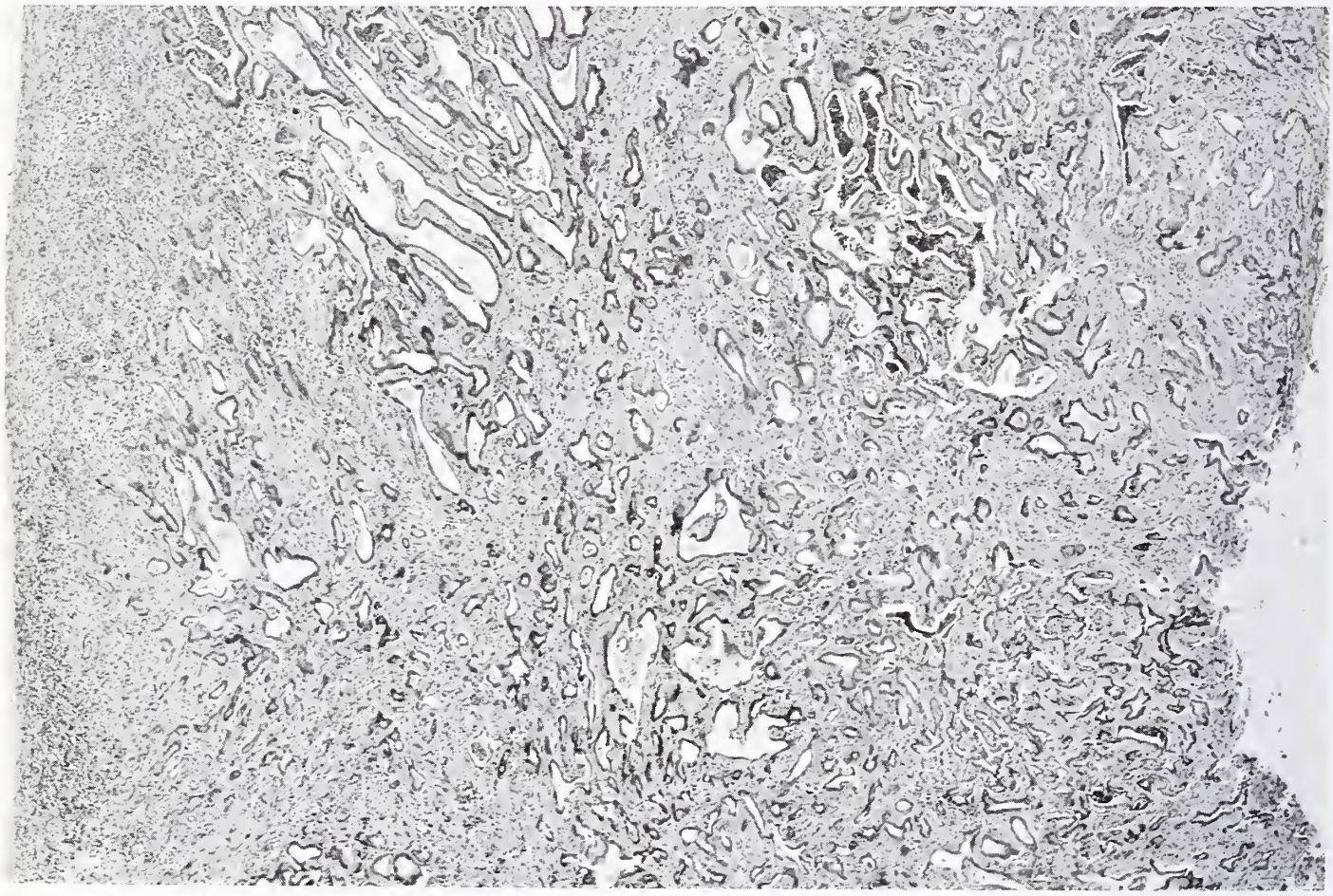

Fig. 131

EXPERIMENTAL ADENOCARCINOMA

This adenocarcinoma is from the fundic portion of the glandular stomach of a rat fed a diet containing 0.025% N,N'-2,7-fluorenylenebisacetamide. The tumor involved the whole thickness of the gastric wall. × 44. (Courtesy of Dr. K. C. Snell, Bethesda, Md.)

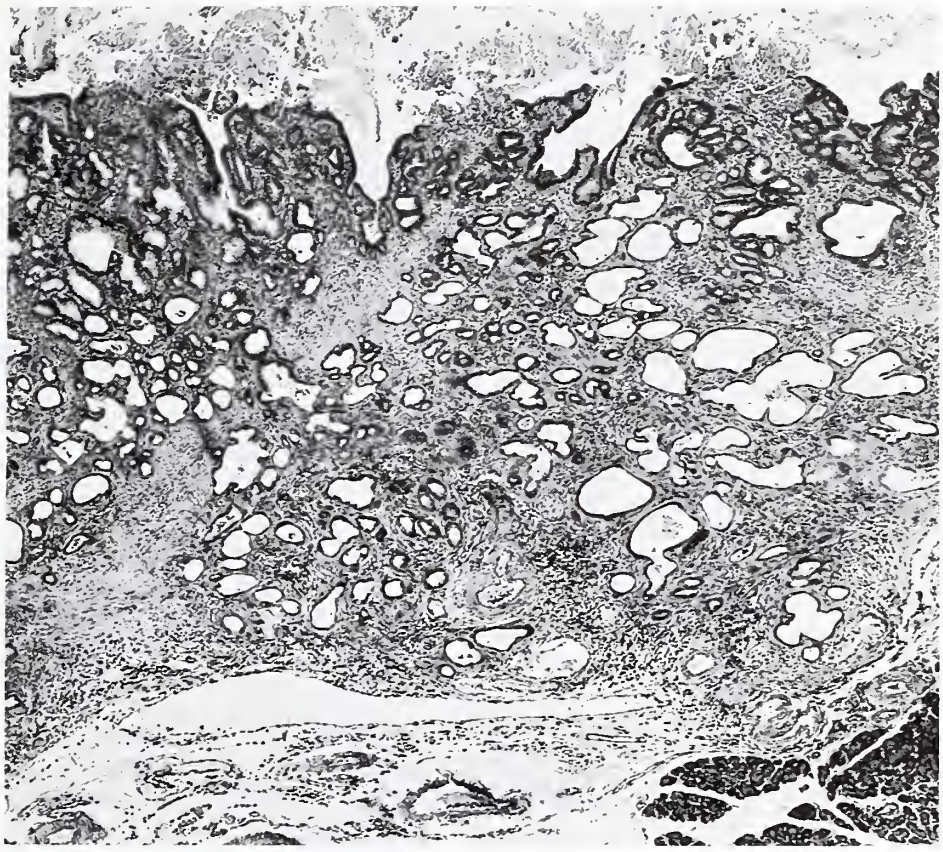

Fig. 132

EXPERIMENTAL ADENOCARCINOMA

This adenocarcinoma involved the pyloric antrum of a rat fed a diet containing 0.025% N,N'-2,7-fluorenylenebisacetamide. The tumor extends to the peripancreatic tissue (lower right). It is composed of well formed glands, many of which are dilated. × 44 (Courtesy of Dr. K. C. Snell, Bethesda, Md.)

Fig. 133

EXPERIMENTAL ADENOCARCINOMA

This is the anterior coronal section of the stomach from a rat given 83 ug/ml of N-methyl-N'-nitro-N-nitrosoguanidine in drinking water for seven months, and killed nine months after discontinuation of the carcinogen. The tumor is in the antrum along both the lesser and greater curvatures. The duodenum is shown on the right. (Courtesy of Dr. Takashi Sugimura, Tokyo, Japan; also pl. IV(7) from Sugimura, T., Fujimura, S., Kogure, K., Baba, T., Saito, T., Nagao, M., Hosoi, H., Shimosato, Y., and Yokoshima, T. Production of adenocarcinomas in glandular stomach of experimental animals by N-methyl-N'-nitro-N-nitrosoguanidine. Gann Monograph 8 157–196, 1969.)

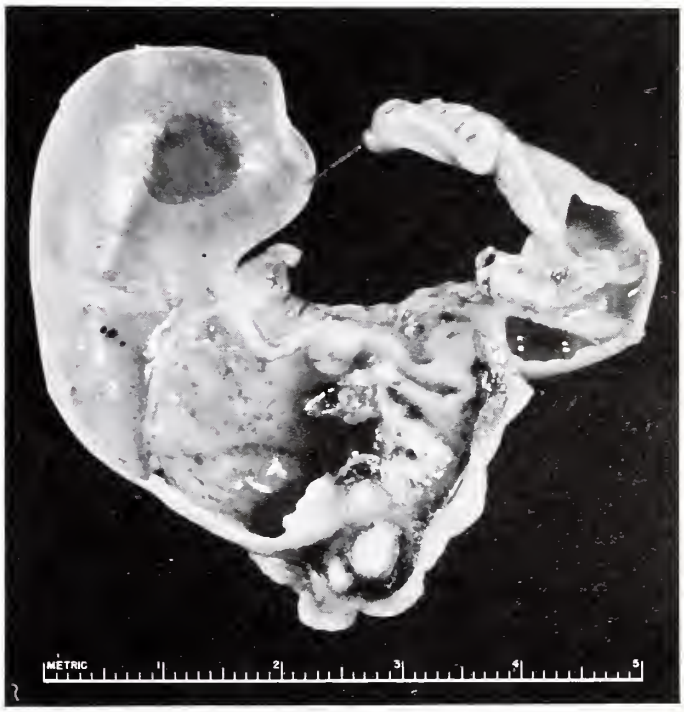

Fig. 133

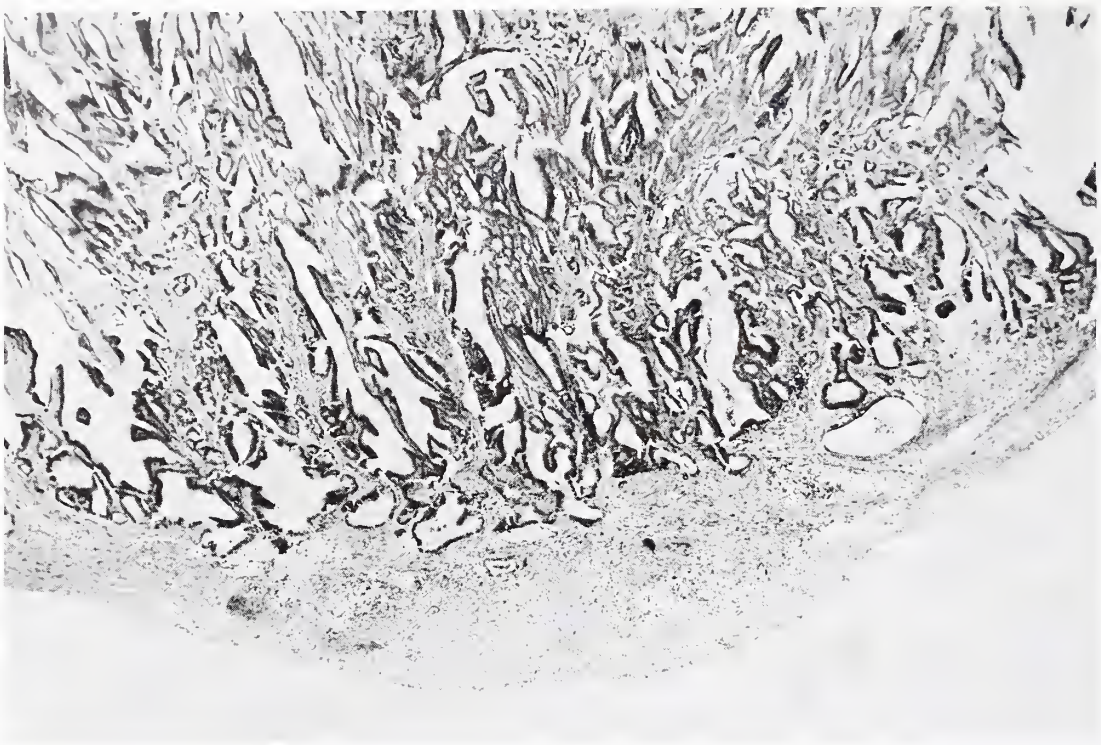

Fig. 134

EXPERIMENTAL ADENOCARCINOMA

This well differentiated adenocarcinoma was found in the glandular stomach of a rat that died on the 388th day of continuous administration of N-methyl-N'-nitro-N-nitrosoguanidine in drinking water. The tumor extends to the subserosa (Courtesy of Dr. Takashi Sugimura, Tokyo, Japan; also pl. I(2) from Sugimura, T., Fujimura, S., Kogure, K., Baba, T., Saito, T., Nagao, M., Hosoi, H., Shimosato, Y., and Yokoshima, T. Production of adenocarcinomas in glandular stomach of experimental animals by N-methyl-N'-nitro-N-nitrosoguanidine. Gann Monograph 8:157–196, 1969.)

that the gastric mucosa exhibited marked atrophy, followed by erosion and reparative hyperplasia before the development of carcinoma. Epithelial hyperplasia appeared to be the most important step preceding carcinoma formation. The marginal epithelium of an ulcer responded to the carcinogen in a similar fashion (Majima et al.). The presence of an ulcer had no effect on the carcinogenesis when the carcinogen was administered orally (Nagayo). Kowalewski and Kasper induced mucosal atrophy and achlorhydria by an anticholinergic drug and found an increased incidence of gastric carcinoma induced by 20-methylcholanthrene in rats but not in mice and hamsters. In most experiments, intestinal metaplasia has been found in the precancerous stages.

References

Butler, W. H., and Barnes, J. M. Carcinoma of the glandular stomach in rats given diets containing aflatoxin. Nature 209:90, 1966.

Druckrey, H., Ivankovic, S., and Preussmann, R. Selektive Erzeugung von Carcinomen des Drüsenmagens bei Ratten durch orale Gabe von N-methyl-N-nitroso-N'-acetylharnstoff (AcMNH). Z. Krebsforsch. 75:23–33, 1970.

Grant, R. Cancer induction in the glandular stomach of rats at sites of implanted 7,12-dimethylbenz(a)anthrace. J. Nat. Cancer Inst. 37:353–364, 1966.

Hare, W. V., Stewart, H. L., Bennett, J. G., and Lorenz, E. Tumors of the glandular stomach induced in rats by intramural injection of 20-methylcholanthrene. J. Nat. Cancer Inst. 12:1019–1055, 1952.

Hirose, F. Induction of gastric adenocarcinoma in mice by localized x-irradiation. Gann 60:253–260, 1969.

Howes, E. L., and de Oliveira, J. R. Early changes in experimentally produced adenomas and adenocarcinomas of the stomach. Cancer Res. 8:419–427, 1948.

Kowalewski, K., and Kasper, T. Achlorhydria, gastric mucosal atrophy and gastric neoplastic lesions in rats, mice and hamsters treated with an anticholinergic drug, propantheline bromide and a carcinogen, 20-methylcholanthrene. Canad J. Surg. 10:99–108, 1967.

Majima, S., Takahashi, T., Yoshida, K., Karube, K., Machida, T., Narisawa, T., Hoshi, H., Hiroki, T., Ito, K., and Kurata, Y. Atypical epithelial proliferation in the course of experimental production of ulcer-carcinoma of the stomach. Tohoku J. Exp. Med. 93:363–376, 1967.

Mori, K., Ota, A., Murakami, T., Tamura, M., and Kondo, M. Carcinomas of the glandular stomach and other organs of rats induced by 4-hydroxyaminoquinoline 1-oxide hydrochloride. Gann 60:627–630, 1969.

Nagayo, T. Effect of oral administration of N,N'-2,7-Fluorenylenebisacetamide combined with traumatic ulcers of the glandular stomach of Buffalo rats. J. Nat. Cancer Inst. 35:829–840, 1965.

Nowell, P. C., Cole, L. J., and Ellis, M. E. Neoplasms of the glandular stomach in mice irradiated with x-rays or fast neutrons. Cancer Res. 18:257–260, 1958.

Odashima, S. Experimental carcinoma of the glandular stomach in rats. I. Effect of 7,12-dimethylbenz(a)anthracene or 4-nitroquinoline 1-oxide placed on glandular stomach combined with oral administration of N,-N'-(2,7-fluorenylene) bisacetamide or n-nitrosodiethylamine. Gann 60:211–222, 1969.

Oettlé, A. G. Spontaneous carcinoma of the glandular stomach in Rattus (Mastomys) natalensis, an African rodent. Brit. J. Cancer 11:415–433, 1957.

Saito, T., Inokuchi, K., Takayama, S., and Sugimura, T. Sequential morphological changes in N-methyl-N'-nitro-N-nitrosoguanidine carcinogenesis in the glandular stomach of rats. J. Nat. Cancer Inst. 44:769–783, 1970.

Schoental, R. Induction of tumours of the stomach in rats and mice by N-nitroso-N-alkylurethanes. Nature 199:190, 1963.

———. Carcinogenic action of Elaiomycin in rats. Nature 221:765–766, 1969.

Snell, K. C., and Stewart, H. L. Malignant argyrophilic gastric carcinoids of Praomys (Mastomys) natalensis. Science 163:470, 1969.

———, Stewart, H. L., and Morris, H. P. The sequential development of atrophy, precancerous lesions, and cancer of the glandular stomach and other organs and tissues of rats ingesting N,N'-2,7-fluorenylenebisacetamide. Gann Monograph 8:125–142, 1969.

Stewart, H. L. Experimentally induced gastric adenocarcinomas. Maude Abbott Lecture, 1971. Lab Invest. 25:672–674, 1971.

———, Snell, K. C., and Hare, W. V. Histopathogenesis of carcinoma induced in the glandular stomach of C57BL mice by the intramural injection of 20-methylcholanthrene. J. Nat. Cancer Inst. 21:999–1035, 1958.

———, Snell, K. C., Morris, H. P., Wagner, B. P., and Ray, F. E. Carcinoma of the glandular stomach of rats ingesting N,N'-2,7-fluorenylenebisacetamide. Nat. Cancer Inst. Monogr. 5:105–139, 1961.

Sugimura, T., Fujimura, S., and Baba, T. Tumor production in the glandular stomach and alimentary tract of the rat by N-methyl-N'-nitro-N-nitrosoguanidine. Cancer Res. 30:455–465, 1970.

Upton, A. C., Cosgrove, G. E., and Lushbaugh, C. C. Induction of carcinoma of the glandular stomach in mice by whole-body irradiation. Gann Monograph 8:63–74, 1969.

ASSOCIATED LESIONS. Gastric carcinoma occurs primarily in older people in whom abnormalities are common in the stomach. There are often varying degrees of mucosal atrophy, intestinal metaplasia, and chronic interstitial inflammation. Furthermore, these changes are more pronounced in the gastric mucosa with accompanying carcinoma than with other diseases. Thus, the status of the gastric mucosa appears to play an important role. Gastric lesions which have been associated with carcinoma and considered by some to be premalignant include: mucosal atrophy and intestinal metaplasia in chronic atrophic gastritis and pernicious anemia; mucosal hyperplasia in hypertrophic gastropathy; peptic ulceration; and adenomatous polyps. The relationship between the polyp and carcinoma has already been discussed on pages 142 – 143. The role of other lesions is explored below.

Mucosal Atrophy and Intestinal Metaplasia. Mucosal atrophy of the stomach is a common phenomenon. In the general population, it occurs mainly in the pyloric mucosa, especially along the lesser curvature; it is usually associated with chronic inflammation in the lamina propria. When atrophy is severe and the fundic mucosa is

involved, the loss of acid and enzyme-secreting cells results in achlorhydria. This latter phenomenon is particularly prominent in pernicious anemia. There have been many reports concerning the relationship between mucosal atrophy and carcinoma in the stomach. Those favoring a positive relationship based their opinion on the findings that atrophic gastritis is commonly associated with carcinoma and that carcinoma occurs more frequently in stomachs with atrophic mucosa (Hitchcock et al.; Siurala and Seppälä). Other investigators noted the increasing incidence of mucosal atrophy with age and found no causal relationship to carcinoma (Guiss and Stewart; Stout). The most prominent morphologic characteristic of atrophic mucosa is the presence of intestinalized glands. Features which are prominent in metaplastic glands, such as striated borders, acid mucin, and goblet cells, have been used as evaluators of mucosal atrophy and intestinal metaplasia in gastric carcinogenesis. Järvi and Laurén noted the presence of striated borders on gastric carcinoma cells and Morson found some tumors occurring in metaplastic areas. Recent investigations using histochemical and ultrastructural technics have demonstrated that many carcinoma cells have features of intestinal type cells (Ming et al.; Goldman and Ming; Stemmermann, 1967). The finding that carcinoma cells are metaplastic cells does not necessarily prove that such cells have developed from benign metaplastic cells in the atrophic mucosa. In fact, Stemmermann (1968) cited evidence to the contrary; namely, metaplastic areas were more closely associated with gastric ulcers than with carcinomas and did not always coincide with the tumors in their locations. Furthermore, in cases with diffuse infiltrative carcinoma, the gastric mucosa may be normal without significant atrophy or intestinal metaplasia, although the tumor cells are often goblet-shaped and secrete acid mucin. This type of carcinoma is also more common in the younger age group and in women (Eklund) in whom mucosal atrophy is not a prominent feature. From these observations, it appears possible that carcinoma cells may differentiate into intestinal type cells by themselves just as benign gastric cells may become metaplastic under injurious stimulation. While some carcinomas may develop in metaplastic mucosa as suggested by Morson, intestinal metaplasia in itself cannot be considered a premalignant condition and is not a prerequisite for carcinogenesis. Both atrophy and intestinal metaplasia are seen in gastric mucosa subjected to various injurious assaults, and carcinogens may cause these changes in animals as nonspecific injurious agents.

References

Eklund, A.-E. Studies on the relation between ABO blood groups and gastric carcinoma. I. Relation of blood groups to different types of tumour. Acta Chir. Scand. 129: 211–218, 1965.

Goldman, H., and Ming, S.-C. Mucins in normal and neoplastic gastrointestinal epithelium. Histochemical distribution. Arch. Path. 85: 580–586, 1968.

Guiss, L. W., and Stewart, F. W. Chronic atrophic gastritis and cancer of the stomach. Arch. Surg. 46:823–843, 1943.

Hitchcock, C. R., MacLean, L. D., and Sullivan, W. A. The secretory and clinical aspects of achlorhydria and gastric atrophy as precursors of gastric cancer. J. Nat. Cancer Inst. 18: 795–811, 1957.

Järvi, O., and Laurén, P. On the role of heterotopias of the intestinal epithelium in the pathogenesis of gastric cancer. Acta Path. Microbiol. Scand. 29:26–44, 1951.

Ming, S.-C., Goldman, H., and Freiman, D. G. Intestinal metaplasia and histogenesis of carcinoma in human stomach. Light and electron microscopic study. Cancer 20:1418–1429, 1967.

Morson, B. C. Carcinoma arising from areas of intestinal metaplasia in the gastric mucosa. Brit. J. Cancer 9: 377–385, 1955.

Siurala, M., and Seppälä, K. Atrophic gastritis as a possible precursor of gastric carcinoma and pernicious anemia. Results of follow-up examinations. Acta Med. Scand. 166: 455–474, 1960.

Stemmermann, G. N. Comparative study of histochemical patterns in non-neoplastic and neoplastic gastric epithelium: A study of Japanese in Hawaii. J. Nat. Cancer Inst. 39: 375–382, 1967.

——— and Hayashi, T. Intestinal metaplasia of the gastric mucosa. A gross and microscopic study of its distribution in various disease states. J. Nat. Cancer Inst. 41: 627–634, 1968.

Stout, A. P. Gastric mucosal atrophy and carcinoma of the stomach. New York J. Med. 45: 973–977, 1945.

Mucosal Hyperplasia. In 1888, Ménétrier reported two cases of gastric carcinoma; one was associated with multiple polyps and the other with diffuse mucosal hypertrophy, namely *polyadénome en nappe*. Since then, numerous reports have verified the first association, but few have dealt with the second condition. In 1964, Chusid and associates found only 12 cases in the literature showing carcinoma associated with mucosal hyperplasia, and reported one of their own. Moeller and associates recently reported another case. Schindler reviewed this subject in 1965 and reported five cases in detail. These were found among 273 cases of gastric carcinoma. One patient was a 67-year-old man with an extensive adenocarcinoma. The other four patients were 33, 23, 47, and 34 years of age, respectively; the tumors in all four patients were undifferentiated. One patient seen at the University of Maryland Hospital was a 20-year-old woman. The tumor was diffusely infiltrating an area measuring 15 by 12.5 cm., with an ulceration measuring 1 by 1 cm. in the fundic mucosa. The tumor cells were mostly undifferentiated or signet ring-shaped. The mucosa was thickened and varied from 1.5 to 4 mm. in depth (fig. 135). The hyperplastic glands were composed of normal fundic cells. There was neither inflammation nor intestinal metaplasia.

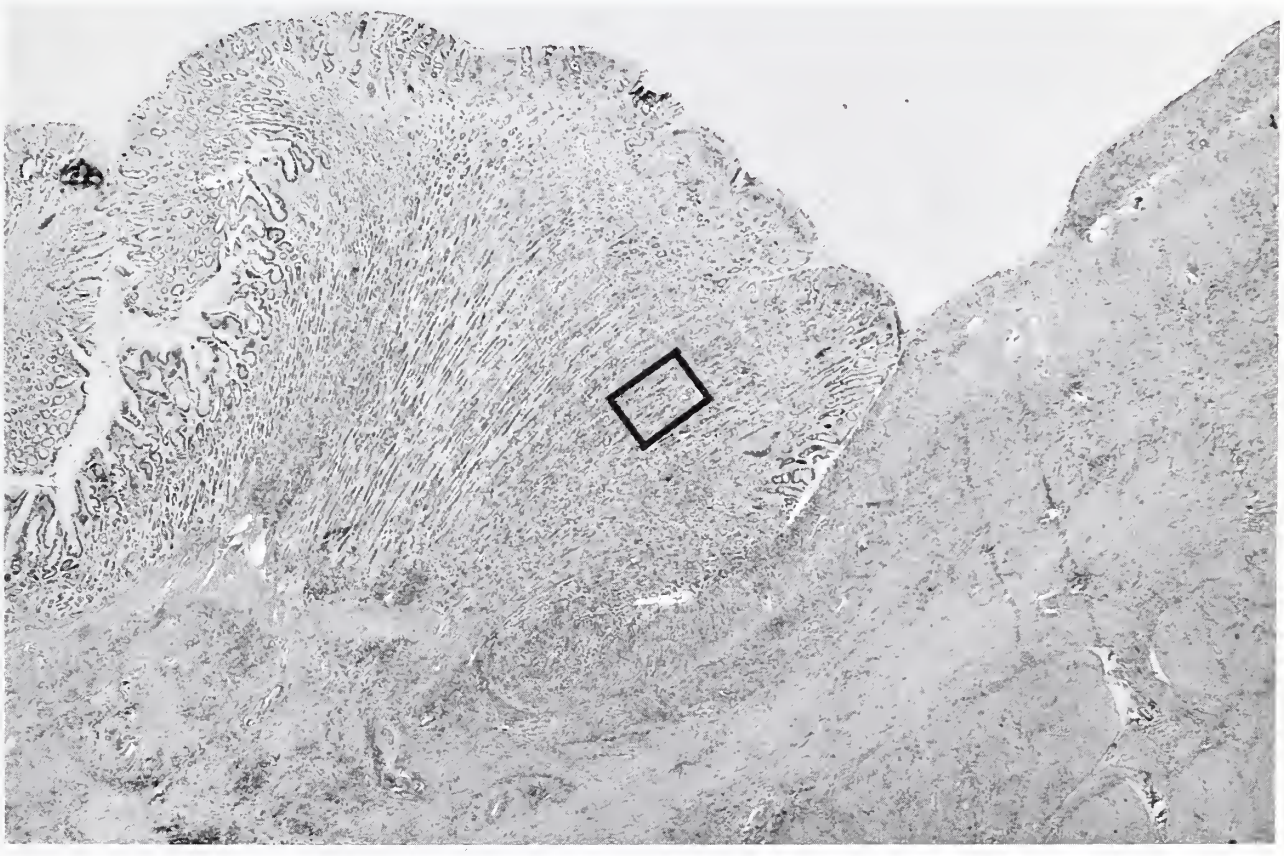

Fig. 135

CARCINOMA ASSOCIATED WITH MUCOSAL HYPERPLASIA

(Figures 135, 136, and 188 from same case)

This is a photomicrograph of the border of an ulcerated area in a diffusely infiltrative carcinoma in a 20-year-old woman. The mucosal fold next to the ulcer measured 4 mm. in thickness. The deep portion of the mucosa bordering on the ulcer was infiltrated by tumor cells. The markedly elongated glands shown in the midportion of the fold contain normal cellular constituents of the fundic glands. The area outlined is magnified in figure 136. × 15.

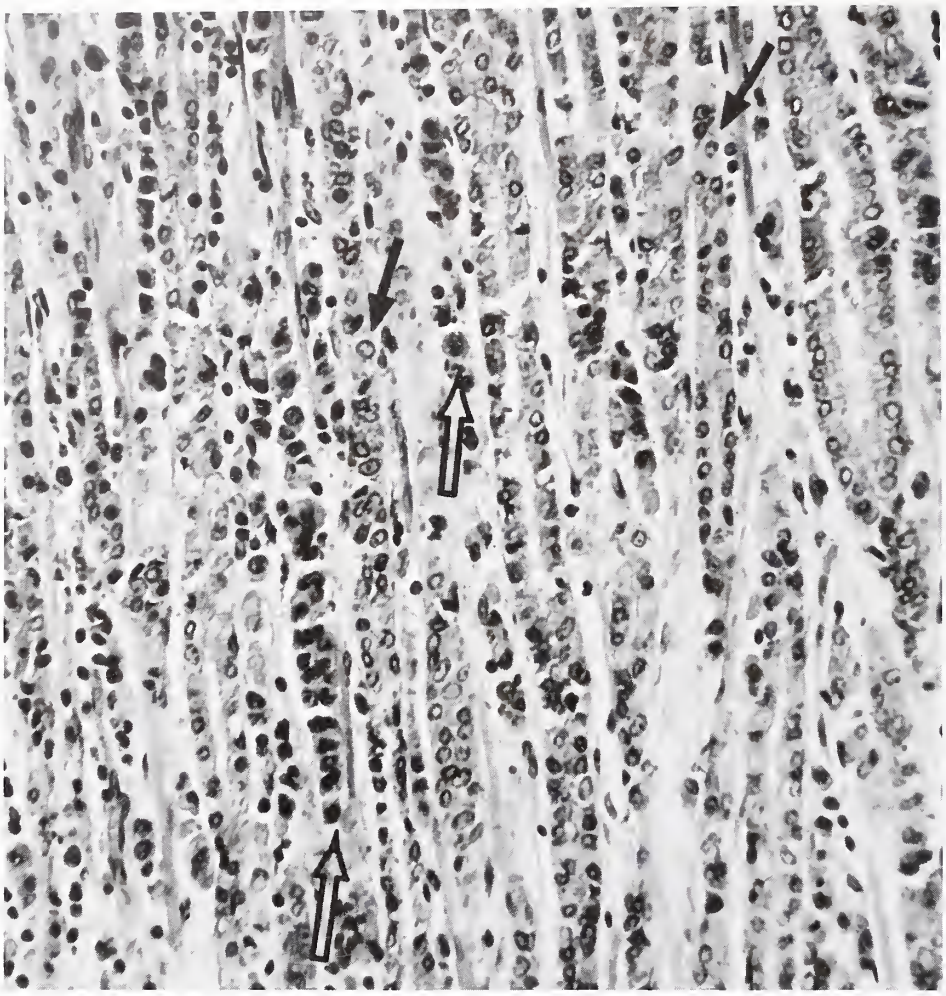

Fig. 136

CARCINOMA ASSOCIATED WITH MUCOSAL HYPERPLASIA

(Figures 135, 136, and 188 from same case)

This is a higher magnification of the demarcated area of tumor seen in figure 135. The glands are lined by a few parietal cells (solid arrows) and atypical mucous cells, many of which resemble the infiltrating tumor cells (open arrows) between the glands, suggesting origin of the tumor cells from the neck mucous cells. The tumor cells shown are undifferentiated, but signet ring cells were present in other areas. × 268.

In the deeper portion of the mucosa, there were multiple foci in which the glands were replaced by atypical cells, and tumor cells were present between the abnormal glands (fig. 136). The superficial portion of these glands appeared normal. This arrangement strongly suggests that the tumor cells arose from neck mucous cells. It is quite possible that mucosal hyperplasia is more frequently associated with carcinoma than the literature indicates, but has escaped attention because of the dominating feature of carcinoma. Nevertheless, the causal relationship between these two conditions remains uncertain.

References

Chusid, E. L., Hirsch, R. L., and Colcher, H. Spectrum of hypertrophic gastropathy. Giant rugal folds, polyposis, and carcinoma of the stomach—case report and review of the literature. Arch. Intern. Med. 114:621–628, 1964.

Ménétrier, P. Des polyadénomes gastriques et de leurs rapport avec le cancer de l'estomac. Arch. Physiol. Norm. Path. 1:32–55, 1888.

Moeller, D. D., Dunn, G. D., Laing, R. R., and Klotz, A. P. Hypertrophic gastropathy and carcinoma of the stomach. Gastroint. Endosc. 16:159–163, 1970.

Schindler, R. Gastric carcinoma and gastritis: with reference to coexistence of carcinoma and chronic hypertrophic glandular gastritis. Amer. J. Dig. Dis. 10:607–624, 1965.

Gastric Ulcer. Possible malignant transformation in chronic peptic ulcer has been evaluated by many pathologists, as well as clinicians, and often resulted in conflicting and controversial opinions. Recent studies indicate that carcinoma develops only rarely in chronic gastric ulcer, and that pathologic evidence for a preexisting benign ulcer in carcinoma is also a rare finding. When the carcinoma develops in a chronic ulcer, the term ulcer-carcinoma has been applied. Ihre and associates found five cases of carcinoma which had developed in an ulcer among 473 patients treated medically for ulcer. Of 278 ulcer cases studied by Ronnøv-Jessen and associates, gastric carcinoma was found in 10, 8 in 113 surgically resected stomachs, and 2 in 52 patients who died. Only one of the 10 cases had a history of chronic ulcer. Thunold and Wetteland collected 19 cases of ulcer-carcinoma among 726 stomachs resected for ulcer. When the surgically resected cancerous stomachs were studied, ulcer-carcinoma was found in 137 of 1,788 cases in Oota's series. Majima and associates (1965) studied 2,484 stomachs resected for either carcinoma or ulcer; 25 cases were found to be ulcer-carcinomas. These investigators suspected that ulcer was an important etiologic factor in gastric carcinogenesis and that malignant change in ulcer was common, at least in the Japanese people. A similar view was expressed by Kuru, who considered deep ulcer as a precursor of carcinoma in 38 of 100 cases of early carcinomas studied. Diagnosis of ulcer-carcinoma has been based on histologic observation of carcinoma along the margin, but not at the base, of a chronic ulcer. On the other hand, Mallory pointed out 30 years ago that peptic ulceration in early carcinoma might result in such an appearance. He also suspected that carcinoma might remain localized for periods of months to years, a view shared by many current cancer in-

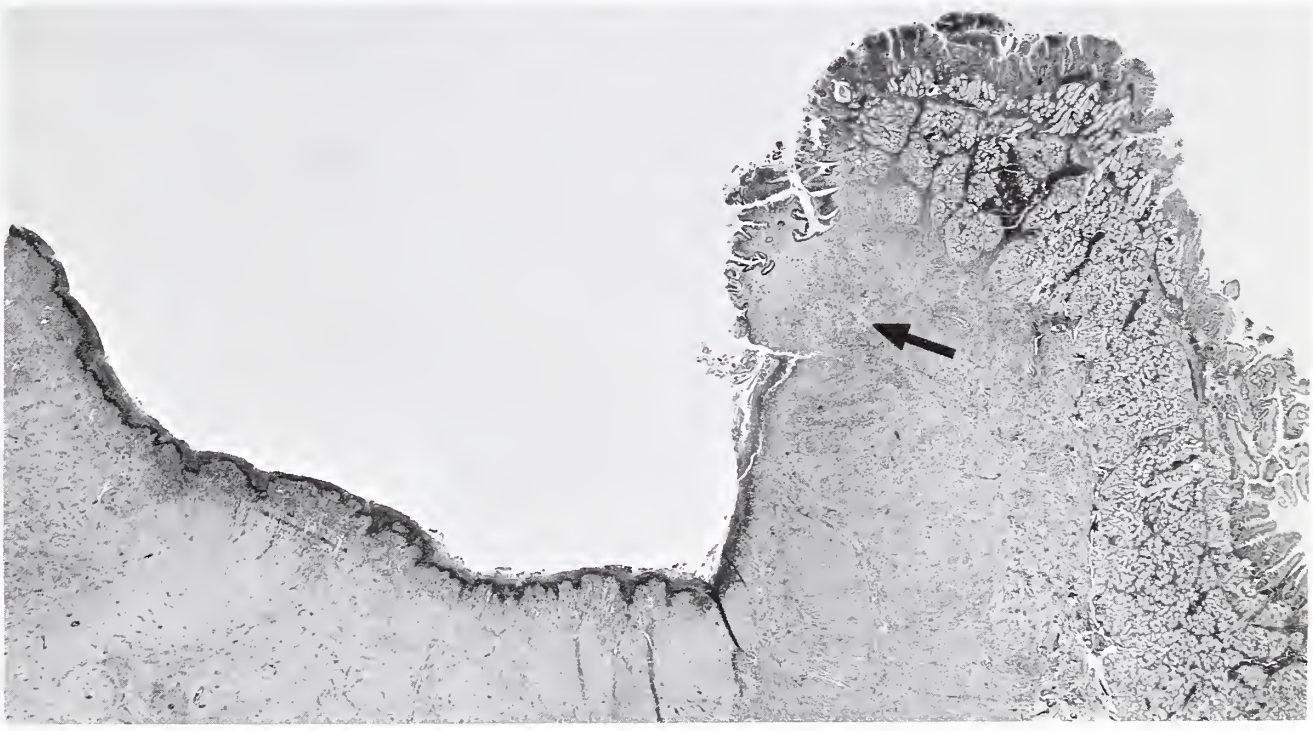

Fig 137

CARCINOMA WITH PEPTIC ULCERATION

(Figures 137 and 138 from same case)

This photomicrograph of an ulcerated carcinoma at the pylorus of a 32-year-old woman reveals a typical sharply demarcated peptic ulceration resembling a chronic benign ulcer. Carcinoma cells, however, are present at the margin (arrow) and in the fibrous tissue surrounding the ulcer. The dark cell clusters in the fibrous tissue at the lower border in the base of the ulcer are malignant. × 7.4.

vestigators. Majima and associates (1967) succeeded in producing ulcer-carcinoma in rats by implanting 4-nitroquinoline 1-oxide in beeswax in the gastric wall. In these experiments, ulcer developed first and carcinoma appeared after the ulcer became chronic. This observation demonstrated only that the gastric mucosa surrounding an ulcer was just as capable of responding to carcinogenic stimulation as the intact mucosa. Seemingly, one may also expect an occasional carcinoma to develop in a chronic ulcer in man. In most cases showing typical chronic ulcer and a limited amount of malignant tissue, the carcinoma is usually present in the base as well as the margins of the ulcer, thus favoring the interpretation of peptic ulceration in a preexisting carcinoma (figs. 137, 138). Other reports noted carcinoma developing in 2 to 5 percent of gastric stumps

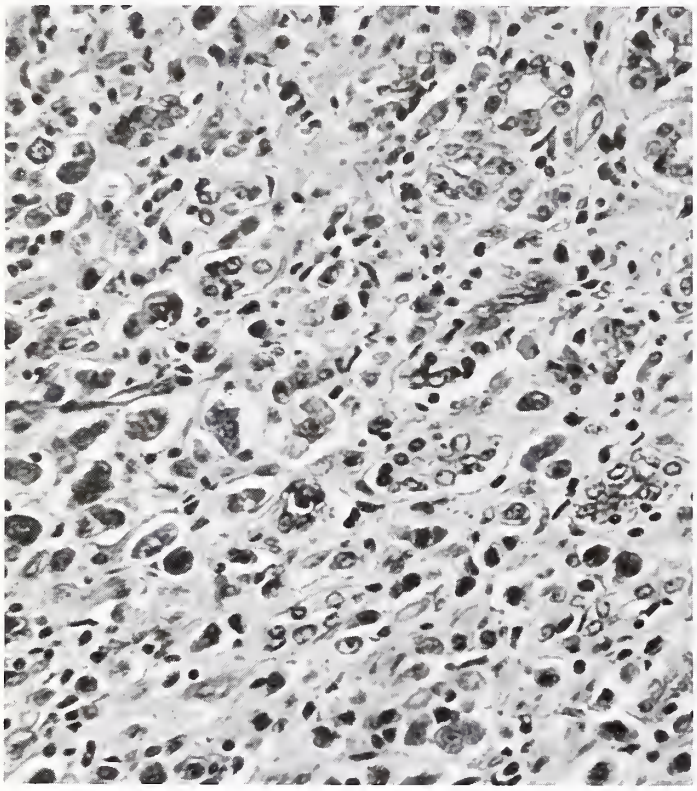

Fig. 138

CARCINOMA WITH PEPTIC ULCERATION

(Figures 137 and 138 from same case)

This photomicrograph of the area marked by the arrow in figure 137 reveals poorly differentiated adenocarcinoma. × 268.

many years after a partial gastrectomy for benign peptic ulcers, most of which were duodenal (Pygott and Shah). Occasionally, a separate benign gastric or duodenal ulcer accompanied carcinoma in the same stomach (Kirschenfeld et al.; Mason). Furthermore, the geographic distribution of gastric carcinoma and ulcer in Japan has been found to be entirely different (Hirohata and Kuratsune). Although the annual mortality rates from gastric carcinoma have been decreasing steadily in the United States, the incidence of gastric ulcer has remained unchanged (Jordan). Such findings further diminish the significance of gastric ulcer as a carcinogenic factor.

References

Hirohata, T., and Kuratsune, M. The geographical comparison of mortality from cancer of the stomach and ulcer of the stomach in Japan. Brit. J. Cancer 23:465–479, 1969.

Ihre, B. J., Barr, H., and Havermark, G. Ulcer-cancer of the stomach. A follow-up study of 473 cases of gastric ulcer. Gastroenterologia 102:78–91, 1964.

Jordan, G. L., Jr. Decreasing incidence of carcinoma of the stomach. Amer. J. Surg. 116:407, 1968.

Kirschenfeld, S., Mermelstein, R. H., and Aronson, A. L. Concomitant duodenal ulcer and gastric carcinoma. New York J. Med. 65:1786–1789, 1965.

Kuru, M. Atlas of Early Carcinoma of the Stomach. Tokyo: Nakayama-Shoten Co., 1967.

Majima, S., Takahashi, T., Yoshida, K., Karube, K., Machida, T., Narisawa, T., Hoshi, H., Hiroki, T., Ito, K., and Kurata, Y. Atypical epithelial proliferation in the course of experimental production of ulcer-carcinoma of the stomach. Tohoku J. Exp. Med. 93:363–376, 1967.

———, Yamaguchi, I., Karube, K., Teshima, T., and Yoshida, K. A histopathologic study on the origin of early carcinoma of the stomach. Tohoku J. Exp. Med. 86:348–365, 1965.

Mallory, T. B. Carcinoma in situ of the stomach and its bearing on the histogenesis of malignant ulcers. Arch. Path. 30:348–362, 1940.

Mason, M. K. Surface carcinoma of the stomach. Gut 6:185–193, 1965.

Oota, K. Role of gastric ulcer in the causation of gastric cancer in Japan a histopathological study of 3,000 gastrectomy materials Acta Un. Int Cancr. 19 1208–1209, 1963

Pygott, F., and Shah, V L. Gastric cancer associated with gastroenterostomy and partial gastrectomy. Gut 9 117–124, 1968

Rønnov-Jessen, V., Ahlgren, P., Qvist, C F. Incidence of gastric cancer in medically treated patients with gastric ulcer Acta Med. Scand 178 141–153, 1965

Thunold, S., and Wetteland, P Ulcer-carcinoma of the stomach in a 10-year-biopsy series A follow-up study of 19 patients Acta Path. Microbiol. Scand 56 155–165, 1962.

HISTOGENESIS OF ADENOCARCINOMA. Cells in the deep foveolar and neck portions of the gastric glands are the actively proliferating cells responsible for the normal turnover of mucous cells (Teir and Räsänen). These cells have also been assumed to become intestinalized in form (Ming et al.). In cancerous stomachs, both the metaplastic and nonmetaplastic foveolar cells often show atypical hyperplasia, or dysplasia, a change rarely seen in the stomach without a concomitant carcinoma. The dysplastic glands are lined by single or pseudostratified cells, often with papillary intraluminal infoldings. These cells are hyperchromatic and show reduced mucin secretion; mitoses are common (figs. 139–141). In about 20 percent of cancerous stomachs, carcinoma in situ may be found in either or both foveolar or metaplastic cells of the glands (figs. 142–144).

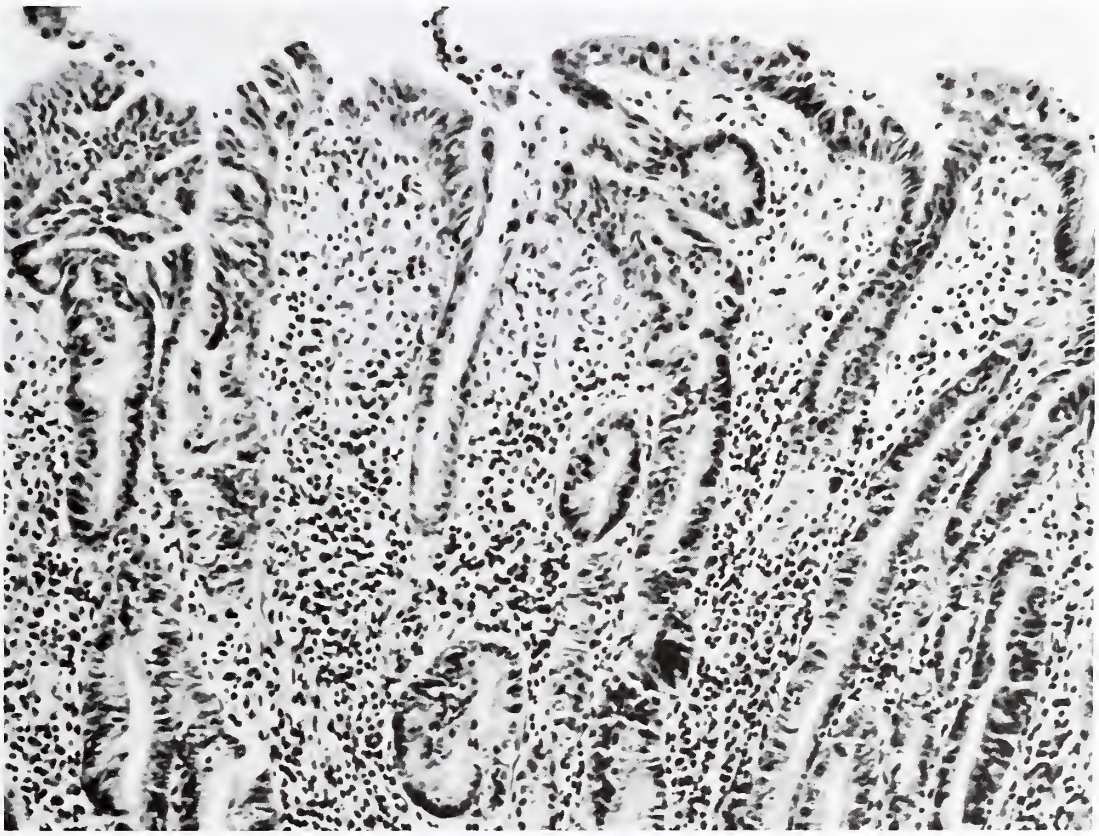

Fig 139

DYSPLASIA OF FOVEOLAR AND SURFACE EPITHELIUM

The stomach of a 70-year-old woman was resected because suspicious cells were found in the gastric washing. The resected specimen showed extensive dysplasia, but no tumor. This photomicrograph shows marked hyperplasia of mucous cells in the surface and foveolar region. In some areas, the epithelium is pseudostratified and shows papillary infoldings into the lumen. Most of the cells have hyperchromatic nuclei and reduced mucus content. There is no intestinal metaplasia. Chronic inflammation is prominent in the lamina propria. × 168 (Courtesy of Beth Israel Hospital, Boston, Mass.)

Fig. 140

CYTOLOGIC APPEARANCE OF DYSPLASTIC FOVEOLAR CELLS

This group of atypical columnar cells was found in the gastric washing on an 82-year-old man who had an adenocarcinoma in the cardiac region. The cells are hyperchromatic; cytoplasm is scanty, revealing little mucus secretion. The gastric mucosa away from the tumor showed dysplastic changes. × 500.

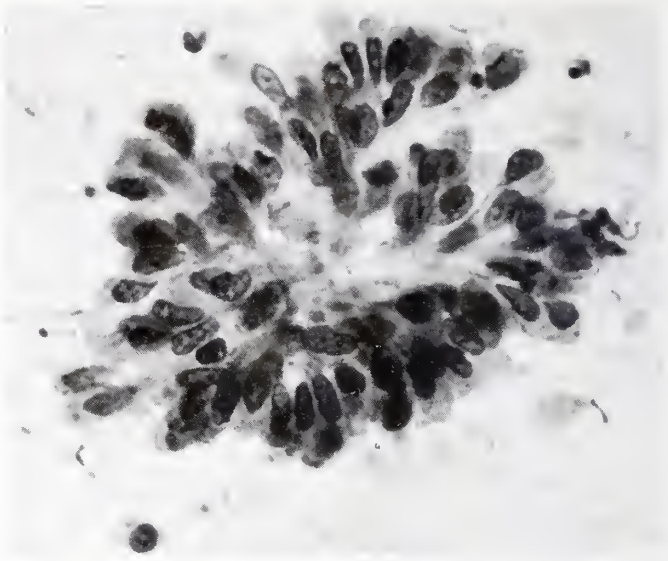

Fig. 140

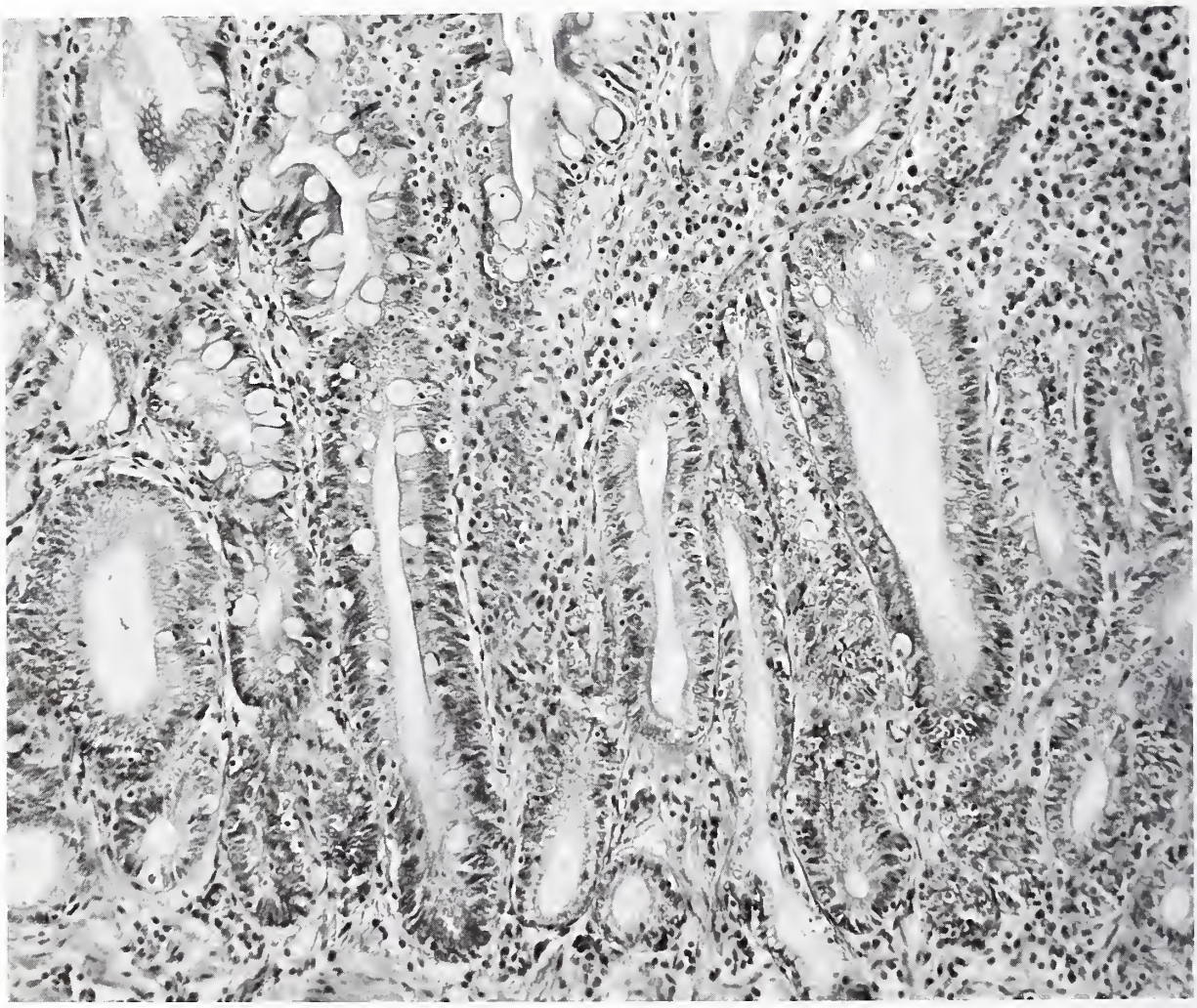

Fig. 141

DYSPLASIA OF METAPLASTIC EPITHELIUM

(Figures 141 – 143, and 146 from same case)

This is a photomicrograph of pyloric mucosa showing dysplastic cells in the deeper portion of metaplastic glands. Many mitotic figures are present. The lamina propria shows mild chronic inflammation. This section is from the stomach of an 81-year-old woman with a superficial carcinoma in the pyloric region. The gross photograph of the tumor is illustrated in figure 146. × 150. (Courtesy of Beth Israel Hospital, Boston, Mass.)

CARCINOMA IN SITU IN FOVEOLAE

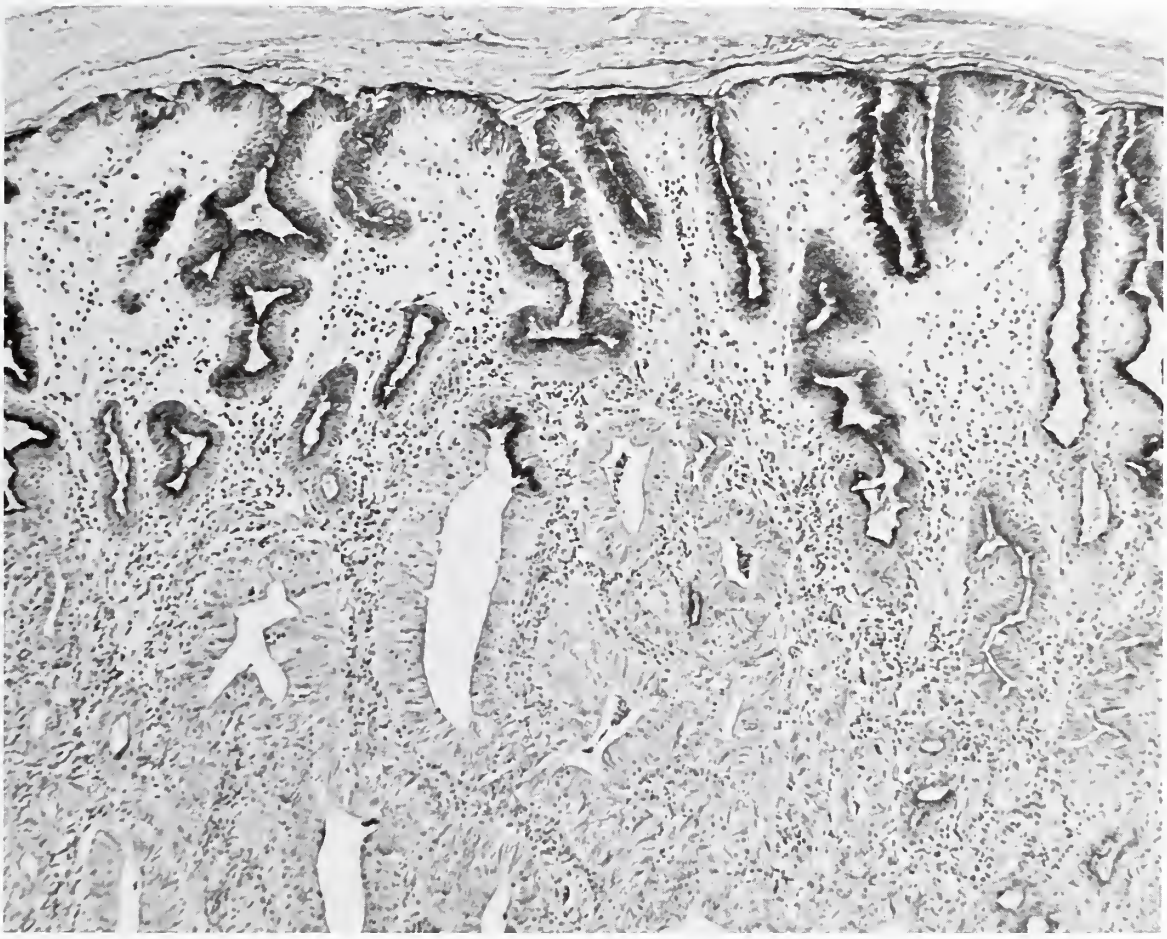

Fig 142

(Figures 141 –143, and 146 from same case)

This photomicrograph of pyloric mucosa is from an area contiguous with superficial carcinoma (fig 146) and reveals carcinoma in the deep portion and hyperplastic cells in the superficial portion of the foveolae. The transition is shown in the midfield The hyperplastic cells have normal mucus secretion, but the tumor cells do not. Mild chronic inflammation is present and intestinal metaplasia was present in other areas (fig 141). PAS stain. × 95. (Courtesy of Beth Israel Hospital, Boston, Mass.)

Fig 143

CARCINOMA AND METAPLASTIC GLANDS

(Figures 141 – 143, and 146 from same case)

This photomicrograph of another area bordering the main tumor shows carcinoma admixed with metaplastic glands. The second gland from the left and another gland on the right show benign intestinal metaplasia. Goblet cells are seen in the gland in the middle, which is continuous with invasive carcinoma in the superficial area. × 192. (Courtesy of Beth Israel Hospital, Boston, Mass.)

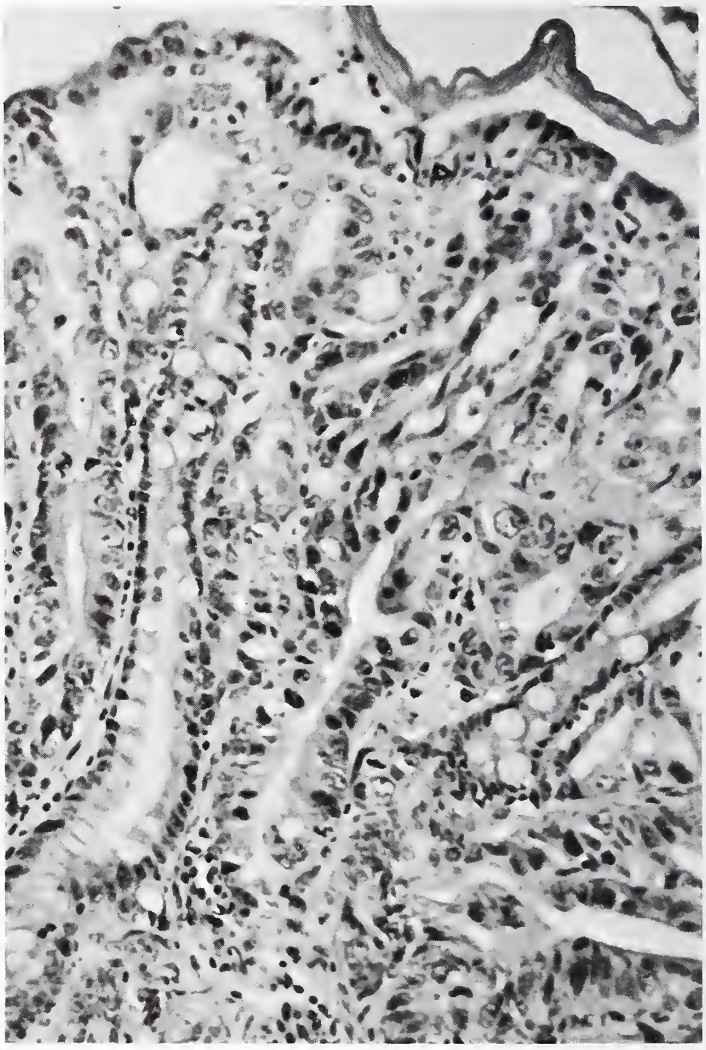

Fig 143

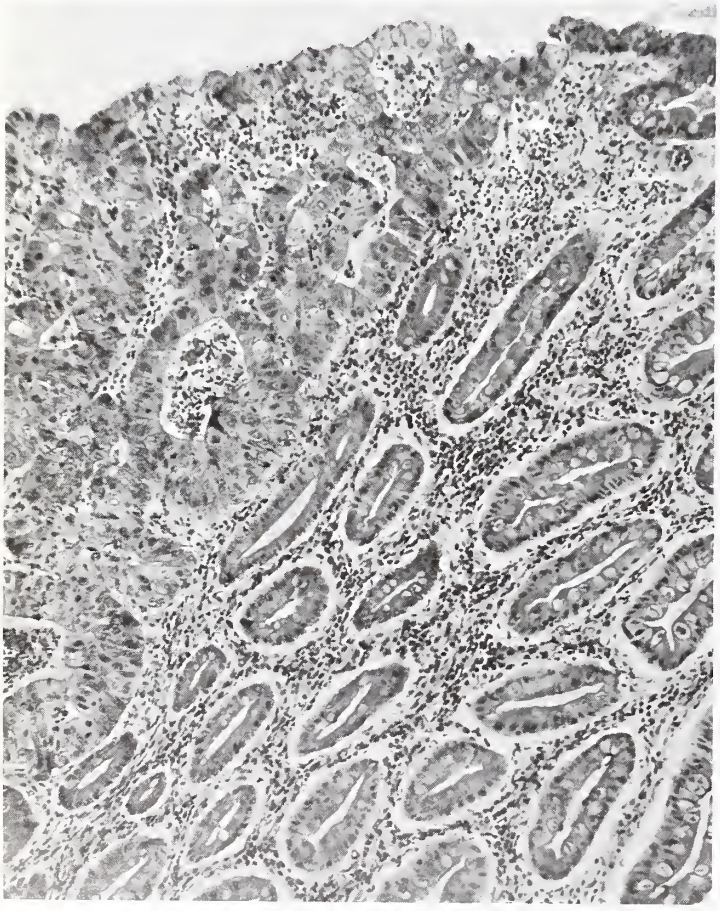

Fig 144

Fig 144

CARCINOMA AND METAPLASTIC GLANDS

(Figures 144 and 166 from same case)

This photomicrograph shows dysplastic metaplastic glands on the right and in situ carcinoma of the stomach on the left. In the latter, goblet cells are present in the superficial portion. × 95.

Well differentiated invasive carcinoma of the stomach often exhibits features seen in intestinalized cells. These features include the presence of goblet cells and striated borders (Goldman and Ming; Järvi and Laurén; Ming et al.), acid mucin (Goldman and Ming; Stemmermann), and enzymes normally present in intestinal epithelium (Planteydt and Willighagen; Stemmermann; Wattenberg). Many tumor cells, however, have poorly developed microvilli and contain only neutral glycoprotein, resembling the nonmetaplastic normal foveolar cells. One may trace the evolution of these two types of tumor cells in the mucosa adjacent to the carcinoma through stages of hyperplasia, dysplasia, and carcinoma in situ, particularly in carcinomas with glandular structures. Conversely, these changes are rarely found in carcinomas with diffuse infiltration by individual cells, such as signet ring cell carcinoma. In such tumors, the lack of significant intestinal metaplasia and the intact superficial mucosa (fig. 136) in the cancerous area suggest the possible origin of tumor cells from the neck mucous cells or pyloric gland cells.

Gastric carcinoma may begin in a wide field rather than in one focus, as shown by studies on early carcinomas when they are still limited to the mucosa (Ewing; Hess; Kuru; Friesen et al.). Superficial erosion and deep ulceration are common in these early tumors. Ewing described frequent digestive excavation in an early carcinoma that left only a ring of tumor tissue at the edge of the ulcer.

References

Ewing, J. The beginnings of gastric cancer. Amer. J. Surg. 31:204–205, 1936.

Friesen, G., Dockerty, M. B., and ReMine, W. H. Superficial carcinoma of the stomach. Surgery 51:301–312, 1962.

Goldman, H., and Ming, S.-C. Mucins in normal and neoplastic gastrointestinal epithelium. Histochemical distribution. Arch. Path. 85:580–586, 1968.

Hess, R. Early cancer of the stomach. Gastroenterologia 86:365–369, 1956.

Järvi, O., and Laurén, P. On the role of heterotopias of the intestinal epithelium in the pathogenesis of gastric cancer. Acta Path. Microbiol. Scand. 29:26–44, 1951.

Kuru, M. Atlas of Early Carcinoma of the Stomach. Tokyo: Nakayama-Shoten Co., 1967.

Ming, S.-C., Goldman, H., and Freiman, D. G. Intestinal metaplasia and histogenesis of carcinoma in human stomach. Light and electron microscopic study. Cancer 20:1418–1429, 1967.

Planteydt, H. T., and Willighagen, R. G. J. Enzyme histochemistry of gastric carcinoma. J. Path. Bact. 90:393–398, 1965.

Stemmermann, G. N. Comparative study of histochemical patterns in non-neoplastic and neoplastic gastric epithelium. A study of Japanese in Hawaii. J. Nat. Cancer Inst. 39:375–382, 1967.

Teir, H., and Räsänen, T. A study of mitotic rate in renewal zones of nondiseased portions of gastric mucosa in cases of peptic ulcer and gastric carcinoma, with observations on differentiation and so-called "intestinalization" of gastric mucosa. J. Nat. Cancer Inst. 27:949–971, 1961.

Wattenberg, L. W. Histochemical study of aminopeptidase in metaplasia and carcinoma of the stomach. Arch. Path. 67:281–286, 1959.

LOCATION AND SIZE OF CARCINOMA. Carcinomas may occur anywhere in the stomach. By the time the tumor is examined, it may have reached large size and involved more than one region of the stomach, although the distal portion of the stomach appears to be the favored site. Of nearly 5,000 cases of gastric carcinoma reviewed by Borrmann, the tumor was in the pyloric region in 40 to 60 percent of cases with an average incidence of 50 percent; on the lesser curvature in 7 to 26 percent, averaging 13 percent; in the cardiac region in about 10 percent; and diffusely infiltrating in 6 percent of cases. The remaining tumors were randomly scattered on the greater curvature, in the fundic area, and on the anterior and posterior walls. Willis collected 1,006 cases of gastric carcinoma and the tumor was located as follows: pylorus and antrum, 47 percent; lesser curvature, 26 percent; cardia, 10 percent; other areas, 9 percent; and the whole organ, 8 percent of cases. Eker and Efskind reviewed

1,212 cases; the tumor was in the lesser curvature in 39 percent, greater curvature in 12 percent, anterior or posterior wall in 24 percent, and circumferential in 25 percent of cases. Thus, a lesion located in the proximal part and on the greater curvature of the stomach is compatible with a carcinomatous lesion; peptic ulcers, by contrast, are uncommon in these sites. Other tumors, however, may be situated in these areas.

The size of the tumor at the time of diagnosis is variable. In a series of 222 cases, Monafo and associates found that 8 percent of the tumors were less than 2 cm. in diameter; 44 percent were between 2 and 6 cm.; 30 percent, between 6 and 10 cm.; 9 percent, between 10 and 16 cm.; and 5 percent were larger than 16 cm. A similar range was reported by Collins and Gall. The thickness of the tumor does not always correspond with the size of the area involved. The linitis plastica type of infiltrative carcinoma is a well known example. Similarly, an early carcinoma limited to the mucosa may involve a large area. Of the 65 early carcinomas reported by Friesen and associates, only 8 percent involved an area 2 sq. cm. or less and 17 percent involved 30 to 100 sq. cm. of the mucosa.

GROSS. The gross characteristics of gastric carcinoma are determined by the relative prominence of one or more of four major features: multicentric origin; surface erosion or ulceration; invasiveness; and mass formation. The extent of multicentricity affects the size of the initial area involved and probably the size of the tumor. Superficial or in situ carcinoma is often observed at the periphery of the tumor irrespective of its size. Of 117 tumors examined by Collins and Gall, preinvasive carcinoma was found in continuity with main tumor in 22 and in areas independent of main tumor in 26 cases. The surface of the tumor is usually eroded or ulcerated, but deep peptic ulceration is not common. The latter occurs chiefly in small superficial carcinoma, probably reflecting a relatively good secretory activity in the rest of the stomach. Invasiveness of the tumor cells and their ability to form an aggregated mass may be inversely related. In many tumors, different cell populations can be easily recognized within the same tumor histologically; each seems to have a different innate ability to invade. Thus, portions of the tumor may penetrate deeply into the gastric wall, while in other areas the tumor grows into a voluminous intraluminal mass. In addition to these intrinsic factors, the regions of the stomach also contribute to the morphologic character of the tumor. A carcinoma in the wide proximal portion of the stomach is likely to form a voluminous fungating tumor in contrast to one in the narrow pyloric region.

Many different classifications of the gross appearances of gastric carcinoma have been presented. The one widely adopted was devised by Borrmann. He divided gastric carcinoma into four groups: (1) Circumscribed, solitary, polypoid carcinoma without significant ulceration; (2) ulcerative carcinoma with wall-like edge and sharp delineation; (3) ulcerative carcinoma, in part with wall-like border and in part diffusely spreading; and (4) diffuse carcinoma. Borrmann's classification does not include features of some important tumors.

The following classification is based on gross morphologic features of the tumor with consideration of its biologic and behavioral tendencies:

1. **Superficial Carcinoma.** Other terms commonly used are carcinoma in situ and superficial spreading carcinoma. The term carcinoma in situ should be restricted to the intraglandular location of the tumor cells. As Friesen and associates pointed out, superficial carcinoma is a more accurate term, since this type of tumor has invaded the lamina propria despite its early development. Involvement of a large area by the tumor probably is a result of multicentric origin rather than spreading from a small focus (Hess). Superficial carcinoma accounted for about 12 percent of gastric carcinomas in Nagayo and associates' series of 1,351 cases and 3 percent in Hess's series of 520 cases.

Two distinct subgroups of superficial carcinoma are seen. One shows a deep peptic ulceration with malignant tissue limited to the mucosa or submucosa at one or more foci along the border of the ulcer. This appearance creates the impression that the ulcer preceded the cancer; thus, it has been called ulcer-cancer. As discussed in the sections on local tissue factors and histogenesis of gastric carcinomas, the reverse relationship is more likely. The other type of superficial carcinoma presents a platelike lesion with shallow erosions, but no deep ulceration (Friesen et al.). The involved area may be either slightly thickened and indurated (figs. 145, 146) or depressed and superficially ulcerated (fig. 147). In either case, decreased mucus secretion in the area results in a dull appearance. Superficial erosion gives it a reddened and granular appearance. These tumors are extensively illustrated by Kuru.

Fig. 145

Fig. 145

SUPERFICIAL CARCINOMA

This postmortem specimen from an 83-year-old woman shows a large superficial carcinoma along the greater curvature of the stomach in prominent, roughened folds. The gastric mucosa in other areas is flat and atrophic. The patient had had weight loss and malaise for six months. The gastric lesion was not discovered even at laparotomy. The tumor involved the submucosa and had metastasized. (Courtesy of Beth Israel Hospital, Boston, Mass.)

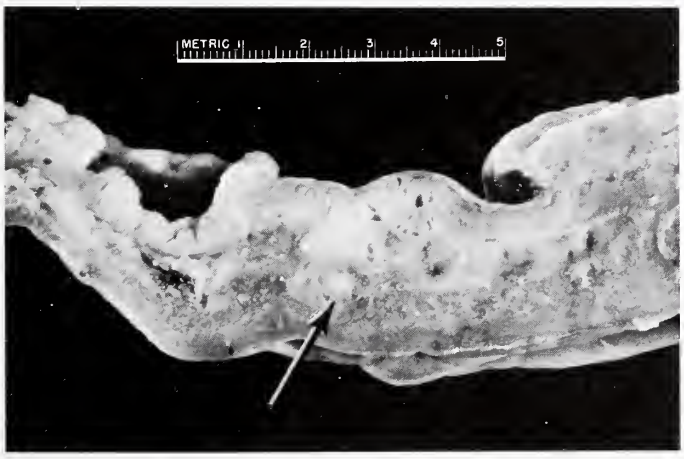

Fig. 146

Fig. 146

SUPERFICIAL CARCINOMA

(Figures 141 – 143, and 146 from same case)

This is a photograph of the cut surface of a superficial carcinoma, 4 cm. in diameter, in the pyloric antrum of an 81-year-old woman. The neoplastic area was indurated and occupies the left two-thirds of the mucosa which measures 2 to 3 mm. in thickness. There is a superficial ulcer in the middle third. A focus of submucosal invasion by carcinoma is shown as white tissue (arrow). A roentgenogram revealed an ulcer of questionable malignant nature. (Courtesy of Beth Israel Hospital, Boston, Mass.)



Fig. 147

SUPERFICIAL CARCINOMA

(Figures 147, 167, and 168 from same case)

This distal portion of stomach was resected from a 78-year-old man after an ulcerated lesion was seen roentgenographically. A 2 x 3 cm. congested and atrophic area is shown along the lesser curvature, near the proximal resection margin at the right. There is irregular, superficial ulceration about 1 cm. in width through the length of the lesion. The histologic appearance of this tumor is seen in figure 167.

2. **Polypoid Carcinoma.** This carcinoma corresponds to Borrmann's type 1 carcinoma. The tumor forms a sharply delineated intraluminal mass with a lobulated surface. There may be superficial erosion, but no large ulceration (figs. 148–150). Some of these tumors have excessive mucus secretion giving them a gelatinous or colloid appearance. The base of the tumor invades the underlying gastric wall to a varying extent, but lateral spread is not prominent. This type constitutes about 8 percent of gastric carcinomas, according to Borrmann. This tumor is apparently formed by cells with limited invasive ability. It simulates villous adenoma in its gross form. No clear evidence suggests a cause and effect relationship between a preexisting polyp and polypoid carcinoma, however. Instead polypoid carcinoma appears to be malignant from its inception (Nagayo et al.).

POLYPOID CARCINOMA

Fig. 148

A polypoid carcinoma is seen on the lesser curvature in the proximal portion of the stomach of a 76-year-old man. It measured 6.8 x 5.0 cm. and projected 1.4 cm. above the mucosal surface. There was superficial invasion of the muscularis externa, but no metastases to regional lymph nodes.

POLYPOID CARCINOMA



Fig. 149

This large polypoid carcinoma occupied the proximal half of the lesser curvature of the stomach in a 70-year-old man who died of bronchopneumonia. It has a sharply delineated contour with a lobulated surface, and a broad base infiltrated by the tumor. The gastric tumor was unsuspected and there were no metastases.



Fig. 150

This polypoid carcinoma, measuring 11 x 9 x 2.2 cm., was located on the anterior wall in the midportion of the stomach. The tumor has an irregularly ulcerated surface and is sharply demarcated. It measured 7 x 3.5 cm. at the base. The tumor contained a large amount of mucinous material and had penetrated to the serosa and metastasized to regional lymph nodes.

3. **Ulcerated Infiltrative Carcinoma.** This common form of gastric carcinoma occurs in approximately 30 to 40 percent of cases. Its two distinct patterns are about equal in frequency. One is a prominent deep ulceration, and the other is a shallow ulcer on a broad base giving a saucer-like configuration. In either form, invasive tumor is evident at the ulcer margins as well as in the base. In the first subgroup showing deep peptic ulceration, mucosal folds may radiate from the ulcer and form overhanging borders in a fashion resembling that presented by benign ulcers (fig. 151). Features indicating the malignant nature of the lesion can usually be found, however. These features include sloping indurated margins rather than overhanging ulcer margins of normal mucosa and a firm, hemorrhagic ulcer base covered with shaggy necrotic material (fig. 151). Such characteristics may not be apparent in the roentgenogram, however (fig. 152), and differential diagnosis between benign ulcer and ulcerated carcinoma may be difficult. In many cases, the infiltrating process may be a helpful diagnostic aid; infiltration of tumor cells in the mucosa and submucosa causes them to form rigid raised borders surrounding the ulcer (figs. 153, 154). Roentgenographically, this thickened border is easily visualized (fig. 155). In the second subgroup, a comparably shallow, but usually large ulcer is superimposed on an obviously infiltrative tumor (pl. V–A). The gastric wall surrounding and underlying the ulcer is thickened, sometimes to a marked degree, and the tissue bordering the ulcer is raised, forming a ridge (figs. 156–158). This form corresponds to Borrmann's type 2 carcinoma. The ulcerated infiltrative carcinomas share their basic configurations with superficial carcinomas, and may represent later stages of development.

Fig. 151

Fig. 151

ULCERATED INFILTRATIVE CARCINOMA

This specimen was resected from an 81-year-old man. An ulcer, measuring 3 x 2.5 cm., is located on the lesser curvature of the distal portion of the fundic mucosa. The normal mucosal folds converge on the ulcer, except for small areas at the upper and distal margins where the mucosa is slightly indurated and slopes toward the ulcer. Tumor was present in the hemorrhagic base of the ulcer.

ULCERATED INFILTRATIVE CARCINOMA

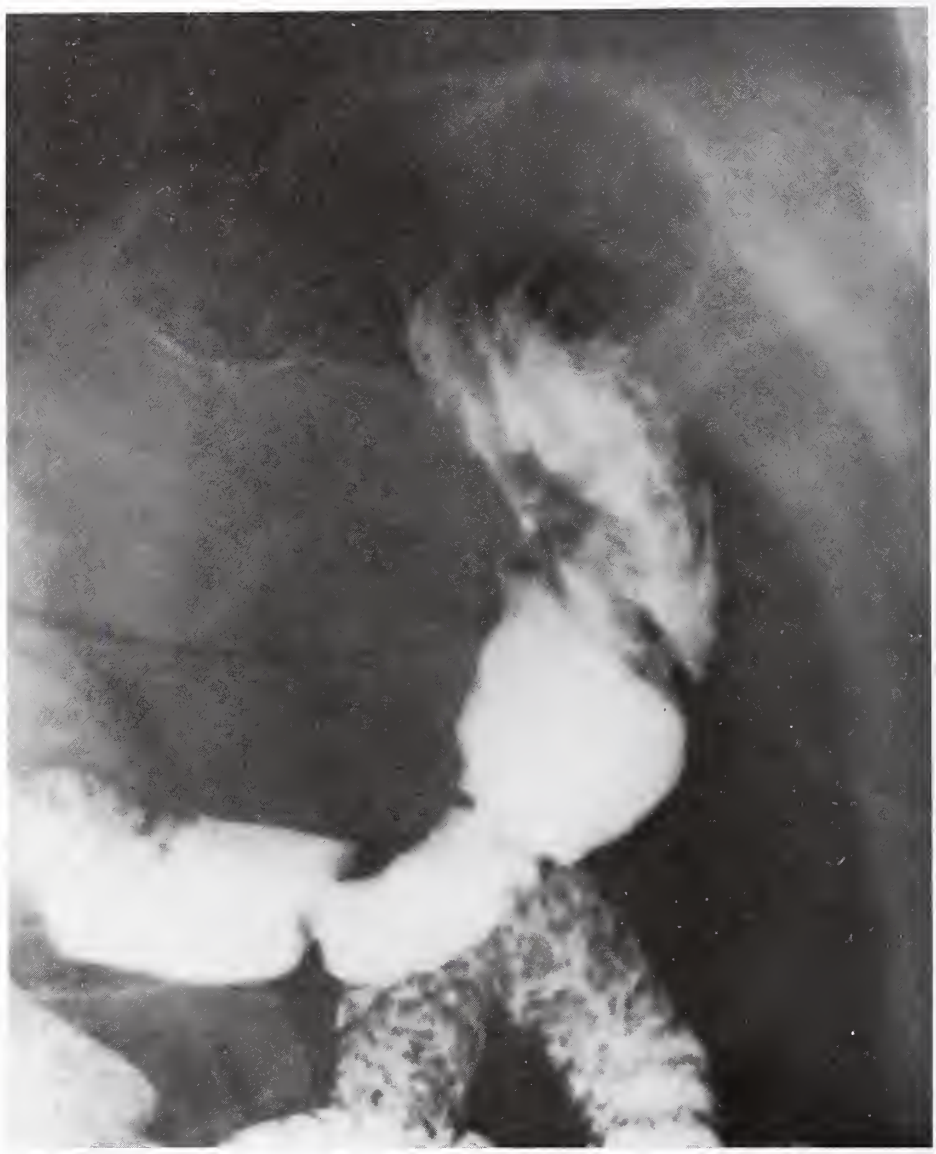

Fig. 152

This roentgenogram reveals an ulcerated lesion on the lesser curvature of the stomach with mucosal folds converging on the ulcer margins.

ULCERATED INFILTRATIVE CARCINOMA

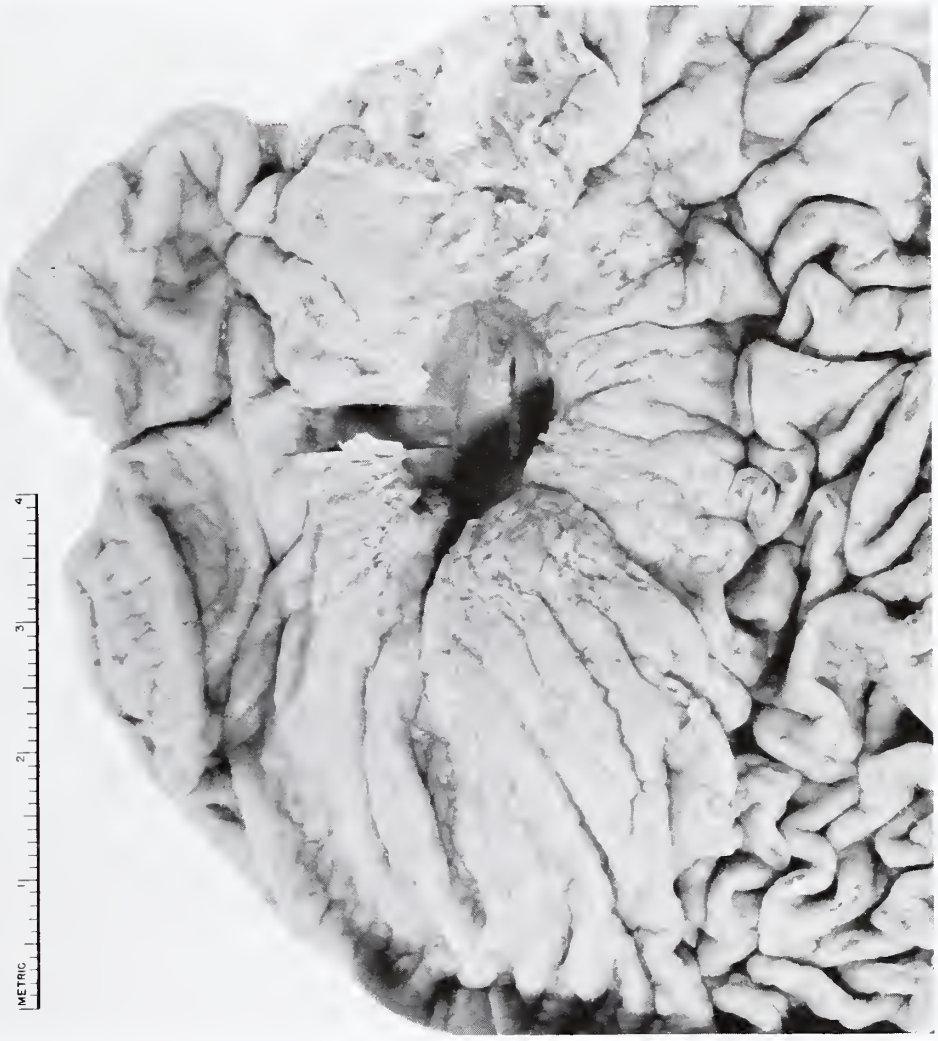

Fig 153

This is a deeply ulcerated carcinoma of the antrum in a 52-year-old man. The ulcer is sharply delineated with a slightly overhanging border. The mucosa surrounding the ulcer is raised, indurated, puckered, and roughened by increased fine lobulation and granularity. The underlying gastric wall is thickened.



Fig. 154

ULCERATED INFILTRATIVE CARCINOMA

This photograph of an ulcerated carcinoma in the fundic mucosa shows the irregular border of the ulcer formed by indurated, nodular mucosa. The normal appearing mucosal folds do not reach the ulcer in most areas. The base of the ulcer is firm and shaggy.

Fig. 155

ULCERATED INFILTRATIVE CARCINOMA

This roentgenogram of an ulcerated carcinoma in the mid-portion of the stomach in a 56-year-old man reveals an 8 cm. ulcer surrounded by thickened tissue bulging into the lumen along the greater curvature. The mucosal folds around the ulcer are obliterated.

ULCERATED INFILTRATIVE CARCINOMA

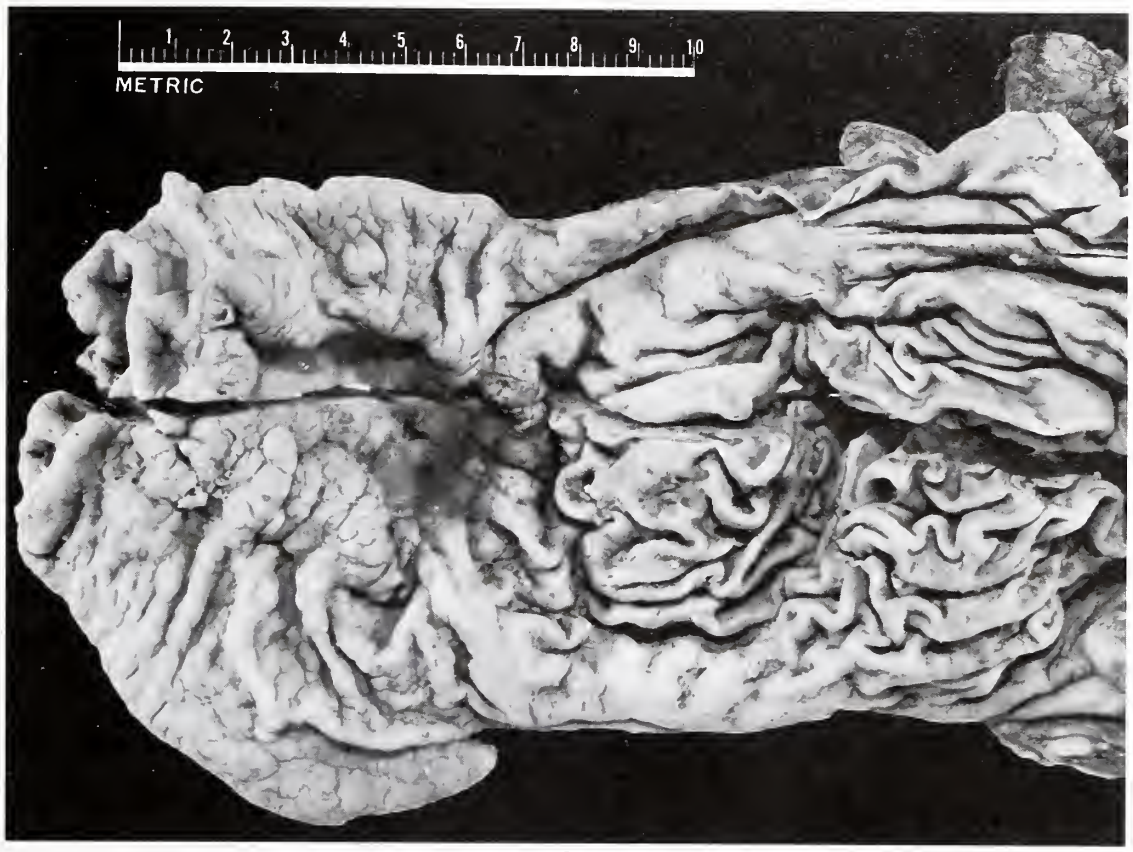

A

B

Fig. 156

This specimen was resected from a 43-year-old man. Photograph A shows an ulcerated carcinoma in the distal portion of the stomach. The mucosa at the distal and lower margins of the ulcer has a cobblestone appearance. B shows the cut surface through the center of the ulcerated area and reveals well defined white and light gray tumor tissue forming the base of the ulcer and involving the mucosa at the distal end on the left.

Fig. 157

Fig. 157

ULCERATED INFILTRATIVE CARCINOMA

This specimen is from a 57-year-old woman. On the lesser curvature, near the cardiac end, there is a saucer-shaped, indurated tumor with shallow ulceration. The ulcerated area is hemorrhagic and necrotic. The mucosal folds of the surrounding mucosa, shown on the right, radiate from the ulcer. On the opposite side, an indurated ridge of tumor separates the ulcer from the normal mucosa. (Courtesy of Beth Israel Hospital, Boston, Mass.)

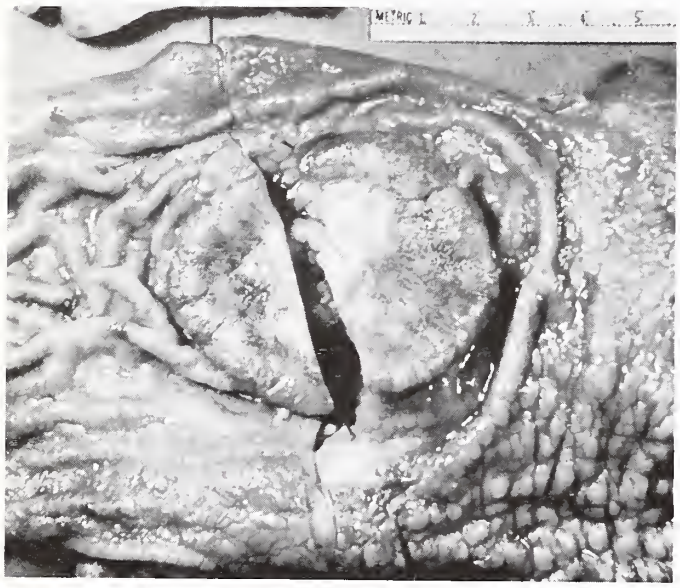

Fig. 158

ULCERATED INFILTRATIVE CARCINOMA

This is a photograph of a disk-shaped tumor at the junction of the antral and fundic mucosa, which had penetrated through the thickness of the gastric wall. The tumor has a sharply demarcated, raised border and a shallow, ulcerated center.

4. **Fungating Carcinoma.** This tumor exhibits prominent intraluminal growth and equally prominent invasiveness into the gastric wall. It corresponds to Borrmann's type 3 carcinoma and constitutes about 30 percent of gastric carcinomas. The surface of the tumor is irregularly ulcerated, leaving a shaggy nodular appearance (figs. 159, 160). Invasiveness of the tumor is manifested laterally as well as in depth. As a result, the tumor has an ill-defined base and tumor tissue may be seen some distance from the main mass. The relative proportion between the intraluminal mass and infiltration into the gastric wall is variable. In some, a large polypoid mass projecting into the lumen suggests a link with polypoid carcinoma (fig. 159). In others, extensive infiltration of the tumor into the gastric wall causes marked thickening, whereas the intraluminal portion of the tumor is relatively flat (fig. 160). This latter appearance suggests a relationship to the saucer-like ulcerated infiltrative carcinoma; Stout included this type of ulcerated carcinoma in the fungating group.

FUNGATING CARCINOMA

Fig. 159

This large, asymptomatic carcinoma was found in an 83-year-old man who died of severe coronary heart disease after nailing of a fractured hip. The tumor formed a large polypoid mass and extended to the subserosa. It also infiltrated along the plane of the gastric wall, resulting in a broad base and nodular thickening of the surrounding tissue. There were no metastases.

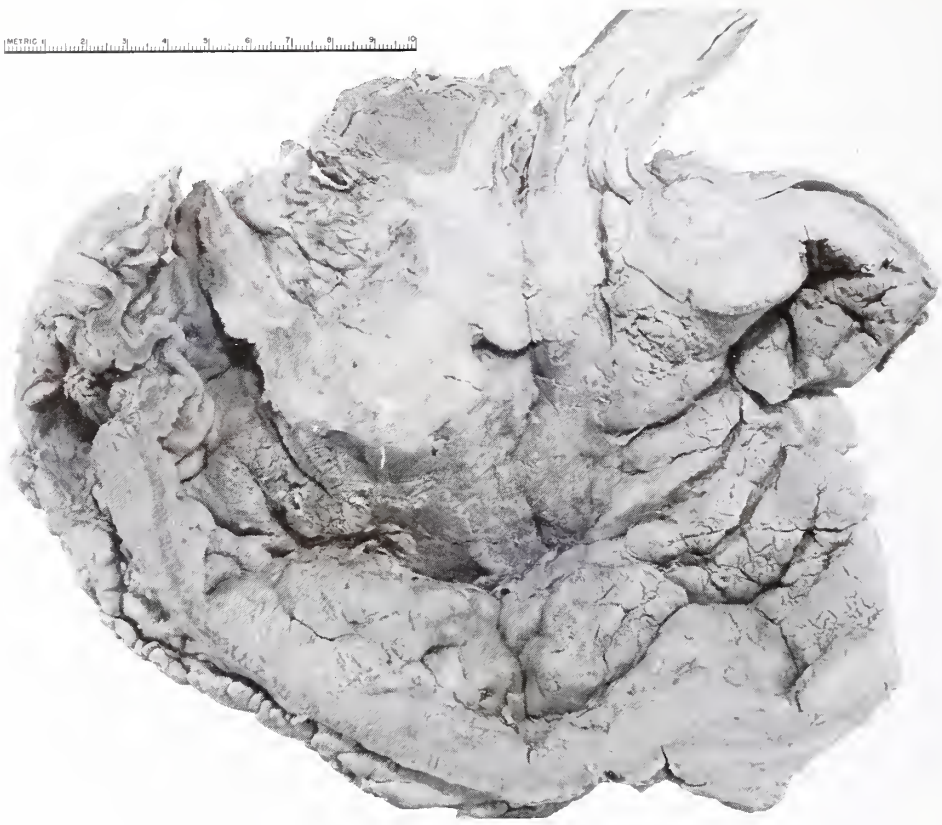

Fig 160

FUNGATING CARCINOMA

This postmortem specimen was obtained from a 72-year-old man who had had gastric symptoms for one year and died with massive metastases to the liver Carcinoma involved most of the stomach except the pyloric end There was marked thickening of the gastric wall with irregular nodular masses on the inner surface of the stomach, which measured an average of 3 cm in thickness

5. **Diffusely Infiltrative Carcinoma.** This carcinoma primarily manifests extensive infiltration of the tumor along the gastric wall, causing marked thickening and stiffening of the wall. Intraluminal growth is relatively inconspicuous. It corresponds to Borrmann's type 4 carcinoma, and constitutes about 10 to 20 percent of gastric carcinomas. Tumor infiltration may involve a large but limited area (figs. 161, 162) or the entire stomach (figs. 163, 164). In the latter case, the term linitis plastica has long been used. The mucosal surface of the stomach may be slightly nodular and necrotic in some areas and grossly intact in others. On cut surface, the submucosa is thickened and fibrosed and streaks of pale tumor tissue may be seen penetrating bundles of the muscularis externa. The subserosa is also fibrosed and small tumor nodules may be present on the serosal surface. The attached omenta are often infiltrated, indurated, and thickened.

Linitis plastica type of stomach has also been reported in benign diseases, such as syphilis, sarcoidosis, and eosinophilic gastritis. Figure 85 demonstrates this feature in a case of allergic granulomatosis involving the stomach. But Stout had not observed any example of benign disease causing diffuse thickening of the stomach and

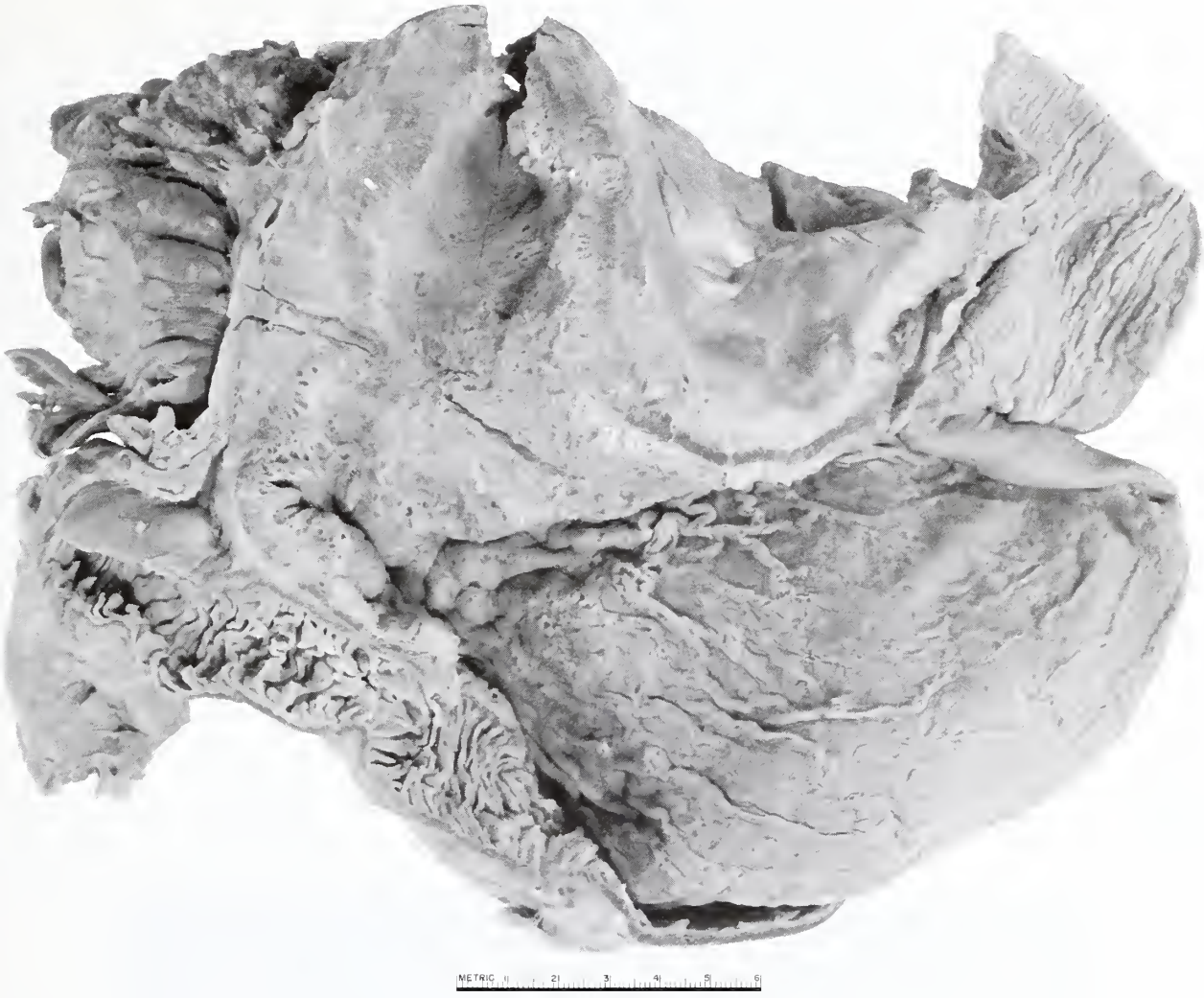

Fig. 161

DIFFUSELY INFILTRATIVE CARCINOMA

This is a postmortem specimen from a 40-year-old man who had a posterior gastroenterostomy one year prior to his death after diagnosis of a gastric ulcer. Autopsy revealed thickening of the distal portion of the stomach and marked stenosis of the pylorus. Small collections of mucinous material in the tumor appear as multiple, small cystic areas. The infiltrated muscularis externa is thicker and less distinct in the distal portion than the dark muscle on the cut surface in the proximal portion.

commented that undifferentiated tumor cells commonly present in this tumor might have been misinterpreted as benign.

Gross appearances of gastric carcinoma as represented by this classification suggest two principal growth patterns: one primarily exhibits an intraluminal growth and the other an intramural growth. These patterns are modified by two major factors—deep ulceration and superficial erosion. A relationship among the five groups is suggested in figure 165.

Fig 162

Fig. 162

DIFFUSELY INFILTRATIVE CARCINOMA

This photograph of a diffuse carcinoma involving the distal third of the stomach shows marked thickening of the gastric wall, particularly the submucosa. The superficially eroded mucosa is diffusely irregular with a few small nodules. (Courtesy of Beth Israel Hospital, Boston, Mass.)

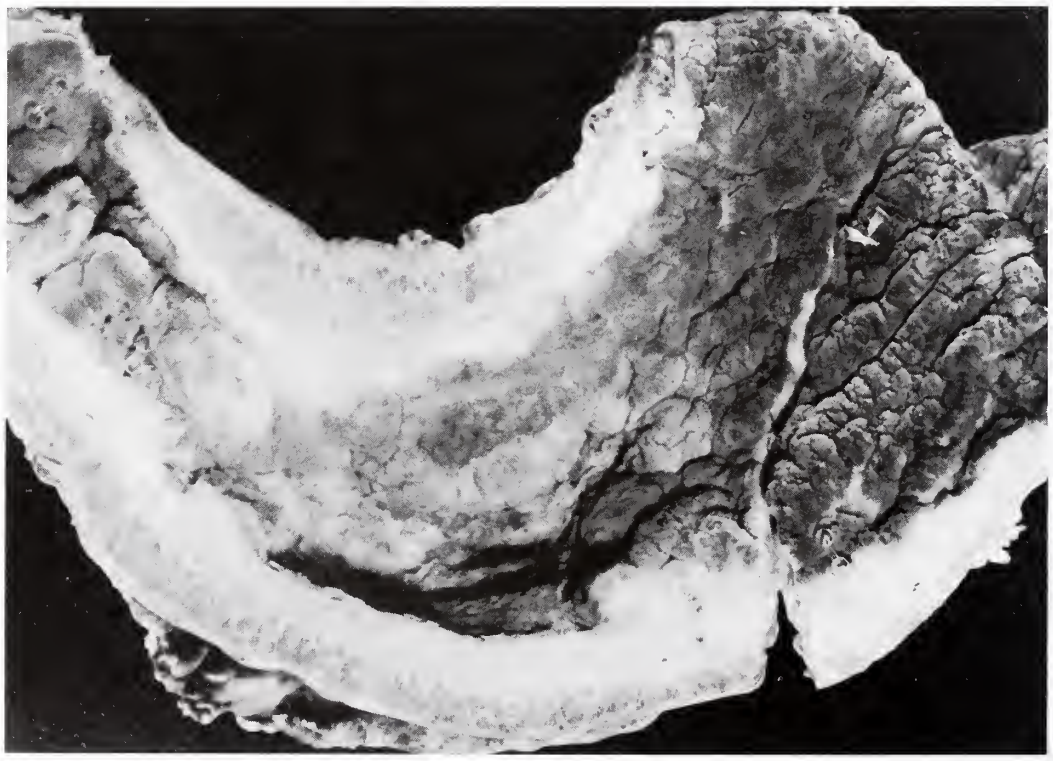

Fig 163

DIFFUSELY INFILTRATIVE CARCINOMA

This stomach contains extensive carcinoma, shown in white, which diffusely thickens the submucosa and penetrates through the muscularis. The mucosa is irregularly eroded in the distal portion and forms thick folds in the proximal portion.

Fig. 164

DIFFUSELY INFILTRATIVE CARCINOMA

This is a postmortem specimen from a 77-year-old man with a 9-month history of epigastric pain and weight loss. The entire stomach is markedly indurated, and the tumor has penetrated the serosa into the omentum.

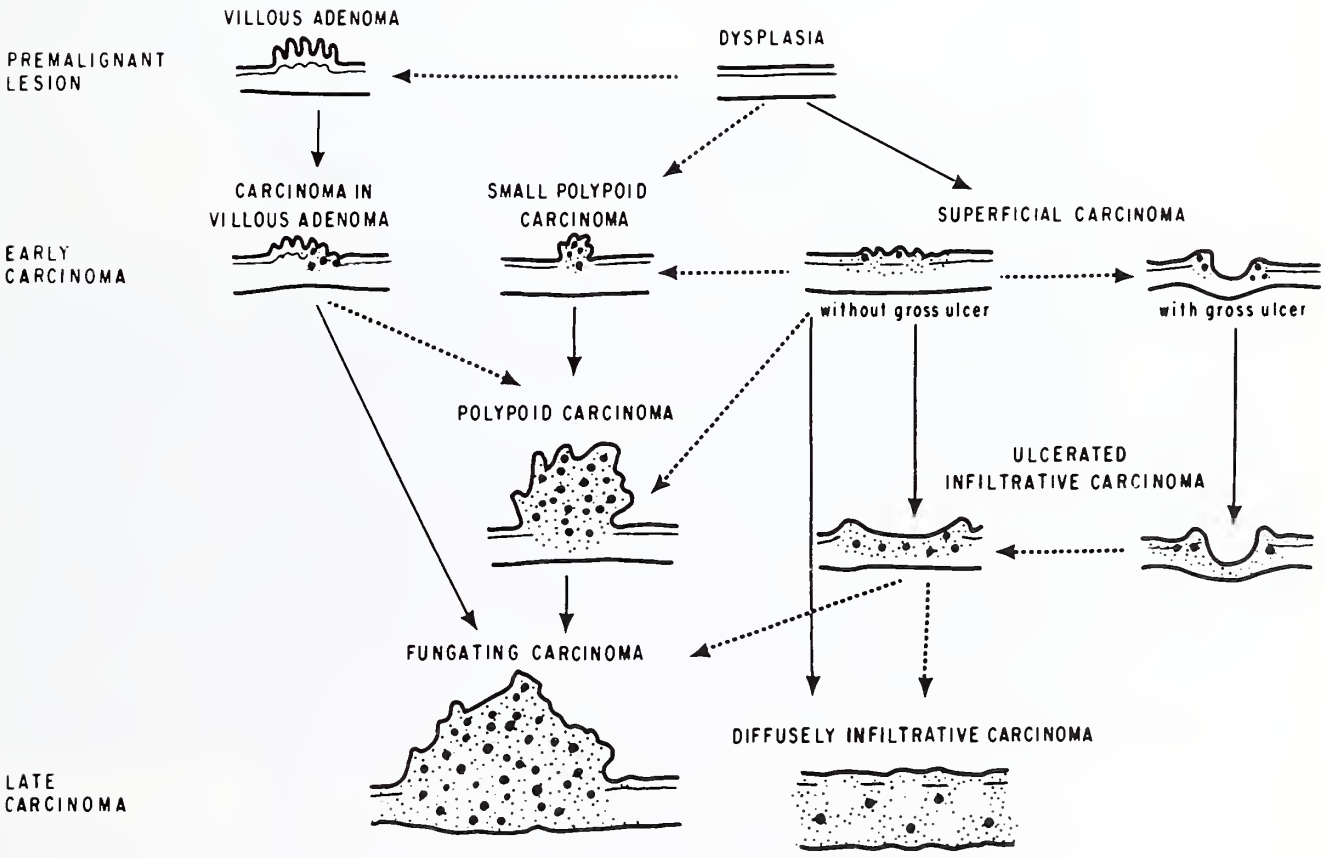

Fig. 165

SEQUENTIAL DEVELOPMENT OF GROSS PATTERNS OF GASTRIC CARCINOMA

This schematic drawing illustrates the probable sequential development of gross patterns of gastric carcinoma. The thin lines represent muscularis mucosae and the dots represent carcinomatous tissue. Solid arrows indicate the probable major pathways, and broken arrows indicate the minor pathways.

References

Borrmann, R. Geshwülste des Magens und Duodenums. In: Henke, F., and Lubarsch, O. Handbuch der Spezieller Pathologischen Anatomie und Histologie. Vol. 4, pt. 1, p. 865. Berlin: J. Springer, 1926.

Collins, W. T., and Gall, E. A. Gastric carcinoma: a multicentric lesion. Cancer 5:62 – 72, 1952.

Eker, R., and Efskind, J. The pathology and prognosis of gastric carcinoma. Based on 1314 partially and totally resected cases. Acta Chir. Scand. Suppl. 264:1 – 182, 1960.

Friesen, G., Dockerty, M. B., and ReMine, W. H. Superficial carcinoma of the stomach. Surgery 51:301 – 312, 1962.

Hess, R. Early cancer of the stomach. Gastroenterologia 86:365 – 369, 1956.

Kuru, M. Atlas of Early Carcinoma of the Stomach. Tokyo: Nakayama-Shoten Co., 1967.

Monafo, W. W., Jr., Krause, G. L., and Medina, J. G. Carcinoma of the stomach. Morphological characteristics affecting survival. Arch. Surg. 85:754 – 763, 1962.

Nagayo, T., Ito, M., Yokoyama, H., and Komagoe, T. Early phases of human gastric cancer. Morphological study. Gann 56:101 – 120, 1965.

Stout, A. P. Tumors of the Stomach. Fascicle 21, Atlas of Tumor Pathology. Washington: Armed Forces Institute of Pathology, 1953.

Willis, R. A. Pathology of Tumours, p. 389. 4th ed. New York: Appleton-Century-Crofts, 1967.

MICROSCOPIC. Gastric carcinoma probably arises from multiple glands, generally within a broad area. This view is supported by the occurrence of multiple independent foci of intramucosal carcinoma (figs. 166 – 169) in superficial carcinomas and in mucosa adjacent to invasive tumor, and the finding of different patterns of tumor growth within the same tumor (fig. 170). These findings were present in 55 percent of 117 carcinomas studied by Collins and Gall. The vast majority of carcinoma cells are of mucous cell origin, capable of forming glandular structures and secreting mucinous materials. In many tumors a wide range of these capabilities is manifested side by side within the same tumor (fig. 171). Furthermore, there is no clear correlation between microscopic grading and the gross patterns of the tumors. Based on these facts, Stout considered histologic classification hopeless and unrewarding. Nevertheless, many pathologists continued to labor on detailed histologic classifications, primarily in the hope of correlating them with survival rates.

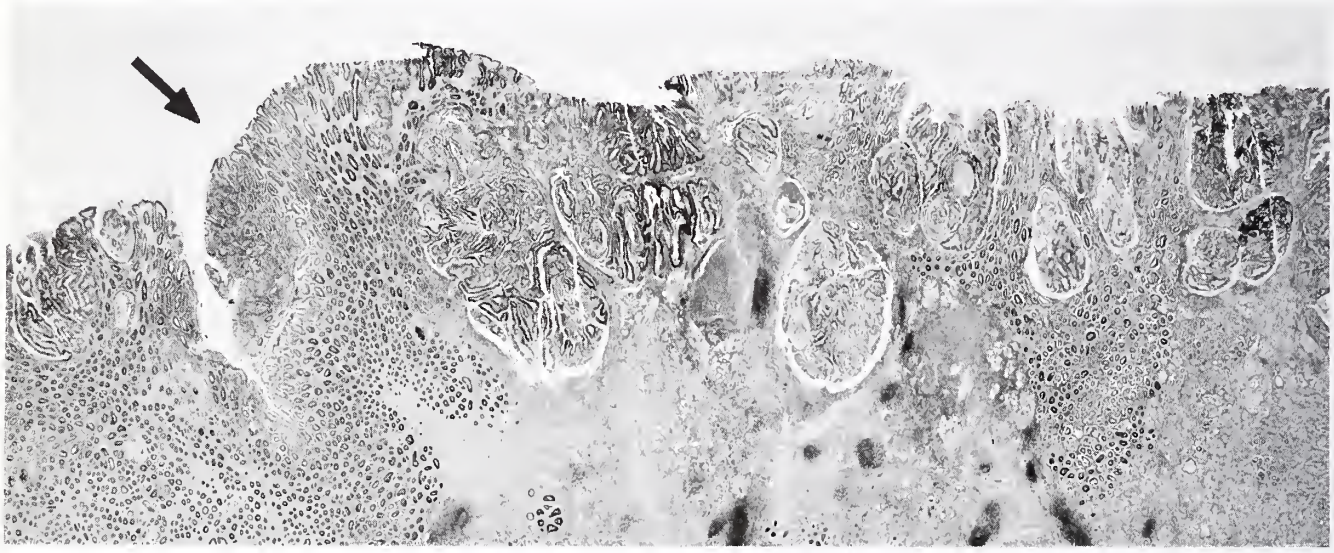

Fig. 166

MULTICENTRIC CARCINOMA

(Figures 144 and 166 from same case)

This photomicrograph shows multiple foci of neoplastic clustered glands in the mucosa suggesting multicentric origin of this moderately differentiated adenocarcinoma. Marked intestinal metaplasia is also present. The area opposite the arrow is illustrated in figure 144. × 7.4

SUPERFICIAL CARCINOMA

(Figures 147, 167, and 168 from same case)

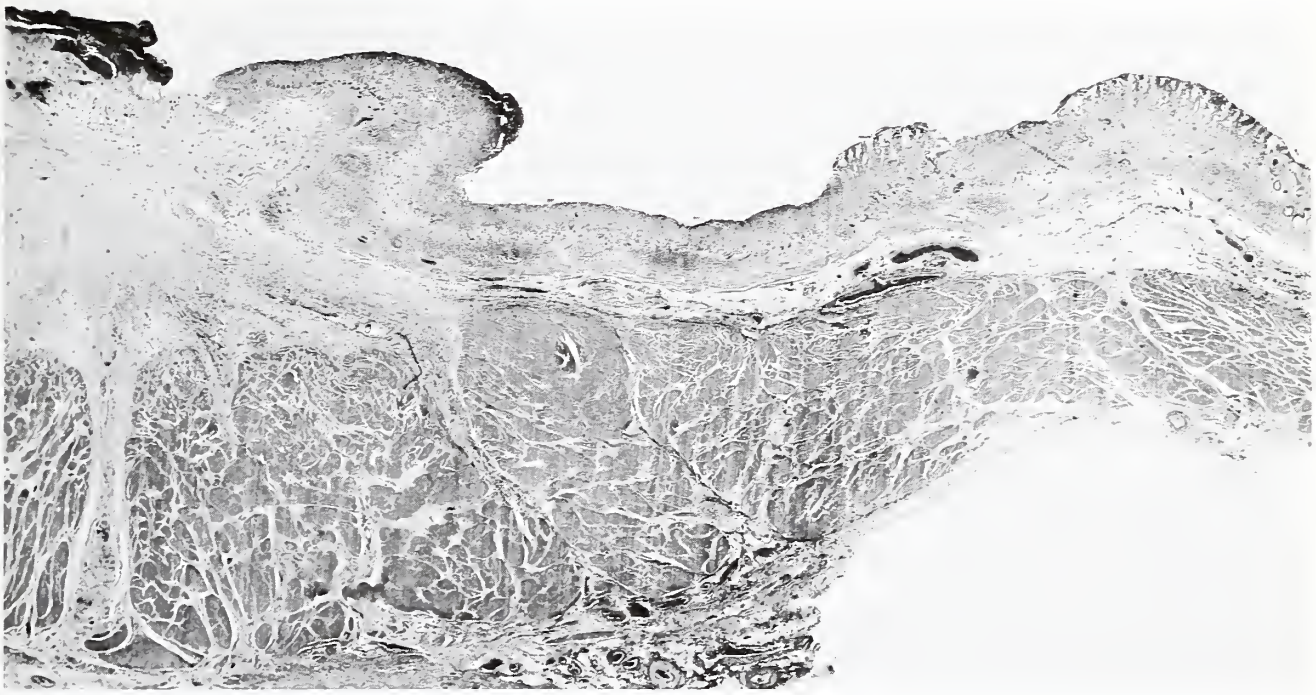

Fig. 167

This photomicrograph of the tumor illustrated in figure 147 shows normal mucosa (right) and depressed areas of superficial carcinoma involving the mucosa (center). The tumor extends into the submucosa with superficial erosion and accompanying fibrosis (left). × 7.4.

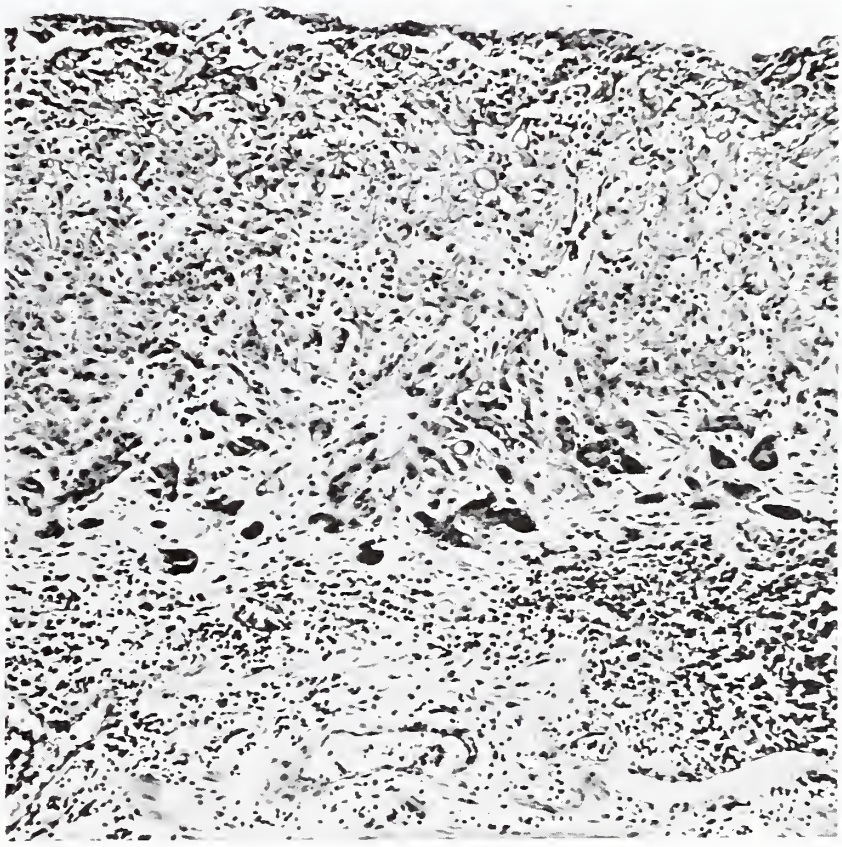

Fig. 168

Higher magnification of the area in the center of the same tumor reveals poorly differentiated cells. This portion of carcinoma is limited to the mucosa. × 100.

Fig. 169

SUPERFICIAL CARCINOMA

This is a photomicrograph of a diffuse glandular carcinoma in the pyloric mucosa adjacent to a large carcinoma. The patient was a 77-year-old man who had two independent polypoid carcinomas in the stomach. × 27.

Fig. 170

ADENOCARCINOMA

This is a photomicrograph of the entire cross section of a saucer-shaped carcinoma in the pyloric region, measuring 2 cm. in diameter and 8 mm. in thickness. At the periphery, the tumor is papillary and in the center, it is poorly differentiated. × 6.

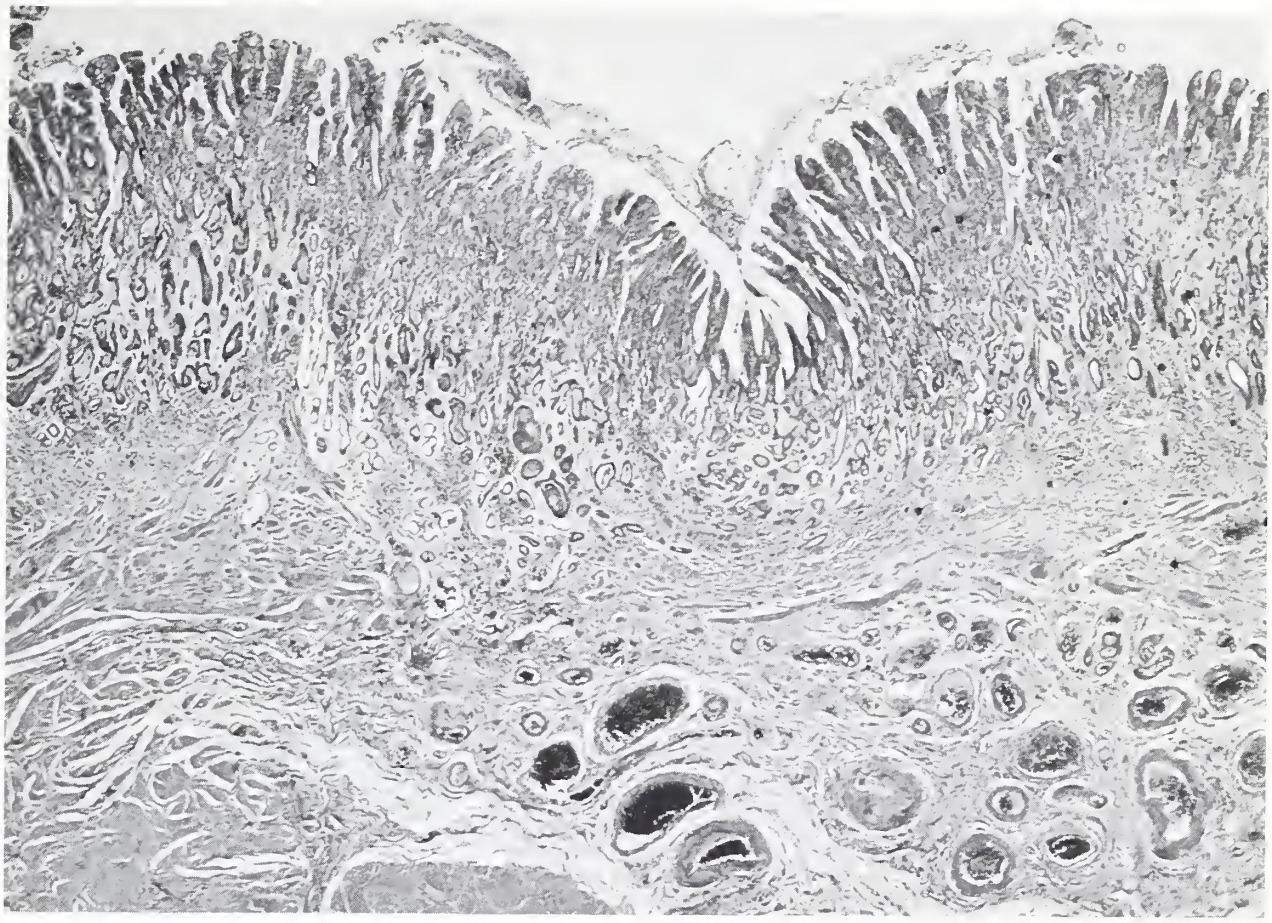

Fig 169

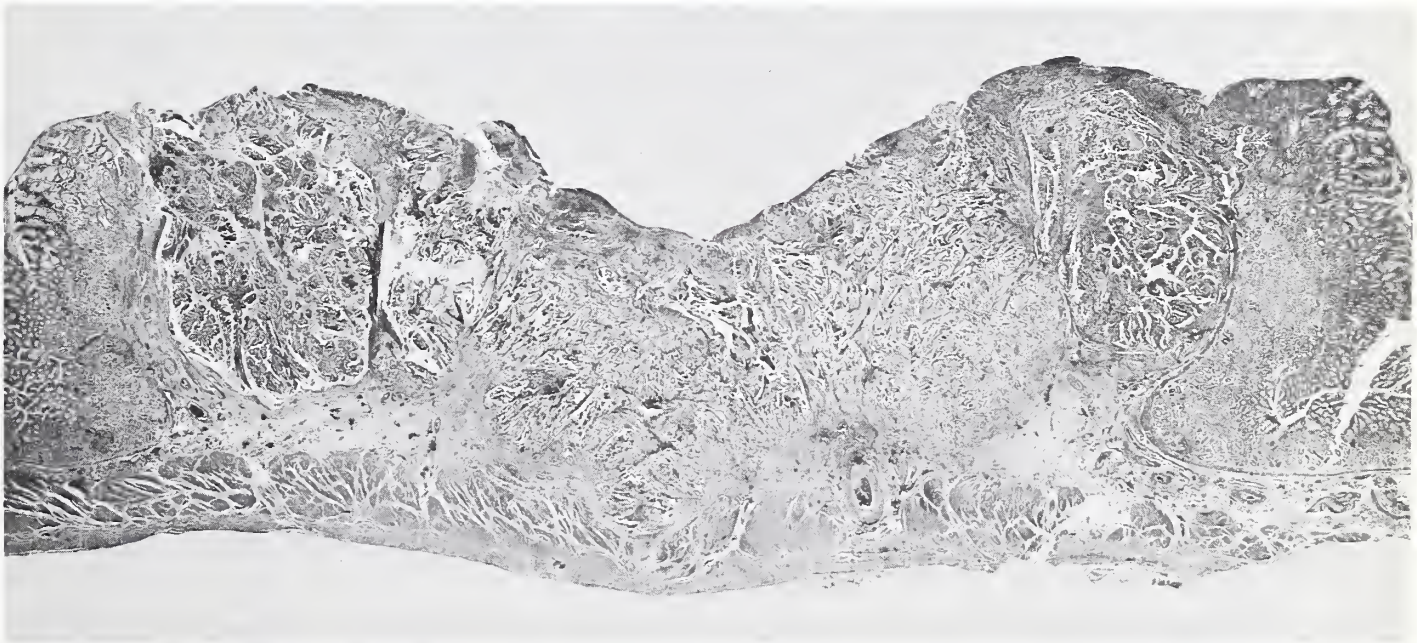

Fig 170

Seemingly, the significance of microscopic features lies not in the degree and variation of cellular differentiation, but in the biologic behavior demonstrated by these features. In this regard, the tumor cells may be divided into two main groups: in one, the tumor cells tend to aggregate forming glands, islands, or masses, and in the other, the tumor cells separate from each other and infiltrate individually.

The aggregated or glandular type of tumor cells is present in the majority of carcinomas. The well differentiated cells form glandular structures (figs. 171, 172), occasionally in papillary form (figs. 173, 174). These cells often exhibit well formed striated borders (fig. 174) and secrete mucus as small vacuoles (fig. 175) or in large goblet form (fig. 176). Occasionally, excessive mucin secretion is accumulated extracellularly (fig. 177) and forms large pools of gelatinous material visible to the naked eye. This tumor is known as colloid or mucinous carcinoma. Striated borders and goblet cells were found in about half the tumors studied by Järvi and Lauren and by Ming and associates. Striated borders are readily observable electron microscopically (figs. 178, 179; Goldman and Ming; Sasano et al.). Histochemical studies by Goldman and Ming and by Stemmermann of mucinous secretion revealed a strong periodic acid-Schiff reaction and a positive reaction for alcian blue, usually at pH 2.5, and occasionally at pH 1 (pl. III-B, C, D). These and other reaction patterns indicate a variable chemical composition of the mucus, consisting of neutral glycoprotein, carboxylated acid mucin, and

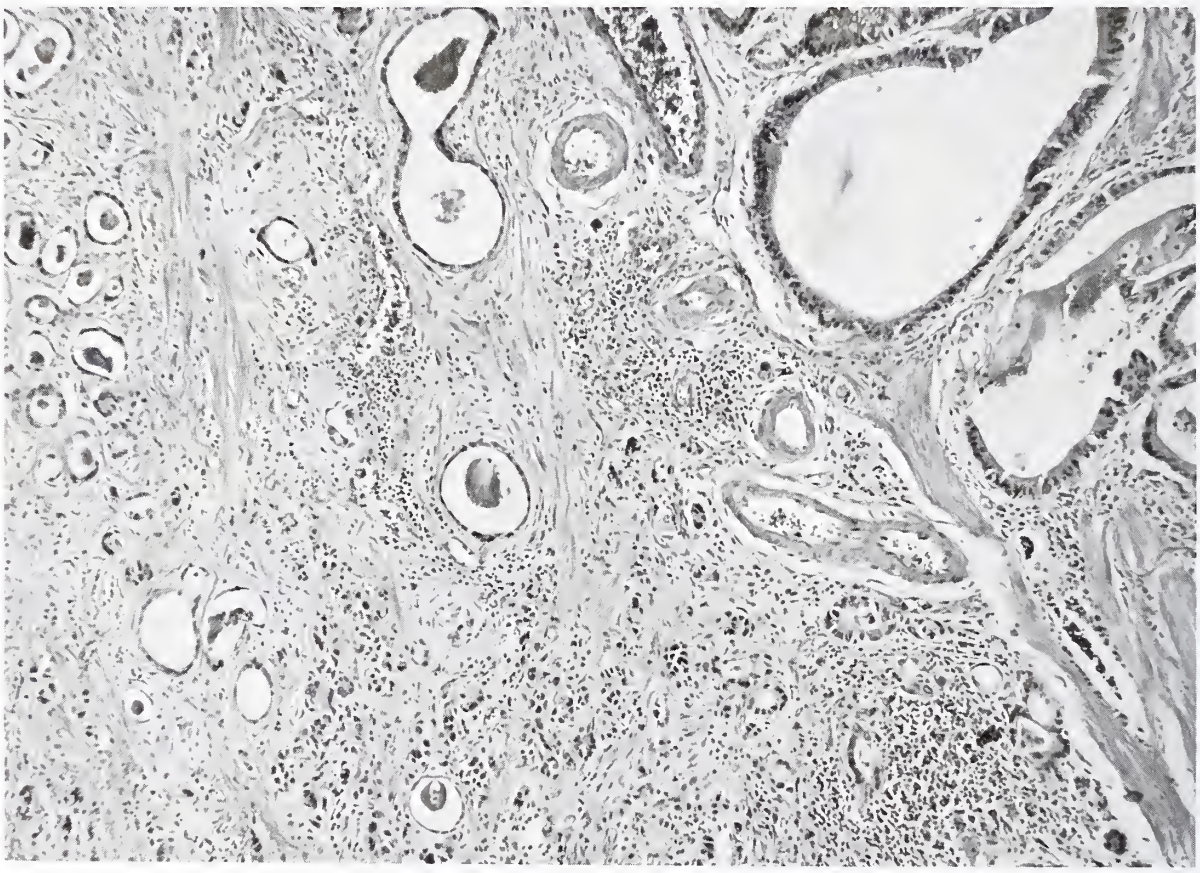

Fig. 171

ADENOCARCINOMA

This photomicrograph of an infiltrative carcinoma in the lesser curvature of the stomach in an 83-year-old woman shows varying degrees of gland formation, focal lymphocytic infiltration, and fibrosis. × 90.

occasionally sulfomucin. Enzyme histochemical studies (Lev et al.; Planteydt and Willighagen; Stemmermann) revealed the presence of intestinal enzymes such as alkaline phosphatase (fig. 180), aminopeptidase, and β-glucuronidase which are not observed in normal gastric mucosa. Many tumor cells gave negative reactions, however. Argentaffin and Paneth cells have also been found (Azzopardi and Pollock; Sasano et al.). Thus, gland-forming carcinoma cells have many features of intestinal metaplasia, but some have retained the characteristics of foveolar cells (Ming et al.; Sasano et al.). When this carcinoma is dominated by undifferentiated cells, these cells also remain in aggregates, forming solid bands or masses (figs. 181, 182). These tumors have been variously named carcinoma simplex, carcinoma solidum, or medullary carcinoma. The undifferentiated cells show some variation in size; most are low cuboidal or polyhedral with centrally located or eccentric nuclei and a fair amount of cytoplasm (figs. 182, 183).

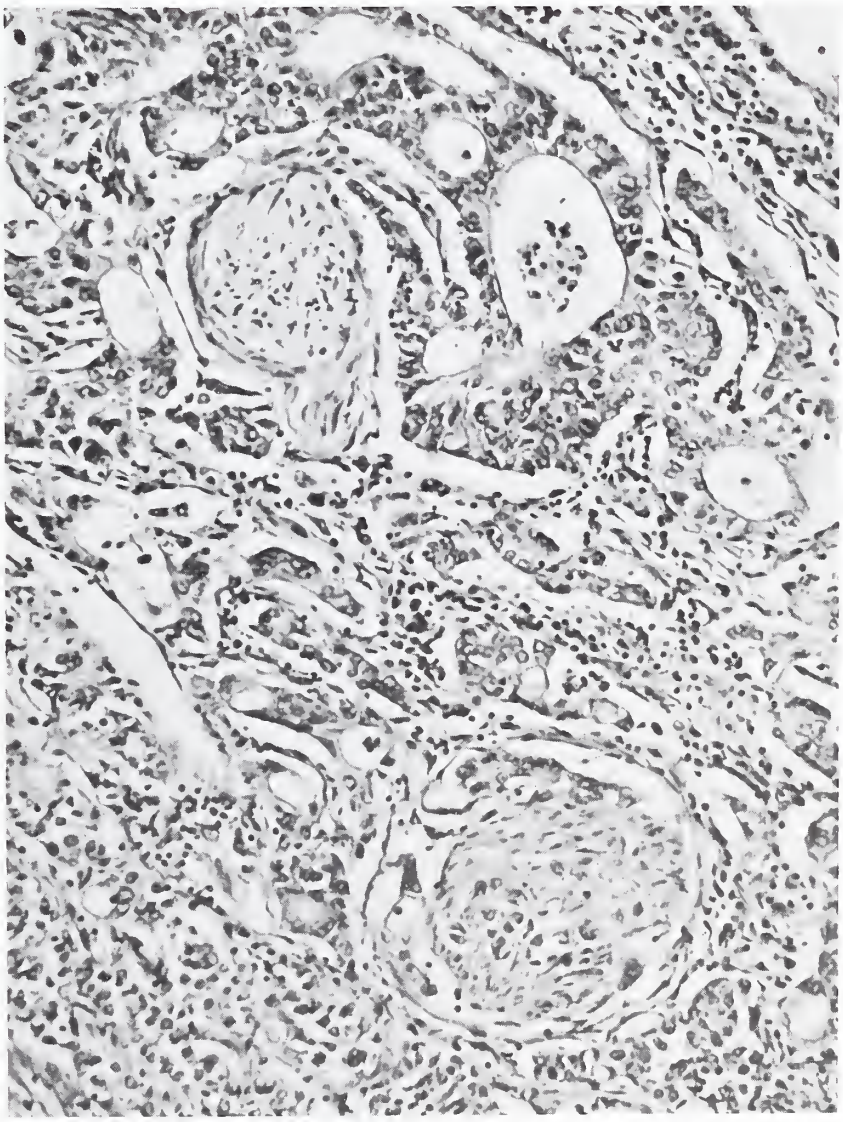

Fig. 172

ADENOCARCINOMA

A saucer-shaped, ulcerated, infiltrative carcinoma, measuring 8 cm. in diameter, was found in the pyloric area in a 66-year-old man. This photomicrograph of a section shows moderately differentiated tumor cells with perineural and neural invasion. × 168.

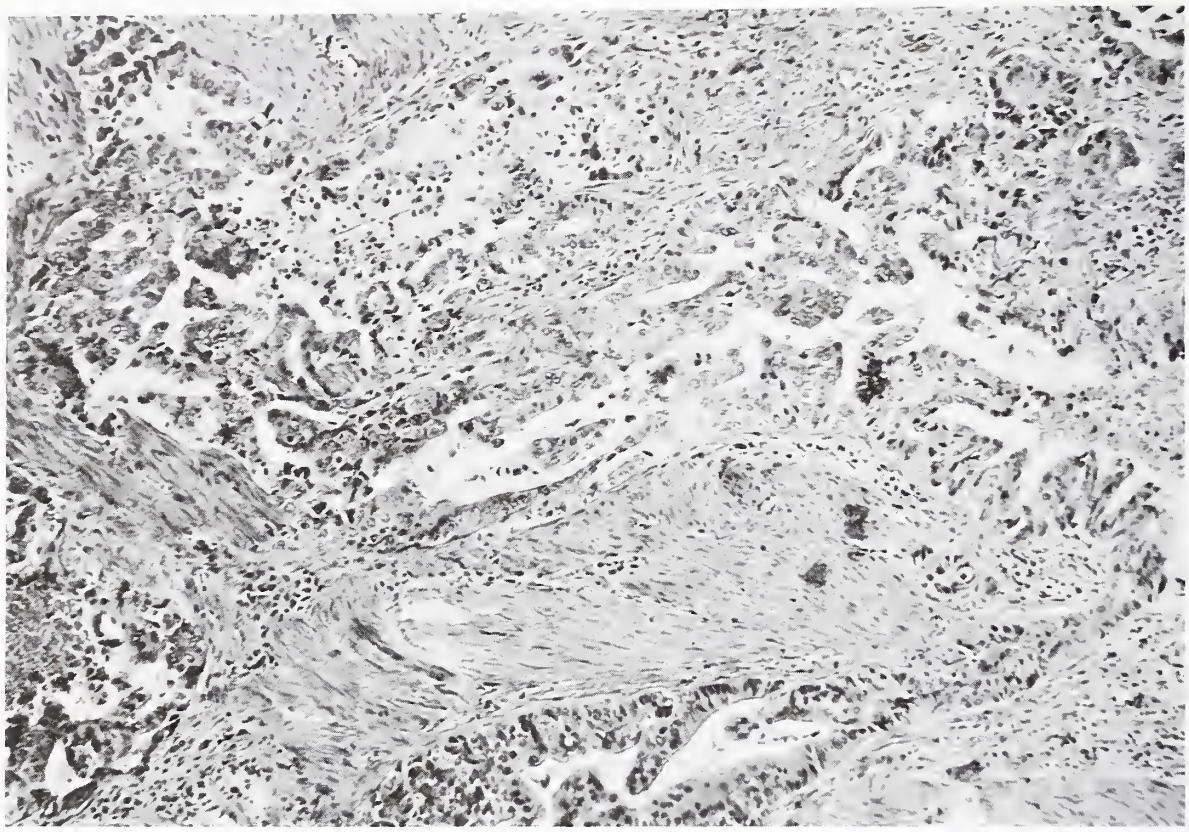

Fig. 173

PAPILLARY ADENOCARCINOMA

This photomicrograph of a fungating carcinoma in a 46-year-old man shows a well differentiated adenocarcinoma with intraluminal papillary projections. × 103

Fig 174

PAPILLARY ADENOCARCINOMA

This photomicrograph of two papillary tumor fragments reveals pronounced striated borders at the periphery and globules of intracellular and intraluminal mucin. Both these structures are stained with colloidal iron, shown in black. Mowry's colloidal iron technic. × 210.

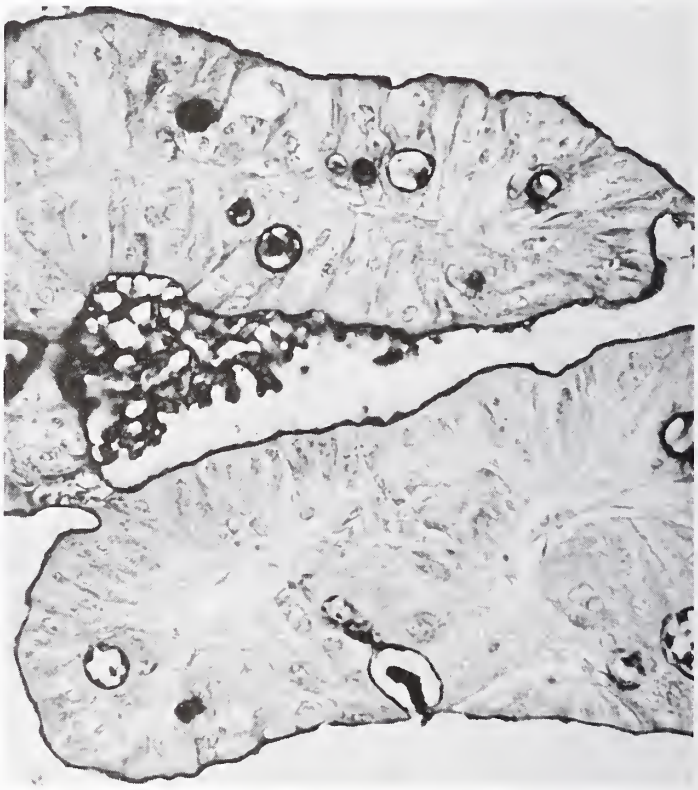

Fig 174

Fig 175

CYTOLOGIC APPEARANCE OF ADENOCARCINOMA

These adenocarcinoma cells from a gastric washing have eccentrically located, round or oval vesicular nuclei, prominent nucleoli, and foamy cytoplasm. × 1200

Fig 175

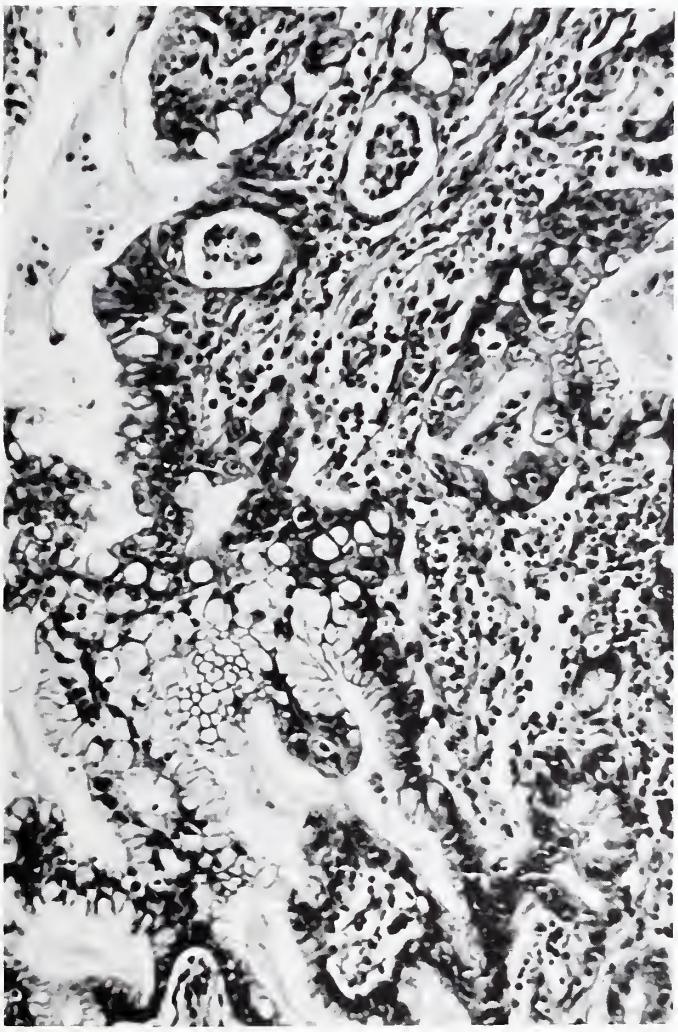

Fig 176

Fig 176

ADENOCARCINOMA WITH GOBLET CELLS

This is a photomicrograph of a polypoid carcinoma, measuring 3 x 2 x 1.5 cm., in the pyloric mucosa of a 66-year-old woman with pernicious anemia. In some areas such as this, there were many goblet cells. × 168

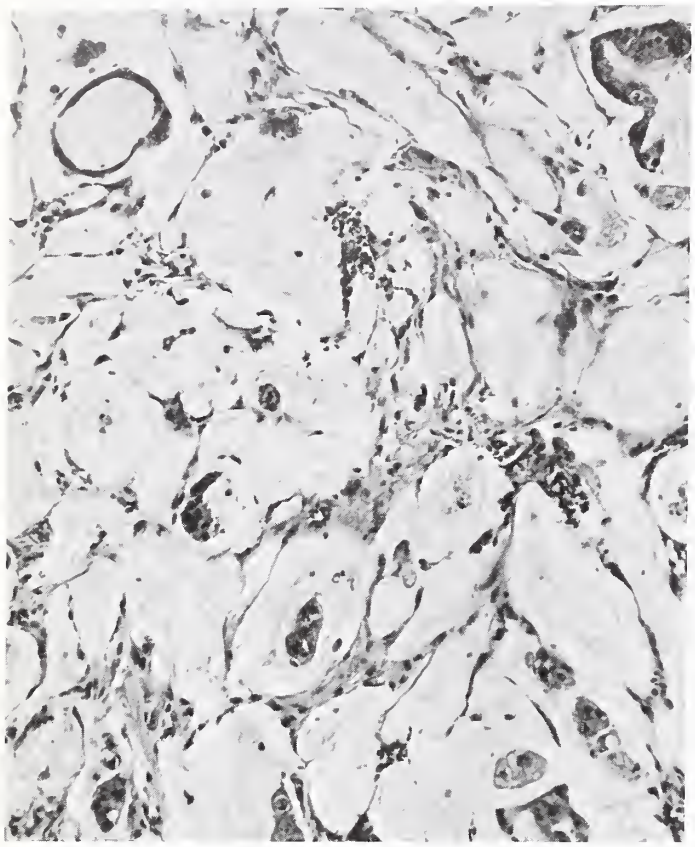

Fig 177

Fig 177

MUCINOUS ADENOCARCINOMA

A subtotally resected stomach from an 88-year-old man contained an ulcerated infiltrative carcinoma, measuring 7.5 x 4 x 3 cm., with an indurated margin and a nodular base. A photomicrograph of a section illustrates glandular elements surrounded by pools of mucin. × 134

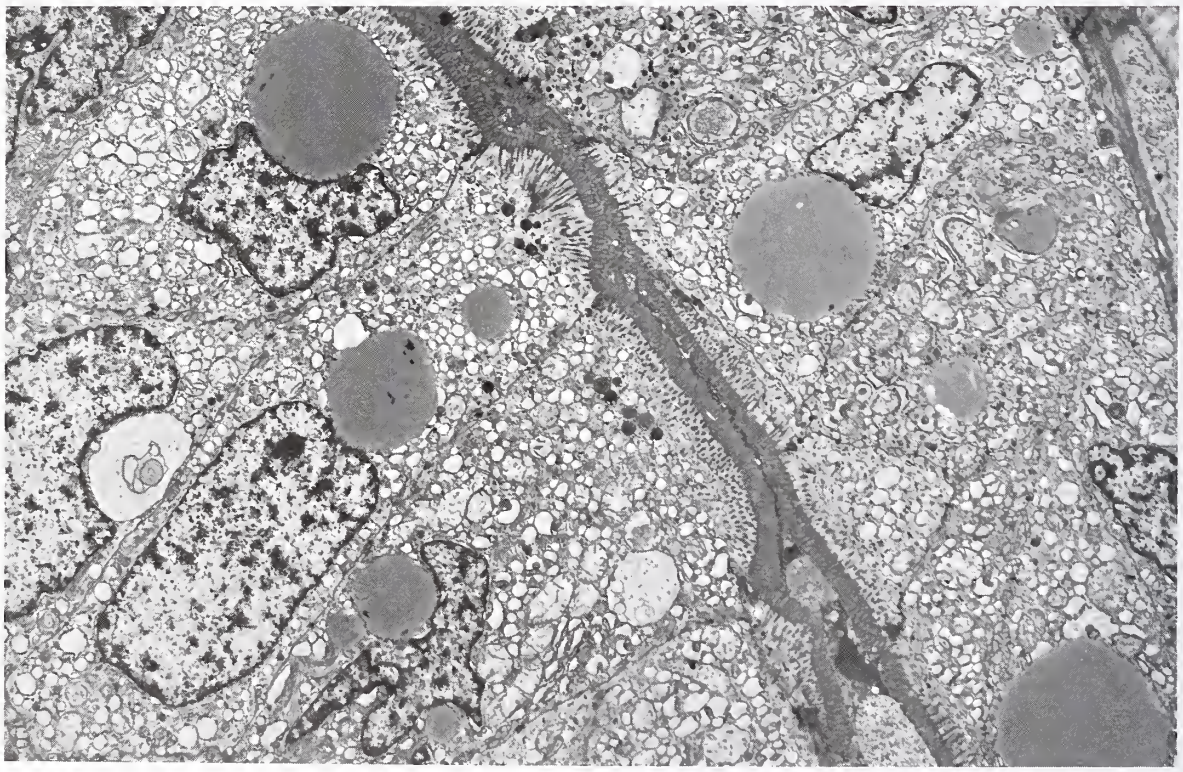

Fig 178

ADENOCARCINOMA

This electron micrograph of a moderately differentiated adenocarcinoma shows well developed microvilli forming striated borders, erratic terminal webs, large pale mucin globules, and dilated endoplasmic reticulum in the cytoplasm. × 3400 (Fig 7 from Goldman, H., and Ming, S.-C. Fine structure of intestinal metaplasia and adenocarcinoma of the human stomach. Lab Invest. 18:203–210, 1968.)

ADENOCARCINOMA

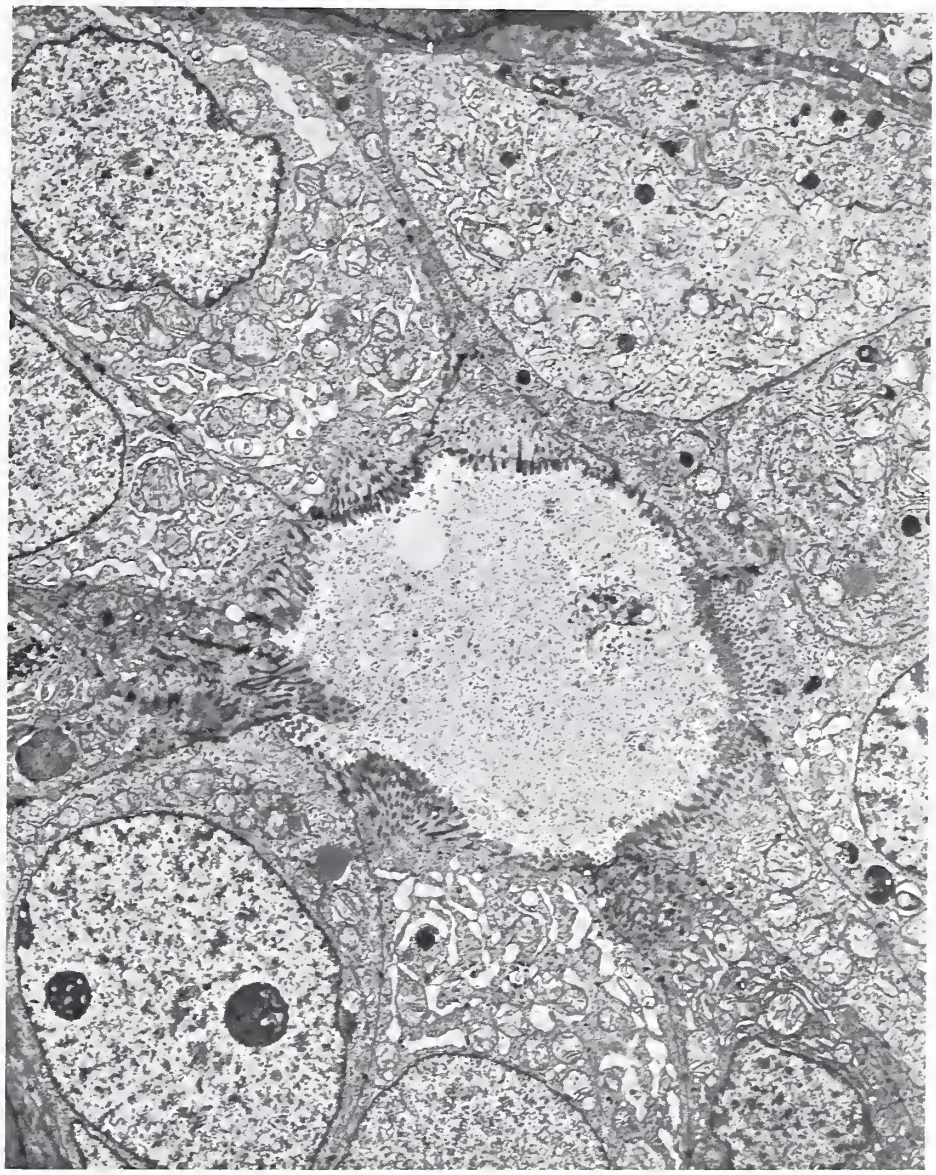

Fig. 179

This electron micrograph of a gland-forming carcinoma shows moderately developed microvilli, elongated terminal webs, and slightly dilated endoplasmic reticulum. Mucin granules are absent. × 4500. (Fig. 8 from Goldman, H., and Ming, S.-C. Fine structure of intestinal metaplasia and adenocarcinoma of the human stomach. Lab. Invest. 18: 203–210, 1968.)

PLATE III

EOSINOPHILIC GASTRITIS

(Plate III-A and Figure 84 from same case)

A. This photomicrograph of a section from the thickened pyloric antrum of a 55-year-old man shows numerous eosinophils and many plasma cells in sheets between the fibers of muscularis externa. The involved area measured 6 x 5 cm. and the gastric wall was 2 cm. thick. The mucosa was intact. Giemsa stain. × 320. (Courtesy of Dr. H. T. Enterline, Philadelphia, Pa.)

ADENOCARCINOMA OF STOMACH

(Plate III-B and C from same case)

B. This well differentiated adenocarcinoma reveals a positive periodic acid-Schiff reaction along the luminal border, in the cytoplasm of the tumor cells, and also in intraluminal secretion. × 125.

C. This is a parallel section of the same tumor stained with alcian blue at pH 2.5. The negative staining indicates that the periodic acid-Schiff positive material is neutral glycoprotein. × 125.

D. This well differentiated adenocarcinoma is stained with alcian blue at pH 2.5. The positive staining along the cell border and in the cytoplasm of tumor cells indicates the presence of acidic mucin. × 125.

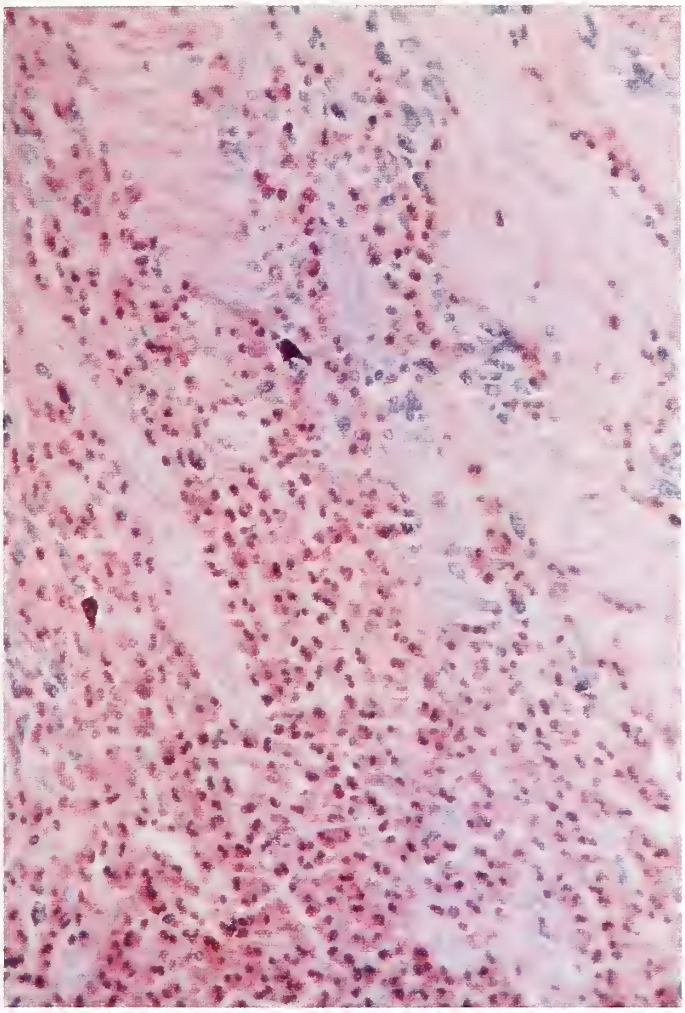

A

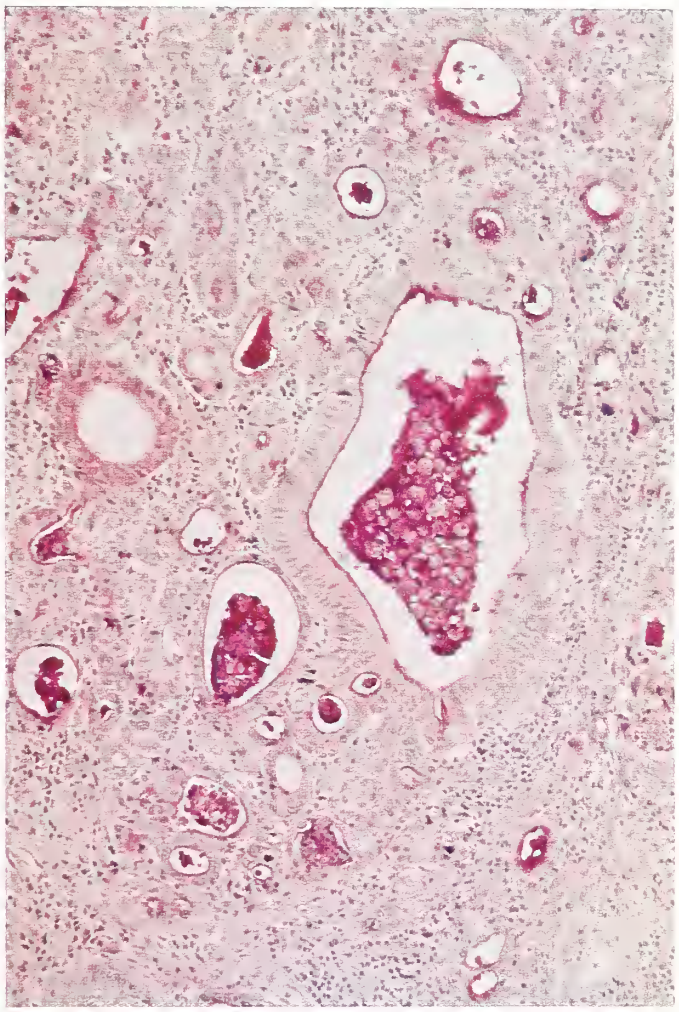

B

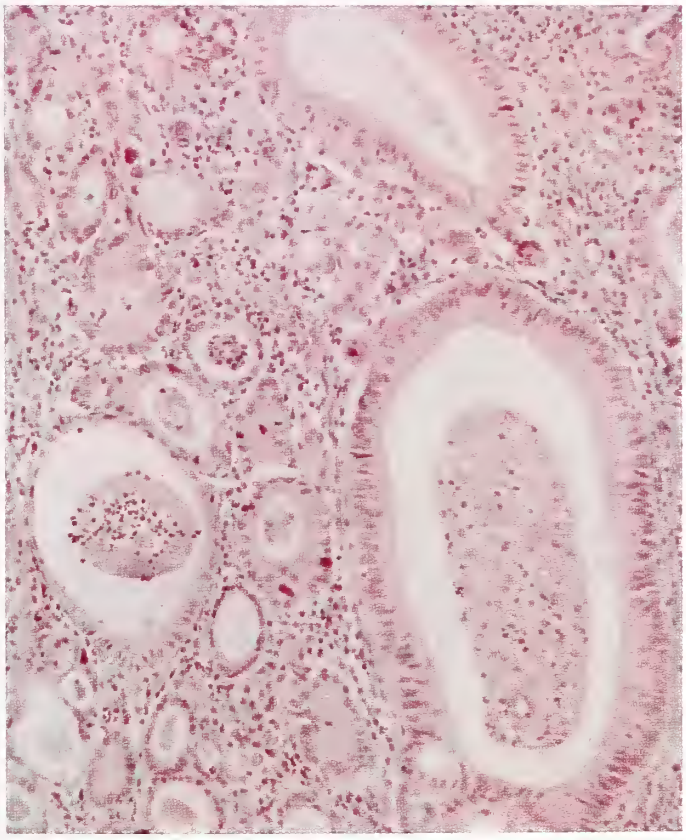

C



D

PLATE III

Fig 180

ADENOCARCINOMA WITH ALKALINE PHOSPHATASE

This is a photomicrograph of a cryostat section of well differentiated adenocarcinoma, stained for alkaline phosphatase using glycerophosphate as substrate. The black positive staining can be seen along the luminal border of the tumor cells. The capillary endothelium is also stained. × 350.

Fig. 181

UNDIFFERENTIATED CARCINOMA

This photomicrograph shows solid patches of undifferentiated tumor cells. There is no infiltration by individual cells. × 119.

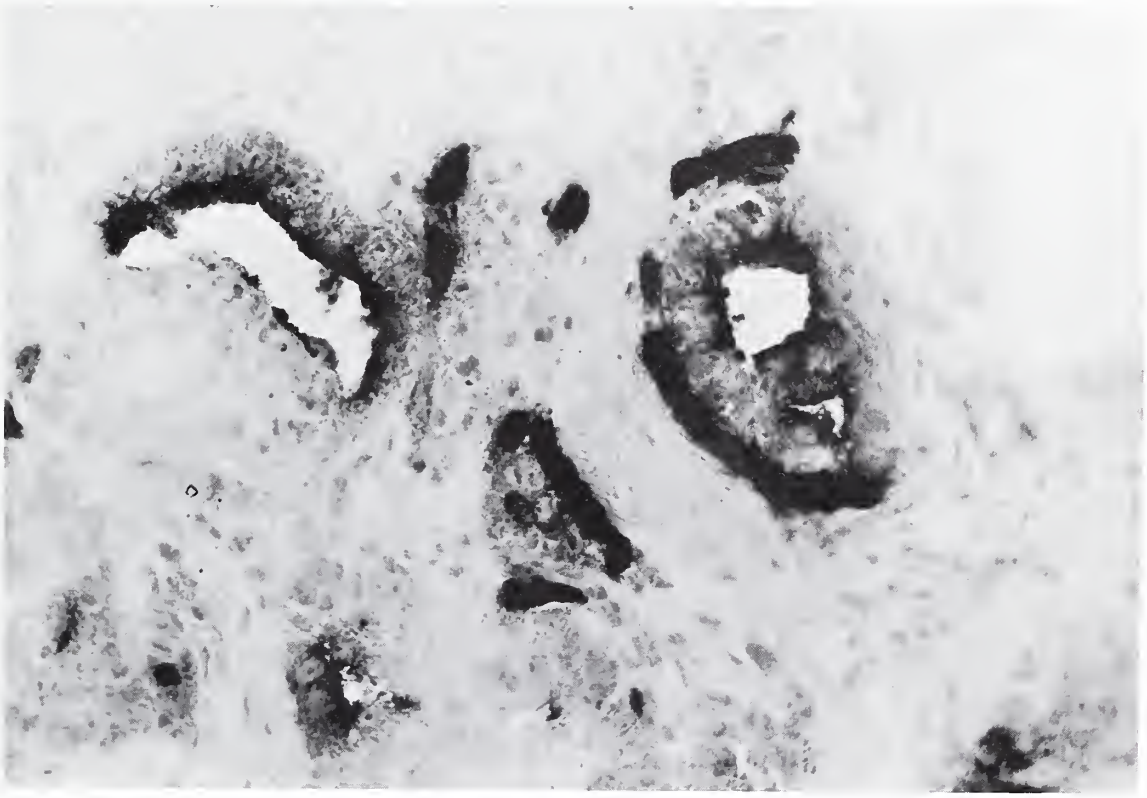

Fig 180

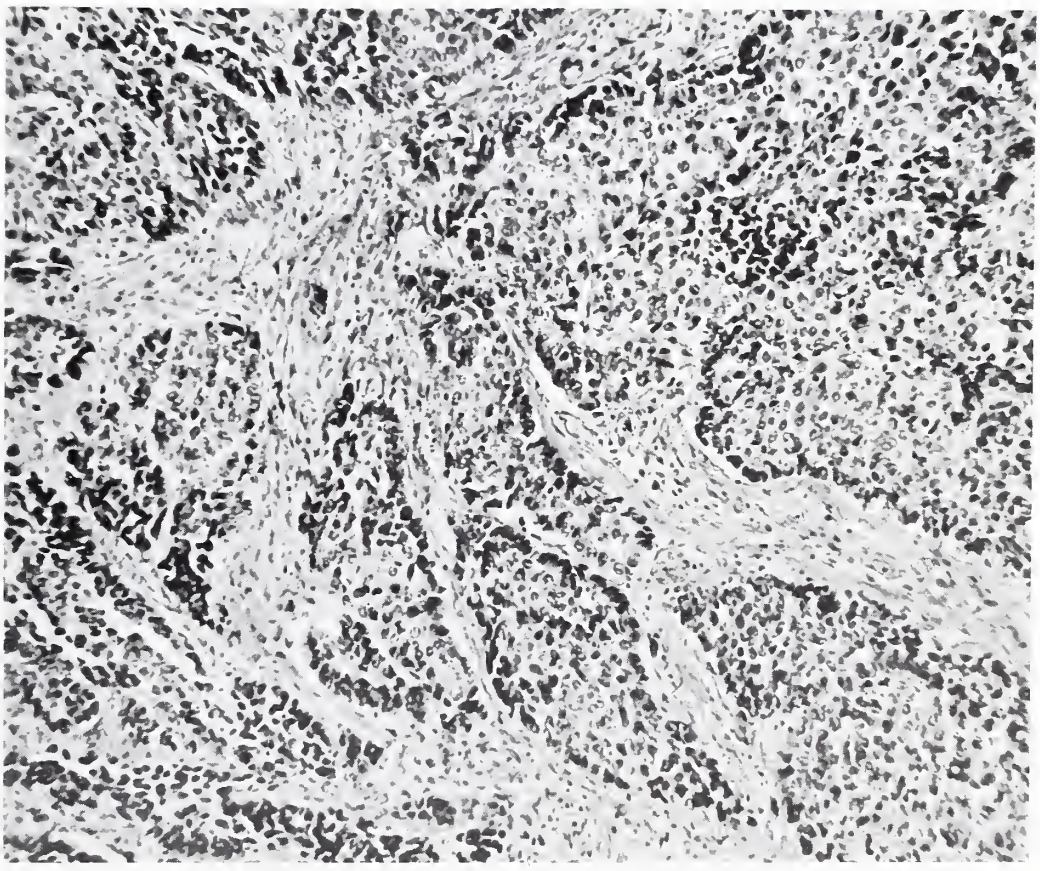

Fig 181

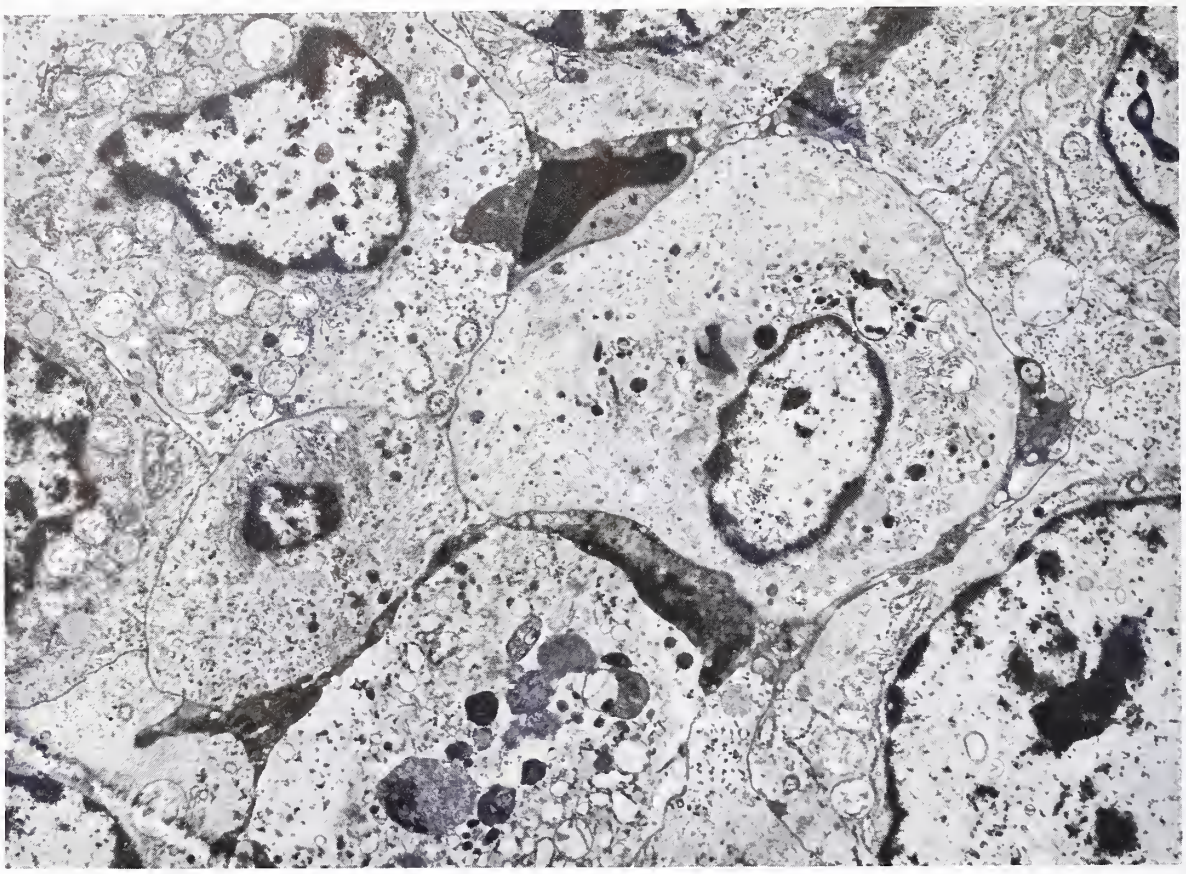

Fig. 182

UNDIFFERENTIATED CARCINOMA

An electron micrograph of a group of undifferentiated carcinoma cells reveals smooth cell membranes; there are neither microvilli nor mucin granules. Many lysosomes are present. × 5000. (Fig. 12 from Goldman, H., and Ming, S.-C. Fine structure of intestinal metaplasia and adenocarcinoma of the human stomach. Lab Invest. 18:203–210, 1968.)

Fig. 183

CYTOLOGIC APPEARANCE OF UNDIFFERENTIATED CARCINOMA

A 67-year-old man had a fungating carcinoma in the distal part of the stomach, measuring 9 cm. in greatest dimension, composed partly of poorly differentiated adenocarcinoma and partly of undifferentiated carcinoma. This photomicrograph shows cells from the gastric washing that are variable in size, their nuclei are round or oval, with clumped chromatin, and the moderate amount of cytoplasm is finely granular. × 850.

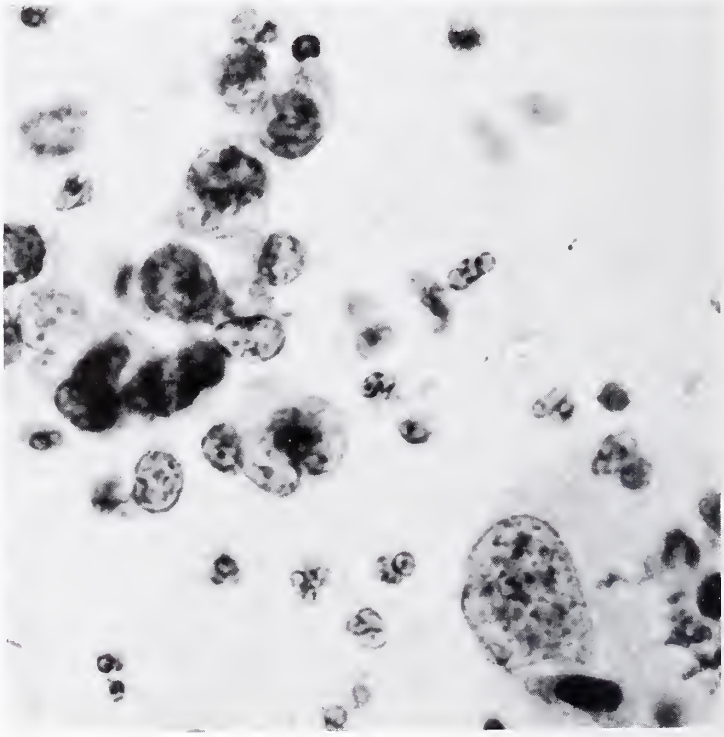

Fig. 183

Tumor cells that tend to infiltrate the tissue individually also show varying degrees of differentiation. Well differentiated cells having large amounts of intracellular mucinous material compressing the nuclei to the cell border are known as signet ring cells (figs. 184, 185). Some of these cells also take the form of goblet cells (fig. 186).

Fig 184

SIGNET RING CELL CARCINOMA

This is a photomicrograph from the mucosa of a stomach with diffuse carcinoma extensively infiltrated by isolated tumor cells throughout the gastric wall. Individual tumor cells are shown in the mucosa. No intestinal metaplasia was present in adjacent glands. PAS stain. × 268

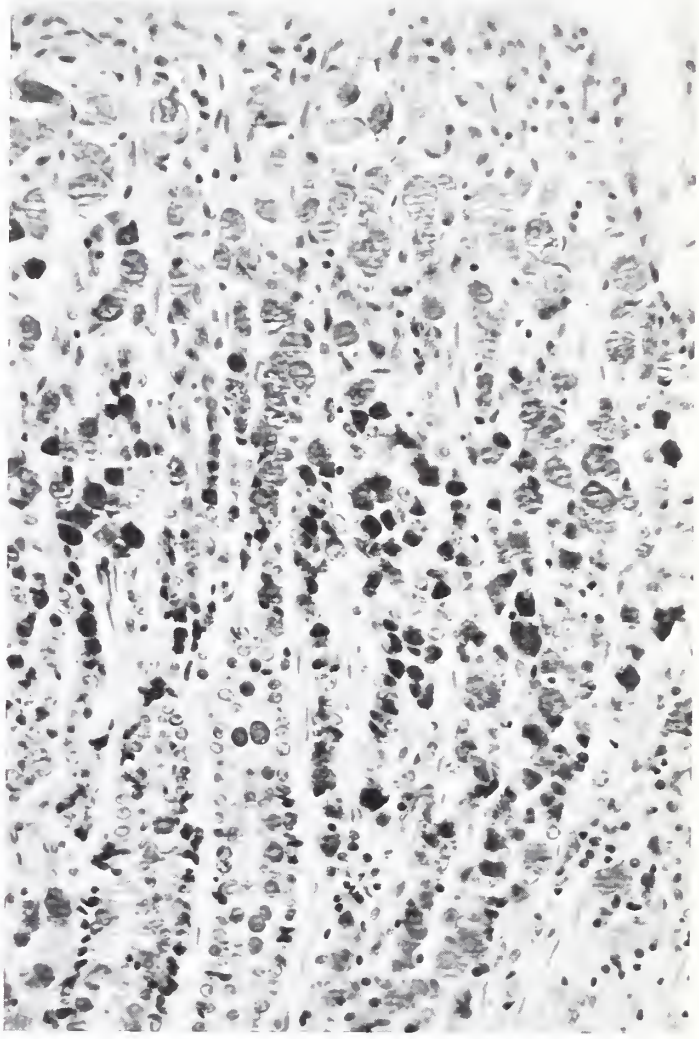

Fig 184

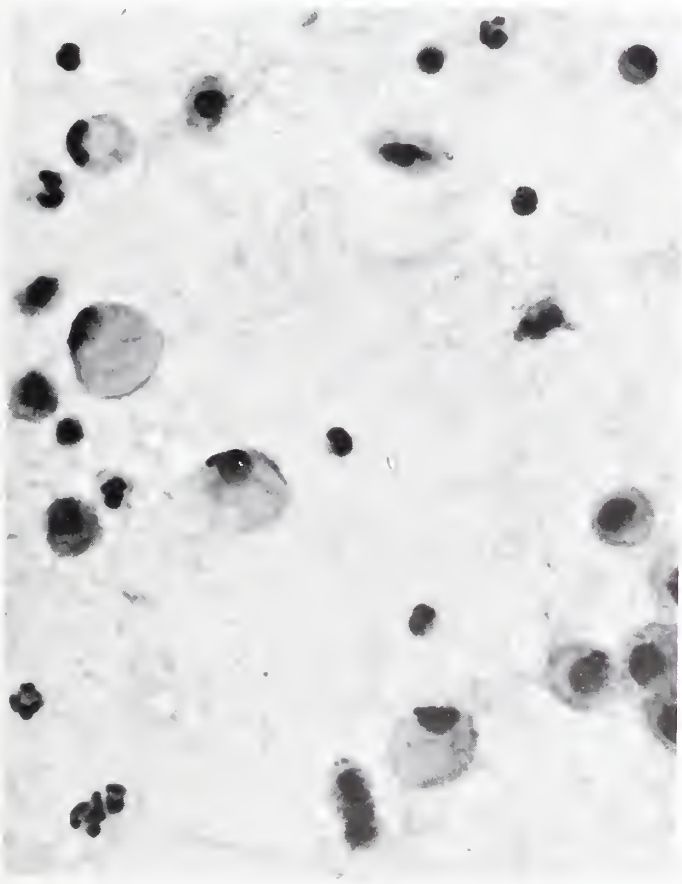

Fig 185

Fig 185

CYTOLOGIC APPEARANCE OF SIGNET RING CELL CARCINOMA

A 50-year-old woman had a partial gastrectomy for extensive superficial signet ring cell carcinoma in the stomach, with focal invasion into the submucosa and lymphatics. Ascites developed eight months later. This photomicrograph of cells found in the peritoneal fluid shows a few signet ring cells that have nuclei compressed against the cell membrane, mesothelial cells with central nuclei and smaller amounts of cytoplasm, and scattered inflammatory cells. × 610.

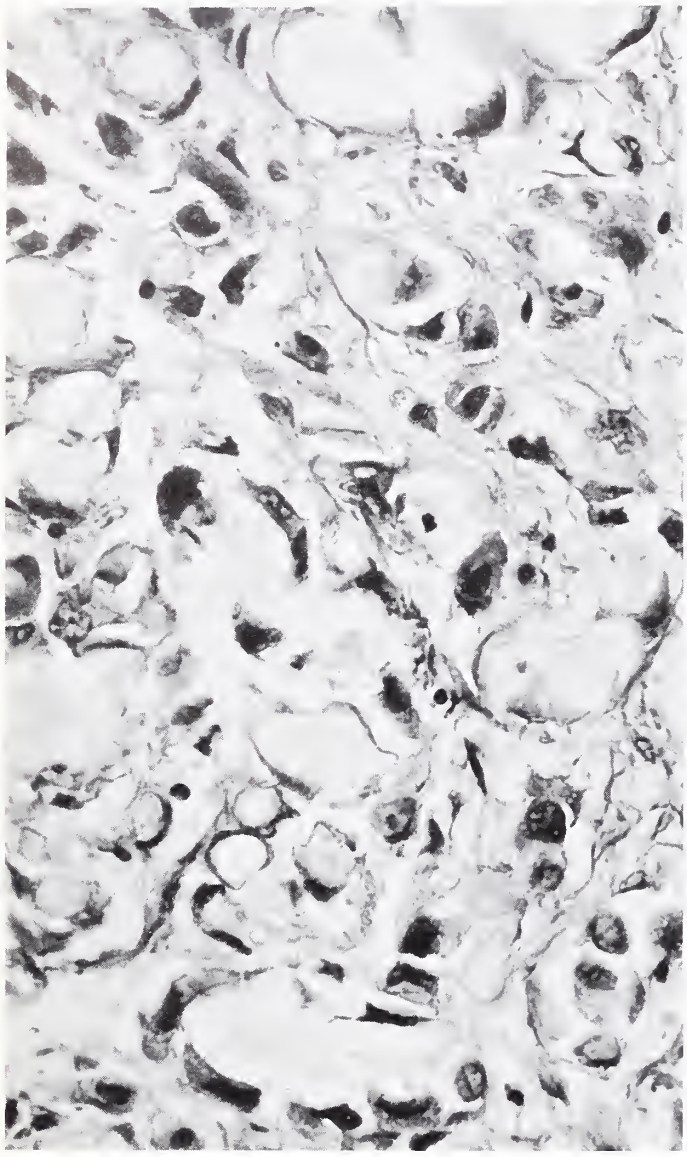

Fig. 186

Fig. 186

SIGNET RING CELL CARCINOMA

This photomicrograph of a group of loosely gathered mucin-producing tumor cells reveals that some are signet ring-shaped or goblet-shaped, and others are over-distended with mucin. × 415.

Occasionally, they form loosely gathered, small groups (pl. IV–A, B) and rarely they produce small glandular structures which resemble pyloric glands because of their basally located nuclei and granular cytoplasm (fig. 187). When examined under the electron microscope, only a few microvilli are present and the mucin granules are small and light. Mucin granules stain strongly with periodic acid-Schiff reaction and many stain positively with alcian blue; some granules, however, are alcian blue negative (pl. IV–A, B). These latter cells often have eosinophilic fine granules, whereas other cells contain large globules of slightly basophilic material. Excessive mucin secretion sometimes also results in formation of mucinous carcinoma. Occasional tumor cells may give positive argentaffin reaction (Kubo and Watanabe). Undifferentiated tumor cells of this type are commonly seen in the same tumor with abundant signet ring cells (fig. 188), and occasionally they are seen as the sole cellular constituent. These cells are small and polyhedral, sometimes elongated, with a comparatively large nucleus and scanty cytoplasm (fig. 189). When seen in aggregates, they may be mistaken for lymphoma cells. This type of carcinoma exhibits strong invasive ability even in the early stages (fig. 190), and in situ lesions are rarely found.

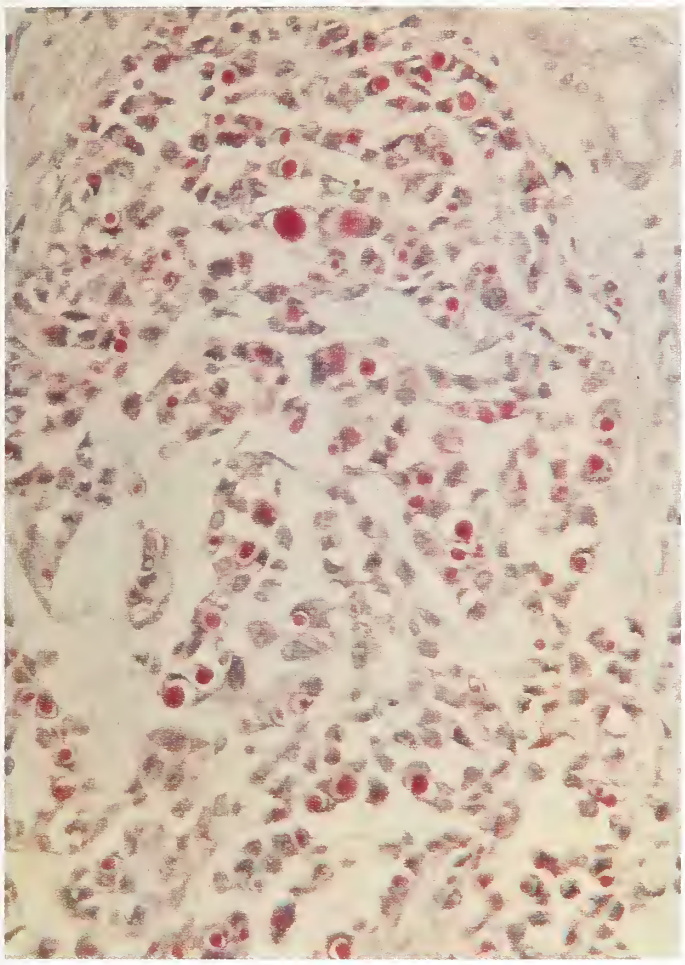

A

SIGNET RING CELL CARCINOMA OF STOMACH

(Plate IV-A and B from same case)

A This group of loosely aggregated tumor cells stained with periodic acid-Schiff reaction shows intense positive reaction of the intracellular secretion. × 320.

SIGNET RING CELL CARCINOMA OF STOMACH

(Plate IV-A and B from same case)

B This parallel section of the same tumor is stained with alcian blue at pH 2.5. A few cells show positive staining, indicating the presence of acidic mucin, many others are negative, indicating that the periodic acid-Schiff positive material in these cells is neutral glycoprotein. × 320

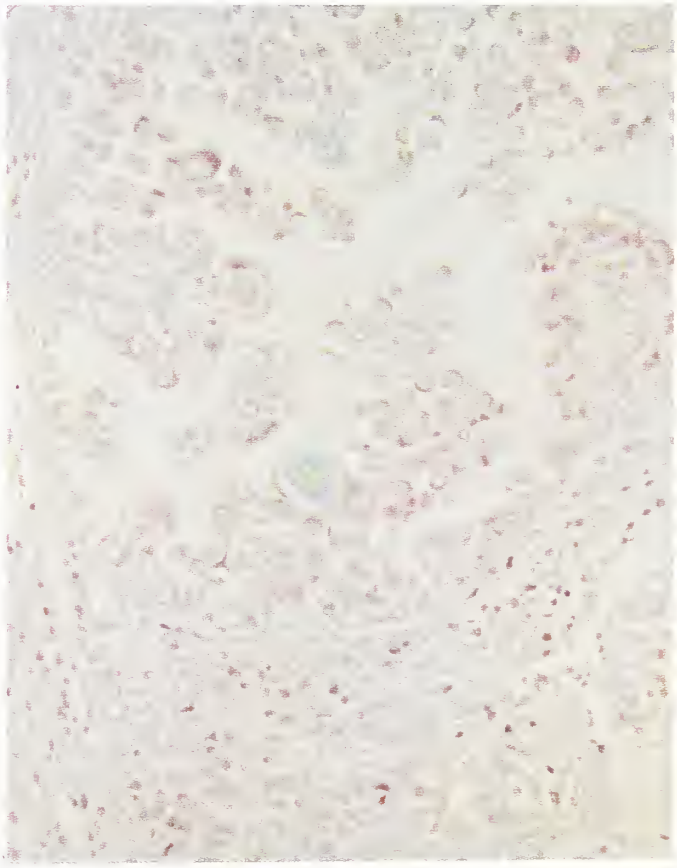

B

PLATE IV

Fig. 187

SIGNET RING CELL CARCINOMA WITH PYLORIC TYPE GLANDS

A diffuse carcinoma involved the entire stomach of a 35-year-old woman. There was marked thickening of the gastric wall and infiltration of prominent mucosal folds by tumor cells. There was no intestinal metaplasia. Many single signet ring cells are seen in this photomicrograph, and many glandular structures are composed of the same type cells with eccentric nuclei and granular cytoplasm. Most of these glands stained strongly with alcian blue although their morphologic appearance resembles pyloric glands. × 110.

Fig. 188

SIGNET RING CELL CARCINOMA

(Figures 135, 136, and 188 from same case)

This higher magnification of the tumor illustrated in figure 135 shows isolated tumor cells infiltrating the muscularis externa Some of the cells are small signet ring cells; most of them are undifferentiated, with darkly stained nuclei and scanty cytoplasm. × 190.

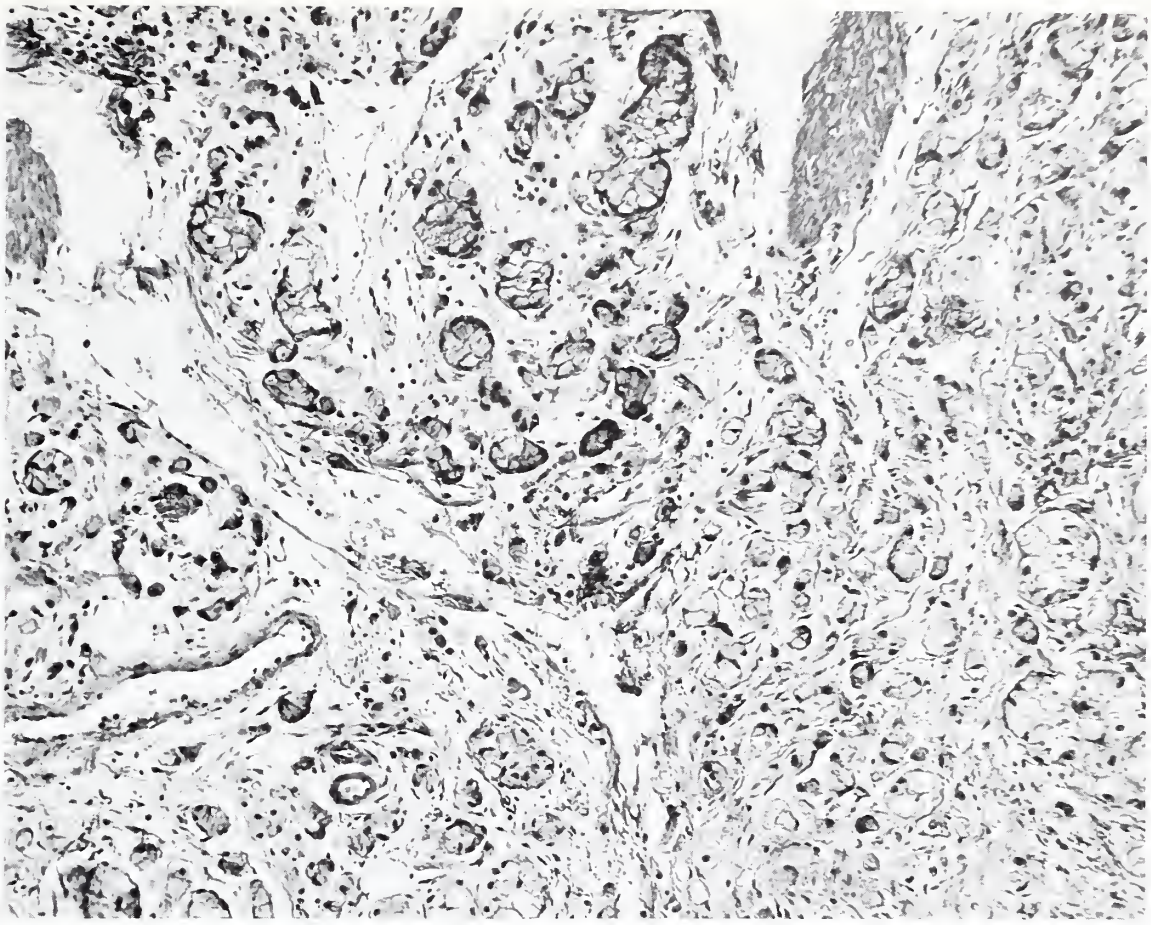

Fig 187

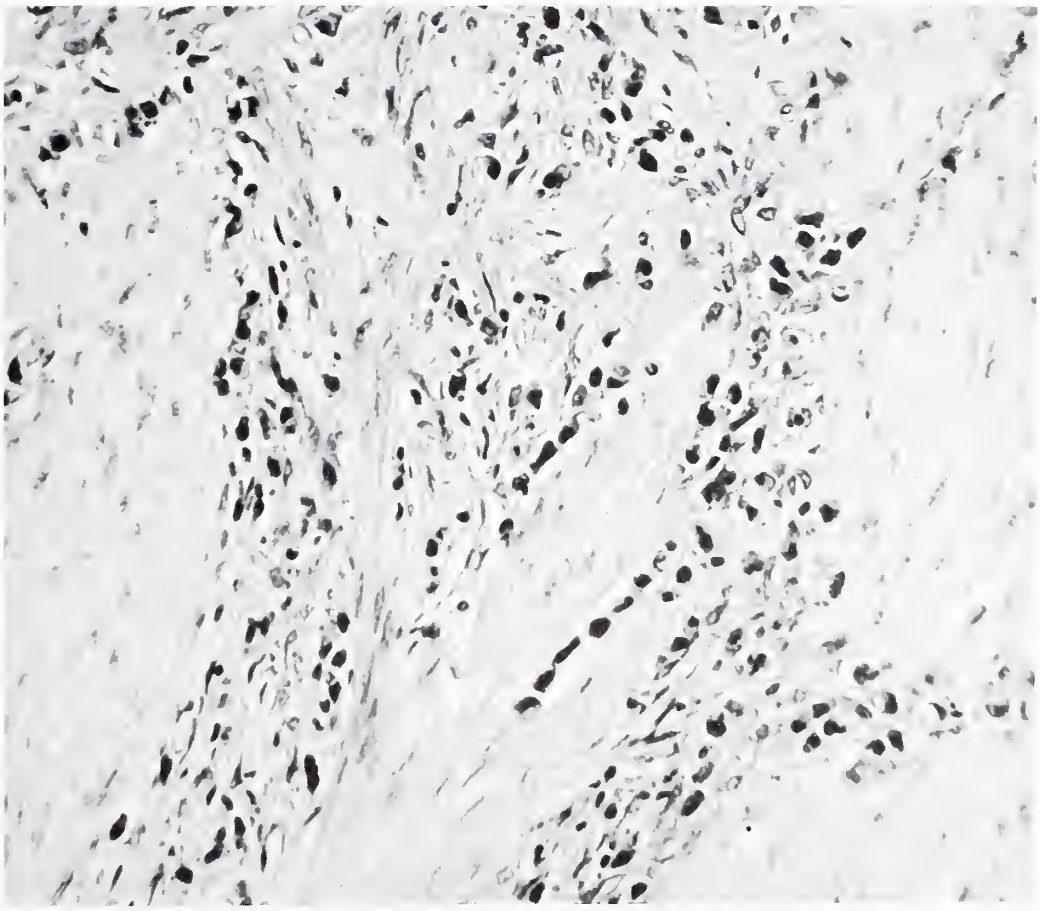

Fig 188

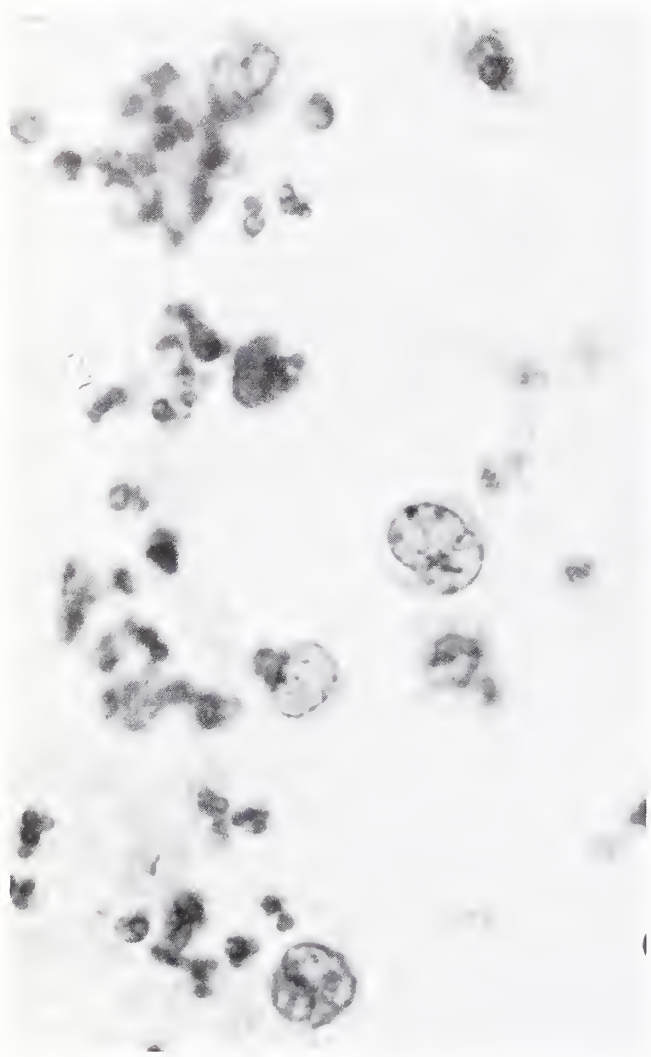

Fig 189

CYTOLOGIC APPEARANCE OF UNDIFFERENTIATED CARCINOMA

A 64-year-old woman had an extensive carcinoma of the stomach. Biopsy revealed numerous isolated undifferentiated tumor cells in the mucosa and submucosa. These cells from the gastric washing have round or oval, somewhat lobulated, vesicular nuclei and scanty amounts of cytoplasm. × 850.

Glandular tumor cells are clearly related to metaplastic cells and early carcinoma is often seen in the area of intestinal metaplasia (Nakamura et al.). The individually infiltrating tumor cells also have features of metaplasia, but they are often seen in stomachs without significant intestinal metaplasia (figs. 135, 190). They may arise from nonmetaplastic foveolar cells, neck mucous cells, or even pyloric gland cells. Since gastric carcinomas are multicellular in origin, different cell types may be present within the same tumor. When this occurs, the biologic behavior is usually determined by the dominant cell type. Laurén attempted to divide gastric carcinomas on a similar cellular basis into two groups: an intestinal type carcinoma and a diffuse type carcinoma. The former constituted 53 percent and the latter 33 percent of carcinomas; in 14 percent of tumors the distinction could not be made. The multicellular origin of gastric carcinoma also makes it difficult to correlate microscopic with gross appearances of the tumor. While glandular tumor cells are usually prominent in carcinomas with large intraluminal growth and isolated tumor cells in those with mainly intramural growth, this correlation is not always possible. Eker and Efskind used the term scirrhous carcinoma on the histologic rather than the gross basis for the isolated cell type. They found this histologic pattern in 54 percent of diffuse carcinomas, 16 percent of ulcerated infiltrative carcinomas, and 6 percent of papillary and nodular carcinomas.

References

Azzopardi, J. G., and Pollock, D. J. Argentaffin and argyrophil cells in gastric carcinoma. J. Path. Bact. 86: 443–451, 1963.

Collins, W. T., and Gall, E. A. Gastric carcinoma. A multicentric lesion. Cancer 5: 62–72, 1952.

Eker, R., and Efskind, J. The pathology and prognosis of gastric carcinoma. Based on 1314 partially and totally resected cases. Acta Chir. Scand. Suppl. 264: 1–182, 1960.

Goldman, H., and Ming, S.-C. Fine structure of intestinal metaplasia and adenocarcinoma of the human stomach. Lab. Invest. 18: 203–210, 1968.

———, and Ming, S.-C. Mucins in normal and neoplastic gastrointestinal epithelium. Histochemical distribution. Arch. Path. 85: 580–586, 1968.

Järvi, O., and Laurén, P. On the role of heterotopias of the intestinal epithelium in the pathogenesis of gastric cancer. Acta Path. Microbiol. Scand. 29: 26–44, 1951.

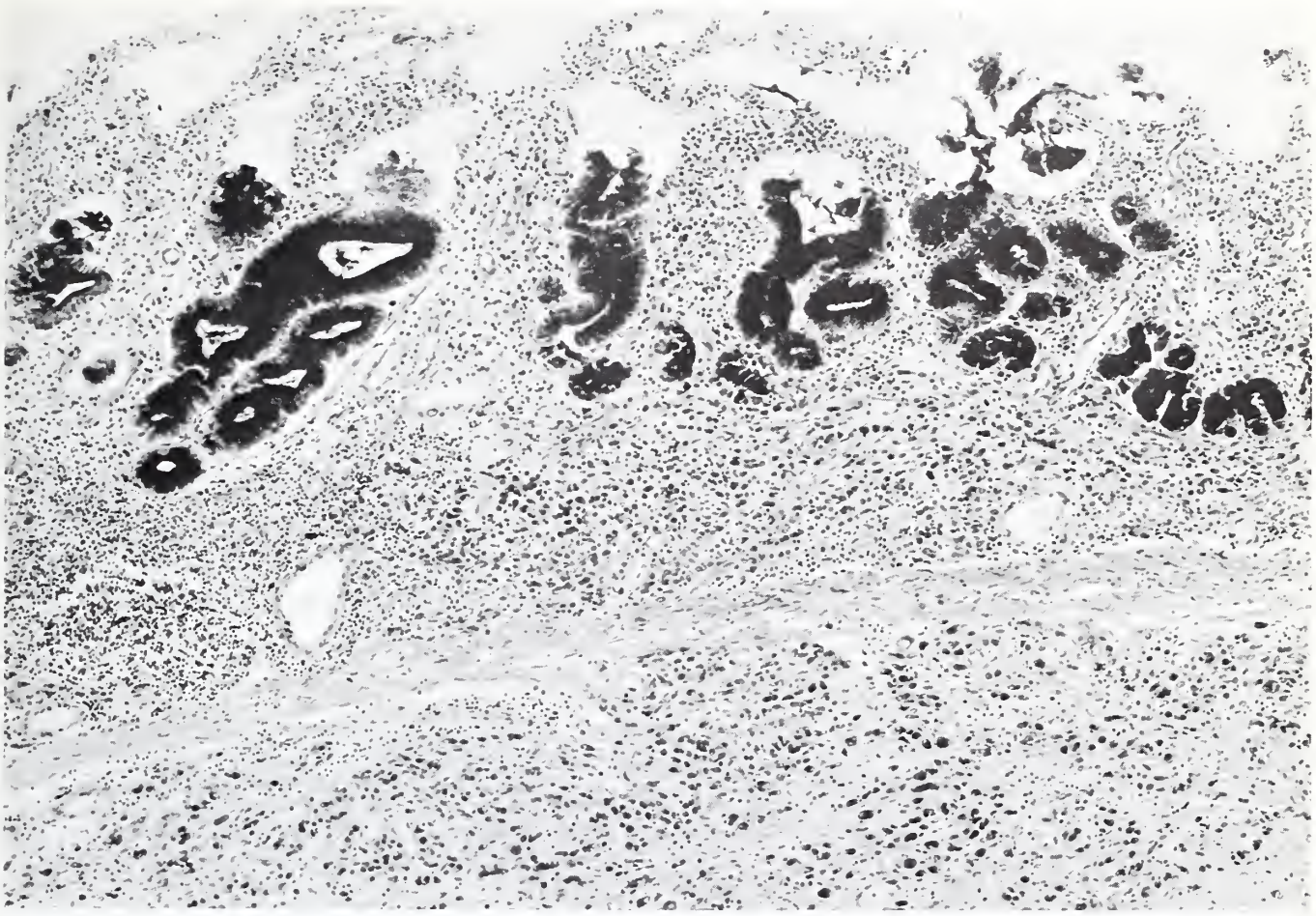

Fig 190

SIGNET RING CELL CARCINOMA

A small carcinoma was found in the distal fundic mucosa of the stomach of a 19-year-old woman who died of rheumatic heart disease. The tumor, 1 cm. in diameter, involved the mucosa and submucosa only. Most of the cells were signet ring-shaped and showed uniformly strong periodic acid-Schiff reaction; many were also stained by alcian blue at pH 2.5. This photomicrograph reveals tumor cells in the submucosa and deep portion of the mucosa where gastric glands are absent. The foveolar cells appear normal. In other areas, the mucosa showed only focal mild atrophy and chronic interstitial inflammation. There was no intestinal metaplasia. PAS stain. × 75.

Kubo, T., and Watanabe, H. Neoplastic argentaffin cells in gastric and intestinal carcinomas. Cancer 27 447–454, 1971.

Lauren, P. The two histological main types of gastric carcinoma: diffuse and so-called intestinal-type carcinoma. An attempt at a histo-clinical classification. Acta Path. Microbiol. Scand. 64 31–49, 1965.

Lev, R., Siegel, H. I., and Jerzy Glass, G. B. The enzyme histochemistry of gastric carcinoma in man. Cancer 23 1086–1093, 1969.

Ming, S.-C., Goldman, H., and Freiman, D. G. Intestinal metaplasia and histogenesis of carcinoma in human stomach. Light and electron microscopic study. Cancer 20 1418–1429, 1967.

Nakamura, K., Sugano, H., and Takagi, K. Carcinoma of the stomach in incipient phase: its histogenesis and histological appearances. Gann 59 251–258, 1968.

Planteydt, H. T., and Willighagen, R. G. J. Enzyme histochemistry of gastric carcinoma. J. Path. Bact. 90 393–398, 1965.

Sasano, N., Nakamura, K., Arai, M., Akazaki, K. Ultrastructural cell patterns in human gastric carcinoma compared with non-neoplastic gastric mucosa—histogenetic analysis of carcinoma by mucin histochemistry. J. Nat. Cancer Inst. 43 783–802, 1969.

Stemmermann, G. N. Comparative study of histochemical patterns in non-neoplastic and neoplastic gastric epithelium. A study of Japanese in Hawaii. J. Nat. Cancer Inst. 39 375–382, 1967.

Stout, A. P. Tumors of the Stomach. Fascicle 21, Atlas of Tumor Pathology. Washington: Armed Forces Institute of Pathology, 1953.

SPREAD OF CARCINOMA. Gastric carcinomas are highly infiltrative tumors and by the time they are examined pathologically, the majority have extended into the subserosa. At the cardiac end, the tumor infiltrates freely into the esophagus, both along the mucosal surface and within the wall. At the distal end, the lesion often appears to end sharply at the duodenum on gross examination; however, microscopically, tumor extension into the duodenum is not uncommon. Of 833 subtotally resected specimens, Majima and associates found duodenal invasion by gastric carcinoma in 18 percent of cases, and twice as frequently when the carcinoma was located less than 1 cm. from the pyloric ring. The duodenal invasion was mostly subserosal and the mucosa was not involved. The reason for the latter phenomenon is not known. Rarely did intramural spread of a highly infiltrative carcinoma involve the other parts of the small intestine and colon as reported by Fernet and associates. Lymphatic invasion by tumor is commonly seen, and occasionally blood vessel invasion is also noted (fig. 191). Vascular invasion probably occurs more frequently than is generally realized. Destruction of the vessel wall obscures this feature unless an elastic tissue stain is applied to the tissue sections. Takayama and Toda found cancer cells in the peripheral blood prior to surgery in 30 percent of cases, and in the blood draining the site of the carcinoma during surgery in 49 percent of cases. Carcinoma often extends to the gastric serosa from which the tumor cells may implant on the other parts of the peritoneum.

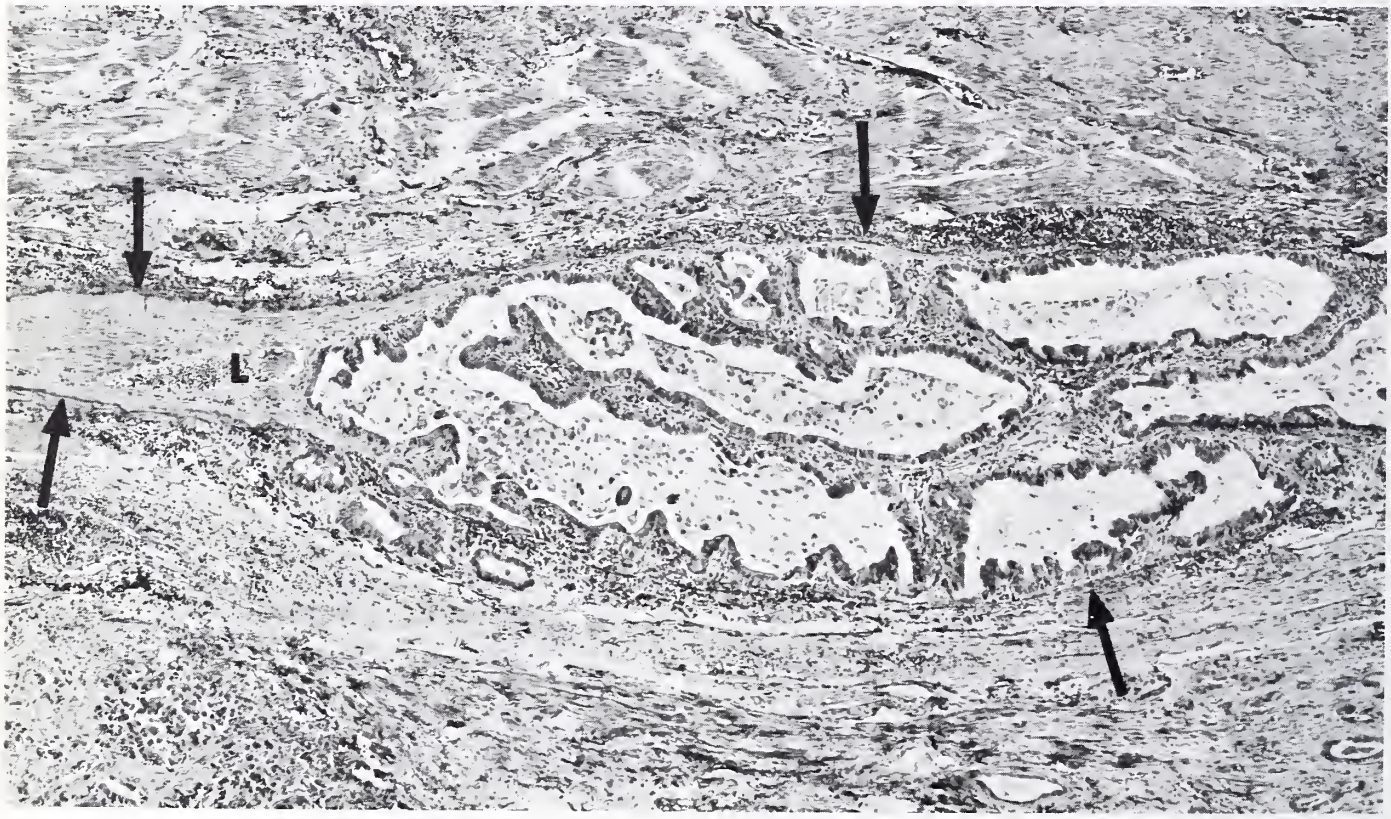

Fig 191

BLOOD VESSEL INVASION

A 46-year-old man had a fungating carcinoma in the proximal part of the stomach with metastases to lymph nodes. This is a photomicrograph of a portion of a longitudinal section of vein in the subserosa, identified by remaining elastic tissue (arrows). The lumen is occluded by the gland-forming tumor and much of the media of the vein has been destroyed. L indicates the venous lumen containing red blood cells. Verhoeff's elastic tissue stain. × 57.

Metastases in the regional lymph nodes are common in surgically resected stomachs, particularly in total gastrectomy specimens (Ringertz). Sunderland made a careful study of 100 specimens and found lymph node metastases in 88 percent of cases. The frequency of nodal involvement at either end of the stomach was related to the location of the tumor. Overall, the superior gastric nodes were most frequently involved in gastric carcinoma. Pancreatic and splenic nodes showed metastases only when the tumor involved the midportion of the stomach. The frequency of metastases to lymph nodes is related to the size and degree of penetration of the primary tumor. Comfort and associates reported that lymph node metastases were present in 43 percent of patients with primary tumors measuring up to 4 cm. in diameter. Friesen and associates found lymph node metastases in 6 percent of patients with superficial carcinomas. Involvement of the left supraclavicular nodes (Virchow node) was present in 5 to 15 percent of cases reported by Ringertz.

At necropsy, lymph node metastases were found in 80 to 90 percent of cases (Ringertz). At the University of Maryland Hospital, a 74 percent incidence was found among 80 cases examined; 10 showed no metastasis, and gastric carcinoma was an incidental finding in 5 of the 10 cases. In 40 percent of cases, there was peritoneal seeding, and in 35 percent of cases metastatic lesions were present in the liver or lungs. Frequency of metastases in other organs was as follows: adrenal, 19 percent; pancreas, 17 percent; retroperitoneum, 12 percent; ovary, 10 percent; bone, mainly vertebrae, 10 percent; uterus,

Fig. 192

GASTRIC CARCINOMA WITH METASTASES TO OVARIES (KRUKENBERG'S TUMOR)

This illustrates an infiltrative carcinoma involving the pyloric portion of the stomach with metastases to the bisected ovaries. The ovary on the right is slightly enlarged and the opposite ovary is about three times its normal size. Both ovaries have retained the general configuration of normal ovaries. (Courtesy of Beth Israel Hospital, Boston, Mass.)

8 percent; kidney, 6 percent; spleen, brain, and pericardium, 4 percent each; heart, pituitary, and urinary bladder, two cases each; and prostate, one case.

Ovarian metastases are usually associated with highly infiltrative carcinoma (fig. 192). Enlarged ovaries containing signet ring, mucin-secreting cells have been known as Krukenberg tumors, and are most often associated with primary gastric carcinoma. These tumors are of interest because they may appear long before the primary tumor is manifest, and because there may be endocrine dysfunction of ovarian origin, apparently from the hyperplastic ovarian stroma accompanying the carcinoma cells. A case at the University of Maryland Hospital illustrating both these aspects was reported by Connor and associates. The patient had a large left ovary removed at another hospital at the age of 37. She developed marked virilization during pregnancy the following year. The right ovary was found to be enlarged and after delivery of a female infant, it was removed. Signet ring cells were found in the right ovary and review of sections of the left ovary, removed two years earlier, also revealed the presence of such cells. Subsequent radiologic examination revealed a gastric ulcer and the stomach was resected. The gastric lesion was a small ulcerated, infiltrative carcinoma containing signet ring cells similar to those found in the ovaries. There was no evidence of metastases in other organs. Virilization disappeared and the patient was well when last seen three years after gastrectomy.

References

Comfort, M. W., Gray, H. K., Dockerty, M. B., Gage, R. P., Dornberger, G. R., Solis, J., Epperson, D. P., and McNaughton, R. A. Small gastric cancer. Arch. Intern. Med. 94:513–524, 1954.

Connor, T. B., Ganis, F. M., Levin, H. S., Migeon, C. J., and Martin, L. G. Gonadotropin-dependent Krukenberg tumor causing virilization during pregnancy. J. Clin. Endocr. 28:198–214, 1968.

Fernet, P., Azar, H. A., and Stout, A. P. Intramural (tubal) spread of linitis plastica along the alimentary tract. Gastroenterology 48.419–424, 1965.

Friesen, G., Dockerty, M. B., and ReMine, W. H. Superficial carcinoma of the stomach. Surgery 51:301–312, 1962.

Majima, S., Yamaguchi, I., Yoshida, K., Karube, K., and Teshima, T. Duodenal extension of carcinoma of the stomach. Tohoku J. Exp. Med. 83:159–167, 1964.

Ringertz, N. The pathology of gastric carcinoma. Nat. Cancer Inst. Monogr 25:275–285, 1967.

Sunderland, D. A. The Lymphatic Spread of Gastric Cancer, p. 408. In: McNeer, G., and Pack, G. T. Neoplasms of the Stomach. Philadelphia: J. B. Lippincott, 1967.

Takayama, T., and Toda, H. Appearance of cancer cells in the blood stream of gastric cancer patients. Its significance in prognosis. J. Int. Coll. Surg. 44:391–404, 1965.

CLINICAL ASPECTS OF CARCINOMA. **Age and Sex.** Gastric carcinoma occurs twice as frequently in men as in women, and primarily in older individuals (fig. 129). In the series studied by Harvey and associates, 73 percent of the patients were 50 years of age or older. Of 296 cases in the files of the Pathology Department at the University of Maryland Hospital, 57 percent of the patients were 60 years of age or older, and 37 percent were between 40 and 59 years of age. In each group, the male to female ratio was about 2.5 to 1. Of the 18 patients (6 percent) younger than 39 years, there were nine men and nine women; two patients were 19 years old, the youngest age in this group. A higher incidence in females among younger patients has also been noted by other investigators (Eklund; McNeer). Alaghemand reported a carcinoma located at the pylorus, with metastases to lymph nodes and liver, in an 11½-year-old Negro boy, but the youngest patient was probably the male infant, reported by Cullingworth in 1877, who began to vomit at the age of 10 days and died 29 days later. A "cylinder-celled epithelioma" involving the pylorus was found at autopsy.

Women and young victims of this disease have a relatively high incidence of infiltrative scirrhous carcinoma. Ninety-three of 352 cases of gastric carcinoma analyzed by Eklund were the scirrhous type. In this group, there were 43 men and 48 women. In patients under 50 years of age, scirrhous carcinoma was present in 47 percent of cases, while it was found in only 23 percent of the older patients.

Clinical Manifestations and Diagnosis. The most frequent complaints are epigastric pain and discomfort. Some patients have symptoms of benign ulcer. Weight loss and anemia are common. Occult blood in the stools is present in the majority of cases, but massive bleeding is rare. Achlorhydria or hypochlorhydria are found in about half the cases (Veidenheimer and Logan), but are infrequent in young patients and those with superficial carcinoma (Friesen et al.). Unusual manifestations of gastric carcinoma include: free perforation (Wilson); hypoglycemia (Silverstein); microangiopathic hemolytic anemia (Lynch et al.); fatal fibrinolysis (Welborn et al.); renal amyloidosis (Acland et al.); nephrotic syndrome (Cantrell); esophageal achalasia (Kolodny et al.); flaky calcification in mucinous carcinoma visible in a roentgenogram (Hermann and Rozin); and monoclonal gammopathy with presence of M-components of immunoglobulins in serum (Williams et al.).

Diagnoses have been based primarily on examination of symptomatic patients. Thus, asymptomatic cases may be completely missed. Five of 80 autopsied cases seen at the University of Maryland Hospital were asymptomatic; in four the tumors were small, but one measured 9 by 6 by 2.5 cm. None of these tumors had metastasized. Roentgenographic studies have resulted in the correct diagnosis in 87 percent and suspicious findings in an additional 6.2 percent of patients (Veidenheimer and Logan). For discrete ulcers and superficial carcinomas, such studies have been rather disappointing (Palumbo and Sharpe; Vilardell). Because of the difficulty in ascertaining the benign or malignant nature of ulcerative lesions in the stomach, any such lesion should be evaluated carefully, particularly those ulcers resisting medical therapy. In ulcerated and superficial carcinomas, correct diagnosis may be achieved by gastroscopy, particularly with the fibergastroscope equipped for biopsy (Cohen et al.), the gastrocamera (Masuda), and cytologic examination (Vilardell). MacDonald and associates reported cytodiagnosis accurate in 90 percent of cases; it has also been used for screening high risk patients such as those with pernicious anemia and achlorhydria. When combined, these different supplemental methods yield the best results (Oyen; Blendis et al.). Tetracycline and acridine derivative fluorescence tests (Vilardell; Witte), and detection of radioactive tumors following administration of P^{32} (Otto et al.) have also been useful adjuvants in diagnosis.

The search for a better rate of cure for gastric carcinoma has always emphasized early diagnosis. Only recently, however, has significant improvement been made in early diagnosis, particularly in Japan where the incidence of superficial carcinoma, confined to the mucosa and submucosa, increased from 3.8 percent in 1955 to 34.5 percent in 1966 (Prolla et al.). This improvement has been attributed to mass screening by radiologic examinations and better diagnostic methods. Among the latter, the fibergastroscope permitting biopsy under direct vision is particularly useful in diagnosing such difficult lesions as ulcers and superficial carcinomas. A correct diagnosis has been achieved in up to 90 percent of cases by this method in the hands of experts (Prolla et al.); however, as with biopsy specimens in general, the value is limited by the selection of the appropriate sites for sampling and the quality of the samples. Improved pathologic understanding of these early tumors has also made it possible to recognize them sooner. In the United States, mass radiologic screening is not practical at present, and

earlier diagnosis relies primarily on understanding and recognizing early carcinoma and improved diagnostic methods.

References

Acland, J. D., Hossein, H. M. T., and Jackson, E. Renal amyloidosis associated with gastric carcinoma. Brit. Med. J. 1:99–100, 1968.

Alaghemand, A. Gastric carcinoma in a child. Amer. J. Dis. Child. 103:833–834, 1962.

Blendis, L. M., Beilby, J. O. W., Wilson, J. P., Cole, M. J., and Hadley, G. D. Carcinoma of stomach. Evaluation of individual and combined diagnostic accuracy of radiology, cytology, and gastrophotography. Brit. Med. J. 1:656–659, 1967.

Cantrell, E. G. Nephrotic syndrome cured by removal of gastric carcinoma. Brit. Med. J. 2:739–740, 1969.

Cohen, N. N., Hughes, R. W., Jr., and Manfredo, H. E. Experience with 1000 fibergastroscopic examinations of the stomach. Amer. J. Dig. Dis. 11:943–950, 1966.

Cullingworth, C. T. Case of cancer of the stomach in an infant five weeks old. Brit. Med. J. 2:253, 1877.

Eklund, A. E. Studies on the relation between ABO blood groups and gastric carcinoma. I. Relation of blood groups to different types of tumour. Acta Chir. Scand. 129:211–218, 1965.

Friesen, G., Dockerty, M. B., and ReMine, W. H. Superficial carcinoma of the stomach. Surgery 51:301–312, 1962.

Harvey, H. D., Titherington, J. B., Stout, A. P., and St. John, F. B. Gastric carcinoma; experience from 1916 to 1949 and present concepts. Cancer 4:717–725, 1951.

Hermann, G., and Rozin, R. Calcification in gastro-intestinal carcinomata. Clin. Radiol. 15:139–141, 1964.

Kolodny, M., Schrader, Z. R., Rubin, W., Hochman, R., and Sleisenger, M. H. Esophageal achalasia probably due to gastric carcinoma. Ann. Intern. Med. 69:569–573, 1968.

Lynch, E. C., Bakken, C. L., Casey, T. H., and Alfrey, C. P. Microangiopathic hemolytic anemia in carcinoma of the stomach. Gastroenterology 52:88–93, 1967.

MacDonald, W. C., Brandborg, L. L., Taniguchi, L., Beh, J. E., and Rubin, C. E. Exfoliative cytological screening for gastric cancer. Cancer 17:163–169, 1964.

Masuda, M. On the diagnosis of the superficial carcinoma of stomach by gastrocamera. Acta Un. Int. Cancr. 20:827–828, 1964.

McNeer, G. Cancer of the stomach in the young. Amer. J. Roentgen. 45:537–550, 1941.

Otto, D. L., Horwitz, N., Kurtzman, R. S., and Lofstrom, J. E. Radioactive I^{131} and P^{32} as aids in the diagnosis of lesions of the stomach. Amer. J. Roentgen. 91:784–795, 1964.

Oyen, O. Gastroscopy. Its value in the diagnosis of ulcer or tumour of the stomach. Acta Chir. Scand. 131:454–460, 1966.

Palumbo, L. T., and Sharpe, W. S. Gastric ulcer. Is it benign or malignant? Arch. Surg. 85:705–710, 1962.

Prolla, J. C., Kobayashi, S., and Kirsner, J. B. Gastric cancer. Some recent improvements in diagnosis based upon the Japanese experience. Arch. Intern. Med. 124:238–246, 1969.

Silverstein, M. N. Tumor hypoglycemia. Cancer 23:142–144, 1969.

Veidenheimer, M. C., and Logan, C. J. Cancer of the stomach. Surg. Clin. N. Amer. 47:621–626, 1967.

Vilardell, F. Revaluation of cytologic methods in the diagnosis of malignant lesions of the stomach. Progress in Gastroenterology 1:129–156, 1968.

Welborn, J. K., Brennan, M. J., and Hathaway, J. C., Jr. Acute fatal fibrinolysis with gastric carcinoma. Amer. J. Surg. 108:344–348, 1964.

Williams, R. C., Jr., Bailly, R. C., and Howe, R. B. Studies of "Benign" Serum M-components. Amer. J. Med. Sci. 257:275–293, 1969.

Wilson, T. S. Free perforation in malignancies of the stomach. Canad. J. Surg. 9:357–364, 1966.

Witte, S. Intravital fluorescent staining with acridine derivatives in cytodiagnosis of the upper gastrointestinal tract. Acta Cytol. 12:15–17, 1968.

TREATMENT AND PROGNOSIS. Treatment for gastric carcinoma is surgical. Continued improvements in methods with increased operability and resectability have reduced hospital mortality rates. Present surgical management as reported from major clinics (Lumpkin et al.; Muto et al.; ReMine and Priestley; Veidenheimer and Logan; Wangensteen and Sosin) may be summarized as follows: Of 100 patients hospitalized, 90 or more had surgical treatment; 60 to 70 had

gastrectomy; 35 to 45 had resection for cure; 4 to 8 died in the hospital; and 15 survived five years or longer. Of the patients who had curative resection, 36 percent survived more than five years, and 18 percent 10 years or more (Veidenheimer and Logan). The preferred surgical procedure was subtotal gastrectomy for distally located tumors and total gastrectomy for proximally located tumors. Gilbertsen noted that increasingly extensive resection resulted in increased survival rates up to 1963; since then, further extension of surgical resection has resulted in increased operative mortality and decreased survival rates. Thus, the surgical approach appears to have reached its limit. Further improvement depends upon diagnosis of early carcinoma. The 5-year survival rates for superficial carcinoma vary from 66 percent (Bragg et al.) to 95 percent (Friesen et al.). Once the tumor has metastasized to the regional lymph nodes, the prognosis is poor. In the series of Hawley and associates, the 5-year survival rate was 40 percent for patients without and only 11 percent for those with lymph node involvement.

Radiotherapy and chemotherapy have been used as adjuvants to surgical treatment with only minor benefit (Kettunen and Larmi; Wilken and Thomson; Serlin et al.). When assessing the survival rates, instances of occasional long survival without treatment should be borne in mind. Loux and Zamcheck reported two patients in whom cancer cells were detected cytologically five and six years before the lesions became demonstrable. Moertel studied the fate of 307 patients with inoperable gastric cancer: 10 percent survived more than one year; 2 percent, five years and more; one percent, 10 years and more; and one patient lived for 12 years after metastases were found in the liver.

Of 4,586 patients treated surgically for gastric carcinoma at the Mayo Clinic, ReMine and associates found that 957 patients survived 10 years or more: 5 percent of these 957 patients had a tumor larger than 10 cm.; 27 percent had undifferentiated tumor; 27 percent had metastases in the lymph nodes; in 37 percent the tumor extended to the serosa of stomach; and in 11 patients the tumor involved the entire stomach. All these manifestations have been considered factors adversely affecting prognosis (Eker and Efskind). Paile, Inberg and associates, and Martin and Kay emphasized the infiltrative ability of the tumor as demonstrated histologically when assessing the prognosis—the more infiltrative the tumor, the worse the prognosis. Black and associates relied more on tissue reaction around the tumor and in the regional lymph nodes than on the actual features of the tumor. They noted that patients with longer survival periods showed lymphocytic reaction in the stroma of the primary tumor and sinus histiocytosis in the regional lymph nodes. This view has recently been reiterated by Inokuchi and associates. Paile and Hawley and associates also noted longer survival in patients showing heavy round cell infiltration in the stroma of tumor.

References

Black, M. M., Opler, S. R., and Speer, F. D. Microscopic structure of gastric carcinomas and their regional lymph nodes in relation to survival. Surg. Gynec. Obstet. 98: 725–734, 1954.

Bragg, D. G., Seaman, W. B., and Lattes, R. Roentgenologic and pathologic aspects of superficial spreading carcinoma of the stomach. Amer. J. Roentgen. 101: 437–446, 1967.

Eker, R., and Efskind, J. The pathology and prognosis of gastric carcinoma. Based on 1314 partially and totally resected cases. Acta Chir. Scand. Suppl. 264: 1–182, 1960.

Friesen, G., Dockerty, M. B., and ReMine, W. H. Superficial carcinoma of the stomach. Surgery 51: 301–312, 1962.

Gilbertsen, V. A. Results of treatment of stomach cancer. An appraisal of efforts for more extensive surgery and a report of 1,983 cases. Cancer 23: 1305–1308, 1969.

Hawley, P. R., Westerholm, P., and Morson, B. C. Pathology and prognosis of carcinoma of the stomach. Brit. J. Surg. 57:877–883, 1970.

Inberg, M., Lauren, P., and Viikari, S. Factors influencing survival after radical operation for gastric cancer. J. Int. Coll. Surg. 44:682–686, 1965.

Inokuchi, K., Inutsuka, S., Furusawa, M., Soejima, K., and Ikeda, T. Stromal reaction around tumor and metastasis and prognosis after curative gastrectomy for carcinoma of the stomach. Cancer 20:1924–1929, 1967.

Kettunen, K., and Larmi, T. Convergent beam therapy following gastrectomy for gastric cancer. Acta Chir. Scand. 127:138–140, 1964.

Loux, H. A., and Zamcheck, N. Cytological evidence for the long "quiescent" stage of gastric cancer in 2 patients with pernicious anemia. Gastroenterology 57:173–184, 1969.

Lumpkin, W. M., Crow, R. L., Jr., Hernandez, C. M., and Cohn, I., Jr. Carcinoma of the stomach: Review of 1,035 cases. Ann. Surg. 159:919–932, 1964.

Martin, C., and Kay, S. The prognosis of gastric carcinoma as related to its morphologic characteristics. Surg. Gynec. Obstet. 119:319–322, 1964.

Moertel, C. G. The natural history of advanced gastric cancer. Surg. Gynec. Obstet. 126:1071–1074, 1968.

Muto, M., Majima, S., Yoshida, K., Karube, K., Teshima, T., and Yamaguchi, I. Results of surgery in 1988 surgical cases of stomach cancer. Tohoku J. Exp. Med. 81:267–278, 1963.

Paile, A. Morphology and prognosis of carcinoma of the stomach. Ann. Chir. Gynaec. Fenn. 60.Suppl. 175, 1971.

ReMine, W. H., and Priestley, J. T. Trends in prognosis and surgical treatment of cancer of the stomach. Ann. Surg. 163:736–745, 1966.

———, Gomes, M. M. R., and Dockerty, M. B. Long-term survival (10 to 56 years) after surgery for carcinoma of the stomach. Amer. J. Surg. 117:177–184, 1969.

Serlin, O., Wolkoff, J. S., Amadeo, J. M., and Keehn, R. J. Use of 5-fluorodeoxyuridine (FUDR) as an adjuvant to the surgical management of carcinoma of the stomach. Cancer 24:223–228, 1969.

Veidenheimer, M. C., and Logan, C. J. Cancer of the stomach. Surg. Clin. N. Amer. 47:621–626, 1967.

Wangensteen, O. H., and Sosin, H. How can the outlook in alimentary tract cancer be improved? Amer. J. Surg. 115:7–16, 1968.

Wilken, B. J., and Thomson, J. W. W. Chemotherapy in cancer of the stomach. Brit. J. Surg. 53:904–906, 1966.

ADENOACANTHOMA AND SQUAMOUS CELL CARCINOMA

SYNONYMS AND RELATED TERMS: **Adenocarcinoma with squamous metaplasia.**

The normal stomach has no squamous epithelium except at the cardiac end where small patches of isolated squamous epithelium may be present, probably due to congenital displacement of esophageal tissue. Squamous cell tumor in the cardiac portion may have arisen from this epithelium, or more likely may represent extension of an esophageal lesion. In a few cases, squamous cells are present in a carcinoma of the distal stomach, either alone or mixed with glandular elements (fig. 193). Squamous cell carcinomas and adenoacanthomas have been found in 0.04 percent (Straus et al.) to 3.4 percent (Urban et al.) of reported series of cases of gastric carcinoma. They cannot be distinguished from usual adenocarcinomas, either grossly or clinically, except for their occurrence in slightly younger aged patients (Boswell and Helwig). About two-thirds of these tumors are located in the distal half of the stomach. They form either ulcerated or fungating masses and rarely they form a diffusely infiltrative lesion (Strassmann). Relative amounts of squamous and glandular cells in the same tumor are variable. As stated by Straus and associates, apparently pure squamous cell carcinomas may reveal glandular elements if a large number of sections are studied microscopically. Only rarely have there been foci of benign squamous epithelium found in the adjacent mucosa (French et al.; Strassmann). Theories on the origin of squamous cells have implicated squamous metaplasia in an adenocarcinoma (Donald), metaplastic or heterotopic preexisting squamous epithelium (Strassmann), heterotopic pancreas (Szögi), and primitive cells capable of differentiating into either squamous or glandular cells (French et al.; Wood). Straus and associates suggested that all these possibilities may be valid.

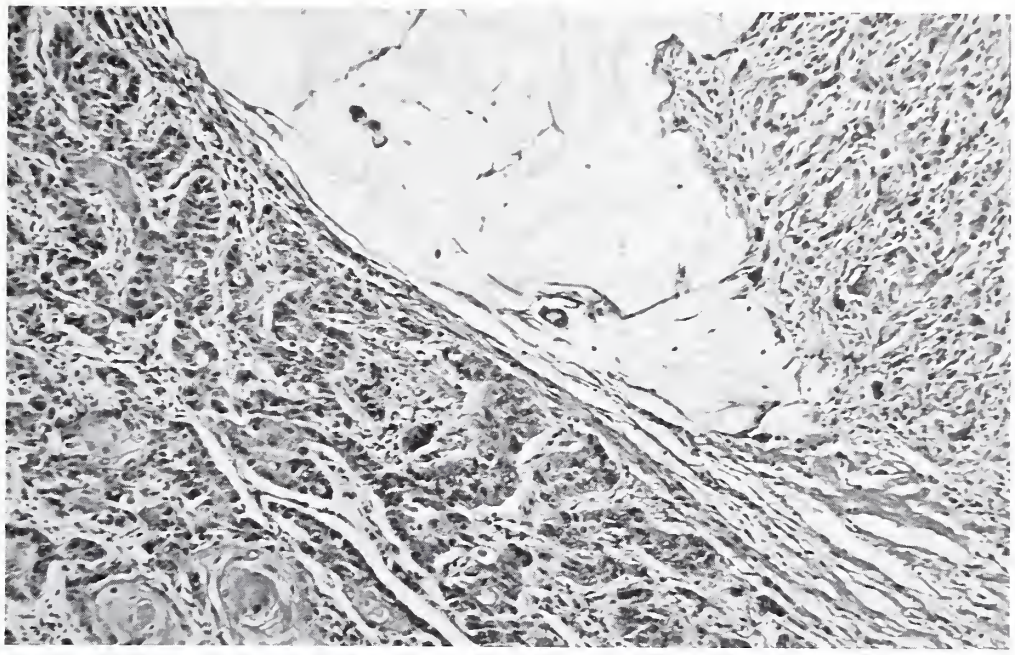

Fig 193

ADENOACANTHOMA

This photomicrograph of an ulcerated infiltrative carcinoma involving the posterior wall of the midportion of the stomach shows squamous cells in the left lower field, a pool of mucin in the upper portion, and poorly differentiated tumor cells at the right. In areas not visible in this field, signet ring cells were present. × 168.

CHORIONEPITHELIOMA

SYNONYMS AND RELATED TERMS. Choriocarcinoma; chorioepithelioma

Regan and Cremin reported a case of a 75-year-old man who had gynecomastia and a large fungating tumor in the proximal portion of the stomach with metastasis to the liver. Microscopic features of the tumor were compatible with chorionepithelioma in some areas and adenocarcinoma in others. They found 16 additional cases in the literature. The 17 patients ranged in age from 28 to 77 years; 11 were men and six were women. These gastric tumors were located in the pylorus and antrum in 10 patients; four patients showed chorionic gonadotropin activity and all had metastases. The tumors were evidently primary tumors of the stomach, and there was no genital or gonadal involvement in any of the patients. The suggested origin of the tumor has included displaced gonadal anlage, gastric teratoma, and retrograde differentiation of tumor cells to the embryonal stage with ability to form trophoblastic cells.

References

Boswell, J. T., and Helwig, E. B. Squamous cell carcinoma and adenoacanthoma of the stomach. A clinicopathologic study. Cancer 18: 181–192, 1965.

Donald, K. J. Adenocarcinoma of the pyloric antrum with extensive squamous differentiation. J. Clin. Path. 20: 136–138, 1967.

French, W. E., Affolter, H., and Hurteau, W. W. Squamous-cell carcinoma of the pylorus with diffuse metaplastic gastritis. Report of a case. Arch. Surg. 74: 322–326, 1957.

Regan, J. F., and Cremin, J. H. Chorionepithelioma of the stomach. Amer. J. Surg. 100: 224–233, 1960.

Strassmann, G. Adenoacanthoma of the stomach. Arch. Path. 41: 213–219, 1946.

Straus, R., Heschel, S., and Fortmann, D. J. Primary adenosquamous carcinoma of the stomach. A case report and review. Cancer 24: 985–995, 1969.

Szögi, S. Muco-epidermoid carcinoma of the stomach. Acta Path. Microbiol. Scand. 46: 37–42, 1959.

Urban, A., Oszacki, J., and Szczygiel, K. Squamous cell metaplasia in gastric carcinoma. Pol. Med. J. 6: 879–894, 1967.

Wood, D. A. Adenoacanthoma of the pyloric end of the stomach. A consideration of its histogenesis and a report of two cases. Arch. Path. 36: 177–191, 1943.

MULTIPLE AND RECURRENT CARCINOMAS

Malignant change in gastric mucosa is often widespread as seen in superficial carcinoma. The usual result is only a single gross carcinoma, however. Two or more distinctly separate carcinomas in the same stomach are rare. Reported incidences varied from 0 to 3.4 percent (Moertel et al.). In 1943, Brindley and associates reported 23 (2 percent) in a total of 1,184 cases of carcinoma at the Mayo Clinic. In 1957, Moertel and associates reported 40 (2.2 percent) among 1,835 cases seen at the same clinic in the following 10-year period. In 38 of these 40 patients, the tumors occurred simultaneously; in one of the remaining two patients, a second tumor occurred 11 years after resection of the first tumor, and in the other case, two separate tumors were found in the gastric remnant 14 years after initial resection. One additional patient had two leiomyosarcomas and one patient had one carcinoma and one leiomyosarcoma. Of 1,685 cases of malignant gastric tumor seen at the Memorial Hospital in New York City, two patients had coexisting carcinoma and leiomyosarcoma, one had lymphoma and carcinoma, and 20 had multiple carcinomas (McNeer et al.).

Recurrence of carcinoma in the gastric remnant following gastrectomy for carcinoma is common (fig. 194); Morgenstern reported 19 to

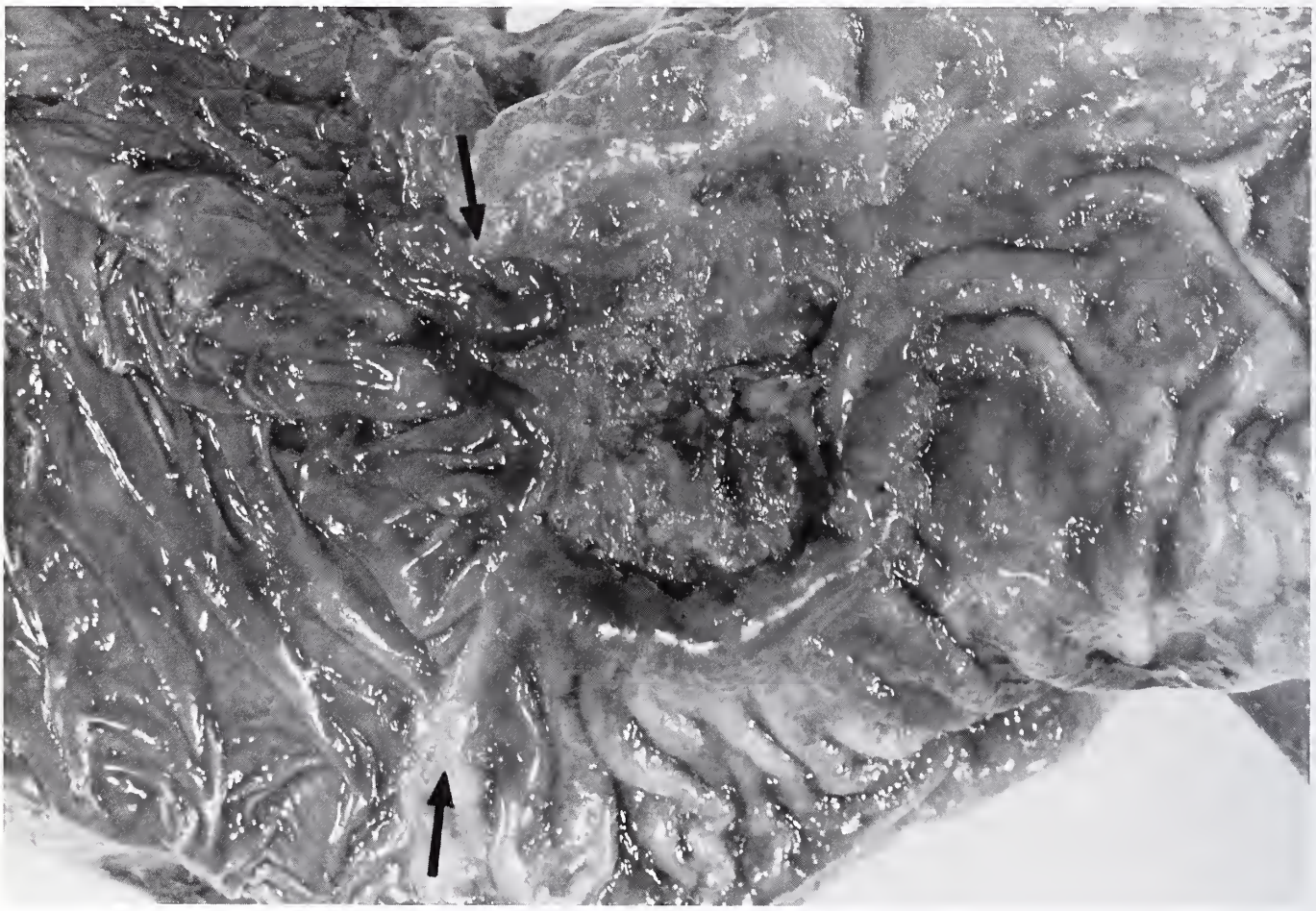

Fig 194

RECURRENT CARCINOMA

A 54-year-old man had a subtotal gastrectomy for carcinoma of the distal part of his stomach. Tumor cells were present at the proximal resection margin. This ulcerated carcinoma recurred seven years later and involved the gastrojejunostomy stoma (arrows). The tumor was composed mostly of gland-forming cells, but signet ring cells were also present. There were no metastases to lymph nodes.

50 percent recurrence, and Harvey and associates reported one in every four patients. Fridman noted carcinoma in the gastric stump at autopsy in 74 of 115 patients who had had gastrectomy. Of 194 cases analyzed by the same author, previous gastrectomy was performed for carcinoma in 149 cases, peptic ulcer in 27, and polyp in 18 cases. Of the carcinoma group, 89 patients (60 percent) had had a gastrectomy performed within three years, probably representing recurrence, and 31 patients had had a gastrectomy performed five or more years previously. Of 20 reported cases reviewed by Irons, the interval between the first gastrectomy and diagnosis of the second tumor varied from 3 to 39 years; 3 of the 20 patients had reticulum cell sarcoma at initial surgery and 17 had carcinoma. Inokuchi and associates reported recurrence of carcinoma in 2 of 25 patients who survived five years after gastrectomy for an early stage of carcinoma. In both patients the recurrence was diagnosed seven years after surgery. In another case, cancer cells continued to be found in the stomach, but the patient was alive three years and three months after surgery. These cases illustrate the long dormancy possible in gastric carcinoma and the need for careful follow-up examination, including periodic roentgenologic and cytologic studies in those patients who have had gastrectomy. Concomitant malignant tumor may also occur in different organs, but there is no apparent increase of risk for patients with gastric carcinoma (Schottenfeld et al.).

References

Brindley, G. V., Jr., Dockerty, M. B., and Gray, H. K. Multiple carcinomas of the stomach. Report of a case. Mayo Clin. Proc. 18:193–199, 1943.

Fridman, E. G. Cancer of a resected stomach: analysis of 194 cases. Acta Un. Int. Cancr. 19:1257–1260, 1963.

Harvey, H. D., Titherington, J. B., Stout, A. P., and St. John, F. B. Gastric carcinoma; experience from 1916 to 1949 and present concepts. Cancer 4:717–725, 1951.

Inokuchi, K., Inutsuka, S., Furusawa, M., Soejima, K., and Ikeda, T. Development of superficial carcinoma of the stomach: Report of late recurrence. Ann. Surg. 164:145–151, 1966.

Irons, H. S., Jr. Carcinoma twice in the same stomach. Gastroenterology 46:44–49, 1964.

McNeer, G., Pack, G. T., and Ashley, M. P. Multiple Gastric Tumors, p. 416. In McNeer, G., and Pack, G. T. Neoplasms of the Stomach. Philadelphia: J. B. Lippincott, 1967.

Moertel, C. G., Bargen, J. A., and Soule, E. H. Multiple gastric cancers. Review of the literature and study of 42 cases. Gastroenterology 32:1095–1103, 1957.

Morgenstern, L. The late development of gastric cancer after gastrectomy for malignant disease. Surgery 47:557–567, 1960.

Schottenfeld, D., Berg, J. W., and Vitsky, B. Incidence of multiple primary cancers. II. Index cancers arising in the stomach and lower digestive system. J. Nat. Cancer Inst. 43:77–86, 1969.

CARCINOID

SYNONYMS AND RELATED TERMS: **Carcinoid tumor; argentaffinoma.**

In normal gastric mucosa, Kultchitsky cells are few and scattered. They are more numerous in areas of intestinal metaplasia. Metaplastic glands are usually present in the area infiltrated by carcinoid, but it is not known whether gastric carcinoid originates in these metaplastic glands. Nevertheless, carcinoid rarely occurs in the stomach; it constitutes only 0.02 percent of gastric tumors (Table VI) and only 3.3 percent of carcinoids of the gastrointestinal tract (Sanders and Axtell). Gastric carcinoid may develop over a wide range of age, but occurs most frequently in the sixth decade. Lützow-Holm reported a case of ulcerated carcinoid with bleeding in a 15-year-old girl. Carcinoid of the stomach is usually a single, small, circumscribed nodule covered by intact mucosa. Pestana and associates found multiple carcinoids in only six of 90 cases. Another example is shown in figure 195.

Histologic features of gastric carcinoid resemble those of the intestines, but with a tendency to be trabecular in the stomach. The tumor cells are round or polygonal and form solid

Fig. 195

MULTIPLE CARCINOIDS

About 40 small mucosal nodules of carcinoid, measuring 0.2 to 0.6 cm. in diameter, were found at autopsy in the stomach of a 59-year-old woman who died of cerebral infarction and bronchopneumonia. Several are shown in this photograph. There were no metastases. (Courtesy of Beth Israel Hospital, Boston, Mass.)

masses and trabeculae (figs. 196, 197). Gastric carcinoids are known to give negative argentaffin and diazonium staining reactions. A recent study by Black confirmed this observation. A strong argyrophilic reaction is present, however. Thus, gastric carcinoid resembles gastric enterochromaffin cells in these reactions. Ultrastructural study done by the same author revealed that secretory granules in gastric carcinoids were argyrophilic, more uniform, smaller, and more variable in density than those in intestinal carcinoids. Occasional lumen-like spaces and mucus droplets may be seen in carcinoids (Black and Haffner). Soga and associates (1971) reported an ulcerated tumor showing mucin, argentaffin, and argyrophilic granules in tumor cells in an unusually well formed tubular pattern. These authors postulated that both mucus-secreting and argentaffin cells might have originated from the same primitive cells. When examined, all the carcinoids had invaded the submucosa, which obviates any valid reason for separating carcinoids into benign and malignant types. Metastases were present in 28 percent of reported cases (Sanders and Axtell), and carcinoid syndrome has been reported in eight cases (Crowder et al). McDonald reported the presence of peptic ulcer in 38 percent of cases with metastasizing carcinoid. The histologic features of carcinoid resemble those of islet cell tumors; both may cause peptic ulcers. The differentiation between them is at times difficult. The trabecular or acinar pattern, the mucus secretion, and the presence of argentaffin and argyrophilic granules favor the diagnosis of carcinoid.

Gastric carcinoid is a slowly growing tumor, and even those patients with metastases survive many years after surgical excision (Lattes and Grossi). Local excision is acceptable if the tumor is single, less than 1 cm. in diameter, and there is no evidence of metastasis. If the tumor is large or multiple, a subtotal gastrectomy is indicated. If metastases are present, all the tumor-involved tissue, including liver metastases, should be excised if possible (Crowder et al.).

Spontaneously occurring gastric tumors in the African rodent, *Praomys (Mastomys) natalensis,* had previously been considered carcinomas. Recently, these tumors have been found to have a strong argyrophilic reaction (figs. 198, 199; Snell and Stewart). Ultrastructural studies by Soga and associates (1969) revealed many secretory granules which had morphologic appearances resembling those of human gastric carcinoids. Many of the animals developed peptic ulcers.

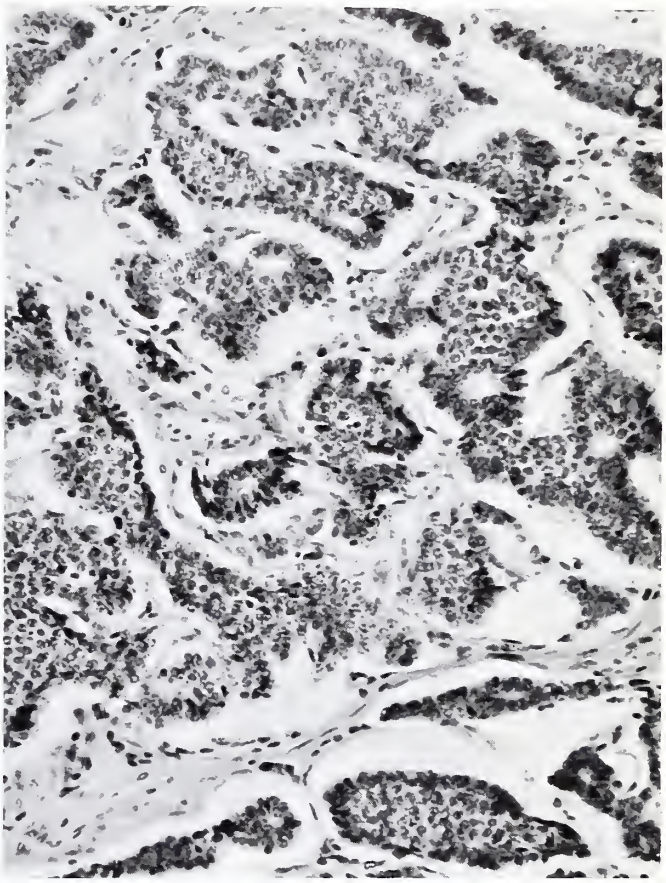

Fig. 196

Fig 196

CARCINOID

This photomicrograph of a 1 7 x 0 8 cm. carcinoid in the stomach of a 25-year-old woman shows sheets and strands of small uniform tumor cells with occasional small acinar formation. Tumor involved the mucosa, muscularis mucosae, and submucosa. The overlying gastric glands showed intestinal metaplasia ×190.

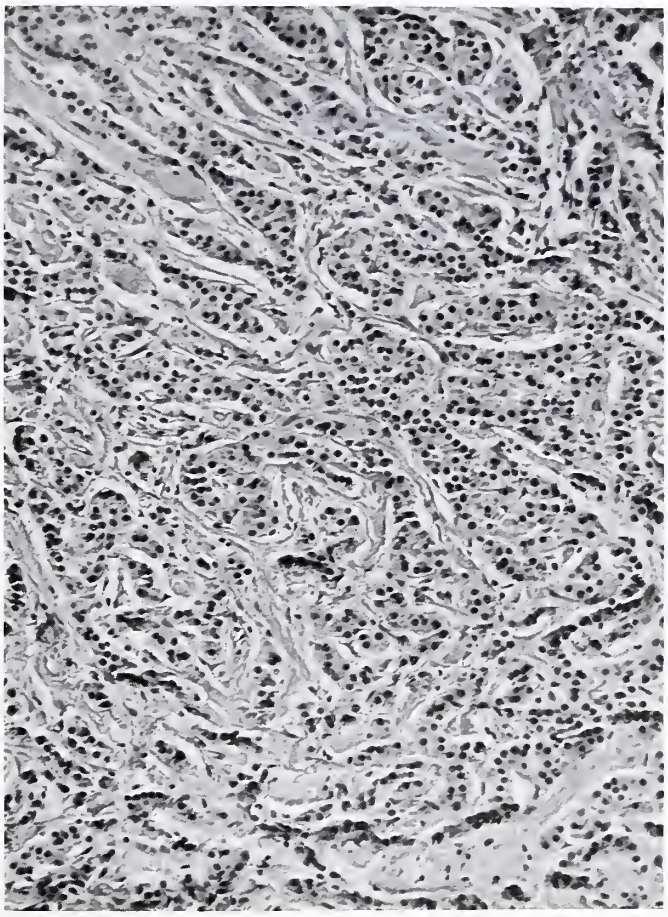

Fig 197

Fig. 197

CARCINOID

This photomicrograph of a gastric carcinoid, found incidentally at autopsy, reveals trabecular arrangement of uniform tumor cells infiltrating the muscularis externa. ×190.

GASTRIC CARCINOID OF MASTOMYS

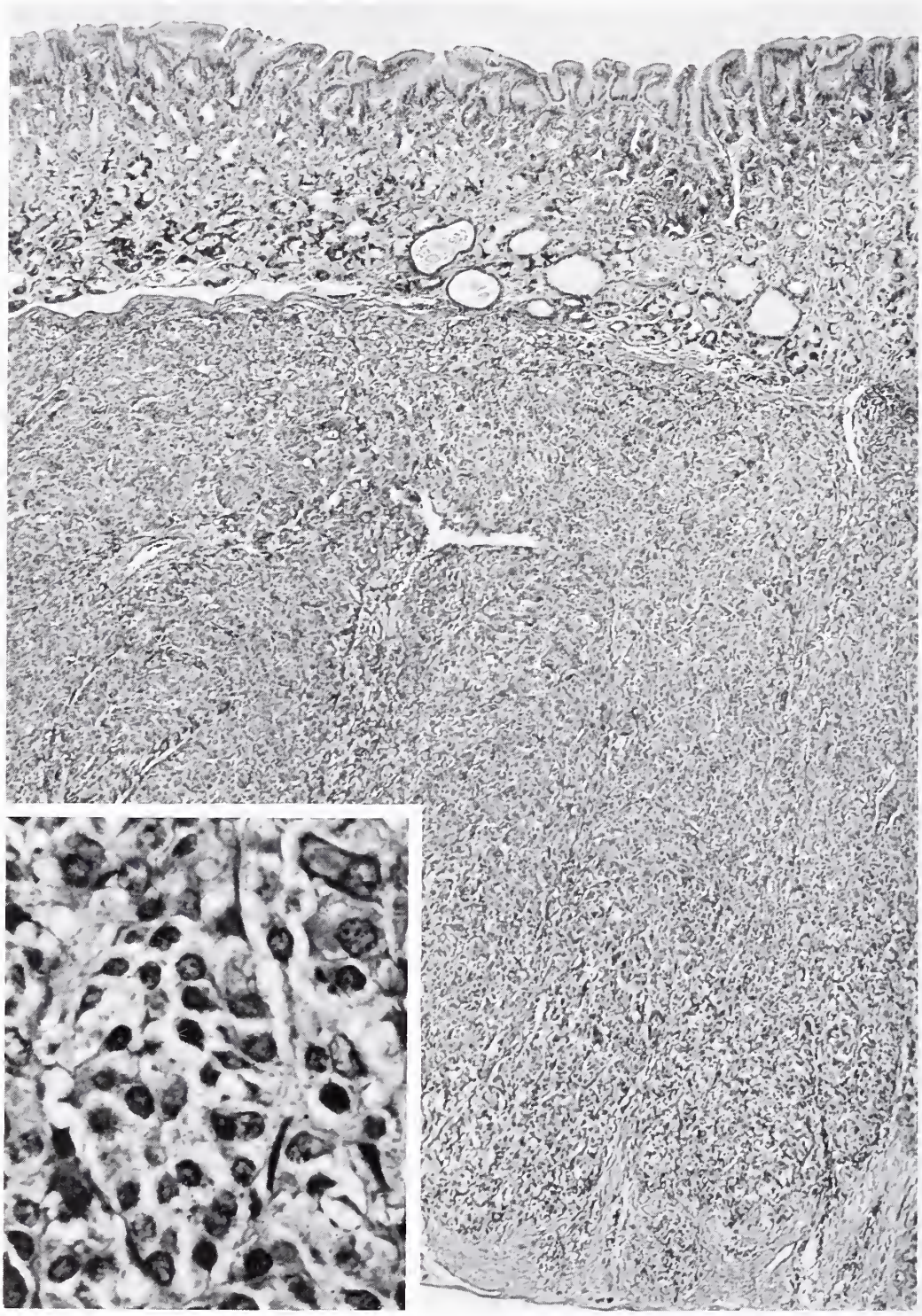

Fig. 198

This photomicrograph of a gastric carcinoid in a Mastomys shows massive infiltration of tumor cells, extending from the base of the mucosa to the outer region of the muscularis. A few dilated glands are seen in the otherwise normal mucosa. × 63. The higher magnification (insert) reveals detail of the clustered cells. × 610. (Courtesy of Dr. K. C. Snell, Bethesda, Md.)

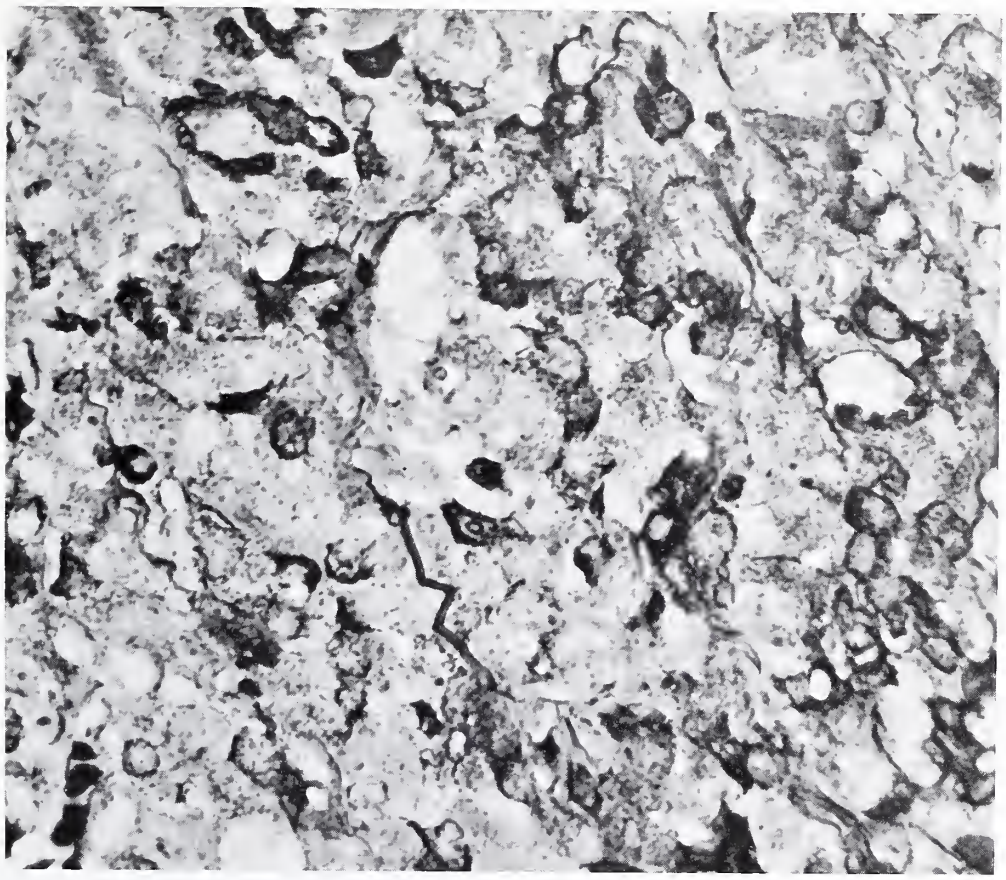

Fig. 199

GASTRIC CARCINOID OF MASTOMYS

This photomicrograph of a section of gastric carcinoid in a Mastomys treated with silver salt solution, according to the method of Sevier and Munger, shows many fine cytoplasmic black argyrophilic granules. × 610. (Courtesy of Dr. K. C. Snell, Bethesda, Md.)

References

Black, W. C., III. Enterochromaffin cell types and corresponding carcinoid tumors. Lab. Invest. 19 473–486, 1968.

———, and Haffner, H. E. Diffuse hyperplasia of gastric argyrophil cells and multiple carcinoid tumors. An historical and ultrastructural study. Cancer 21 1080–1099, 1968.

Crowder, B. L., II, Judd, E. S., and Dockerty, M. B. Gastrointestinal carcinoids and the carcinoid syndrome. Clinical characteristics and therapy. Surg. Clin. N. Amer. 47 915–927, 1967.

Lattes, R., and Grossi, C. Carcinoid tumors of the stomach. Cancer 9 698–711, 1956.

Lützow-Holm, G. Carcinoid tumors of the stomach. Two cases. Acta Chir. Scand. 104 193–200, 1952.

McDonald, R. A. A study of 356 carcinoids of the gastrointestinal tract; report of four new cases of the carcinoid syndrome. Amer. J. Med. 21 867–878, 1956.

Pestana, C., Beahrs, O. H., and Woolner, L. B. Multiple (seven) carcinoids of the stomach. Report of a case. Mayo Clin. Proc. 38 453–456, 1963.

Sanders, R. J., and Axtell, H. K. Carcinoids of the gastrointestinal tract. Surg. Gynec. Obstet. 119 369–380, 1964.

Sevier, A. C., and Munger, B. L. Technical note; a silver method for paraffin sections of neural tissue. J. Neuropath. Exp. Neurol. 24 130–135, 1965.

Snell, K. C., and Stewart, H. L. Malignant argyrophilic gastric carcinoids of Praomys (Mastomys) natalensis. Science 163 470, 1969.

Soga, J., Tazawa, K., and Ito, H. Ultrastructural demonstration of specific secretory granules of Mastomys gastric carcinoids. Acta Med. Biol. 17 119–124, 1969.

———, Tazawa, K., Aizawa, O., Wada, K., and Tuto, T. Argentaffin cell adenocarcinoma of the stomach: an atypical carcinoid? Cancer 28 999–1003, 1971.

TUMORS AND TUMOR-LIKE LESIONS OF MESODERMAL ORIGIN

TUMORS OF MUSCULAR TISSUE

LEIOMYOMA*

The gastric wall has an abundance of smooth muscle cells, and tumors of muscular tissue are common. Clinically significant tumors of this type occur with about the same frequency as polyps (Table VIII), but the small insignificant ones may be the most common tumors of the stomach. Their recorded incidence depends upon diligence of the search for such tumors. Meissner found leiomyomas in the stomach in 23 of 50 cases at autopsy. Palmer reviewed 610 cases in the literature and found an almost equal distribution between the sexes. The age of patients varied from 9 to 94 years; most patients were in the middle age group.

Grossly, most of the tumors project into the lumen; some protrude on the serosal aspect and occasional lesions have an hourglass shape. The covering mucosa is generally intact, but focal ulceration and hemorrhage may occur (fig. 200). The tumor is generally firm and rubbery and the cut surface is pale and fleshy (fig. 201). Gross appearance depends upon the cellularity of the tumor and the amount of collagenous tissue it contains.

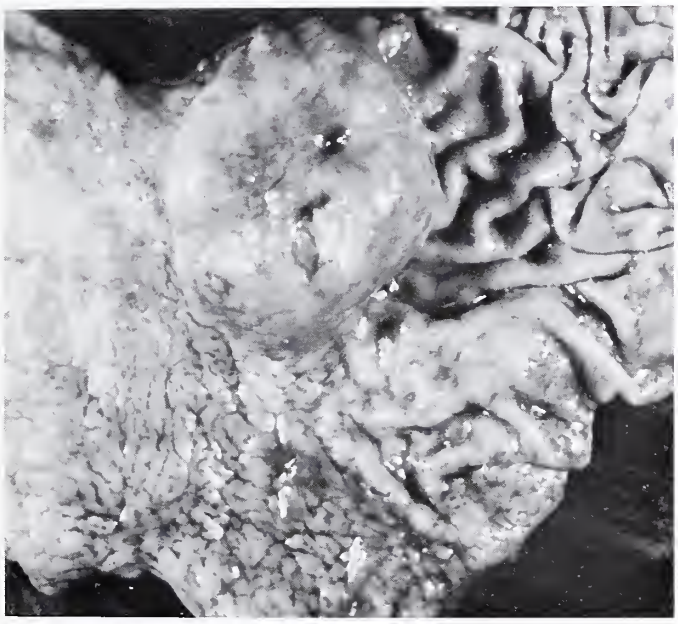

Fig. 200

LEIOMYOMA

(Figures 200 and 201 from same case)

This leiomyoma, from a 60-year-old woman who had gastric bleeding, was located at the junction of the fundic and pyloric mucosa; it measures 5 x 4 cm. Two small ulcers containing blood clots are visible on the dome of the mucosal covering.

Fig. 201

LEIOMYOMA

(Figures 200 and 201 from same case)

This photograph shows the pale, fleshy, cut surface of the tumor seen in figure 200.

Microscopically, the sharply circumscribed periphery shows no fibrous capsule and presses directly on the muscularis from which it has arisen (fig. 202). Leiomyoma is composed of easily recognizable bundles of spindly muscle cells interposed with varying amounts of collagen fibers (figs. 202, 203). A frequently encountered histologic feature is the palisade arrangement of nuclei with cytoplasmic processes radiating toward a less cellular and often collagenous focus (fig. 204). Occasional leiomyomas are cellular, and a rare mitosis may be seen. These tumors may have focal areas of hemorrhage and necrosis. Their benignity is indicated by well differentiated cells and the absence or rarity of mitoses. Welsh and Meyer studied the ultrastructure of gastric leiomyomas and found that in contrast to uterine leiomyomas, the features of normal smooth muscle cells, such as micropinocytotic activity and myofibril filaments, are inconspicuous and rare in gastric leiomyomas (fig. 205). In addition to these features, cilia were seen in some cells.

Fig. 202

LEIOMYOMA

This is a photomicrograph of one of two leiomyomas, which measured 1.5 and 3.5 cm. in diameter, in the pyloric antrum of a 65-year-old man who had gastric bleeding, anemia, and weight loss. It illustrates the round, sharply circumscribed periphery of the tumor without a fibrous capsule, but delineated by compressed smooth muscle. The pale areas in the tumor are collagenous tissue. Masson trichrome stain. × 11.

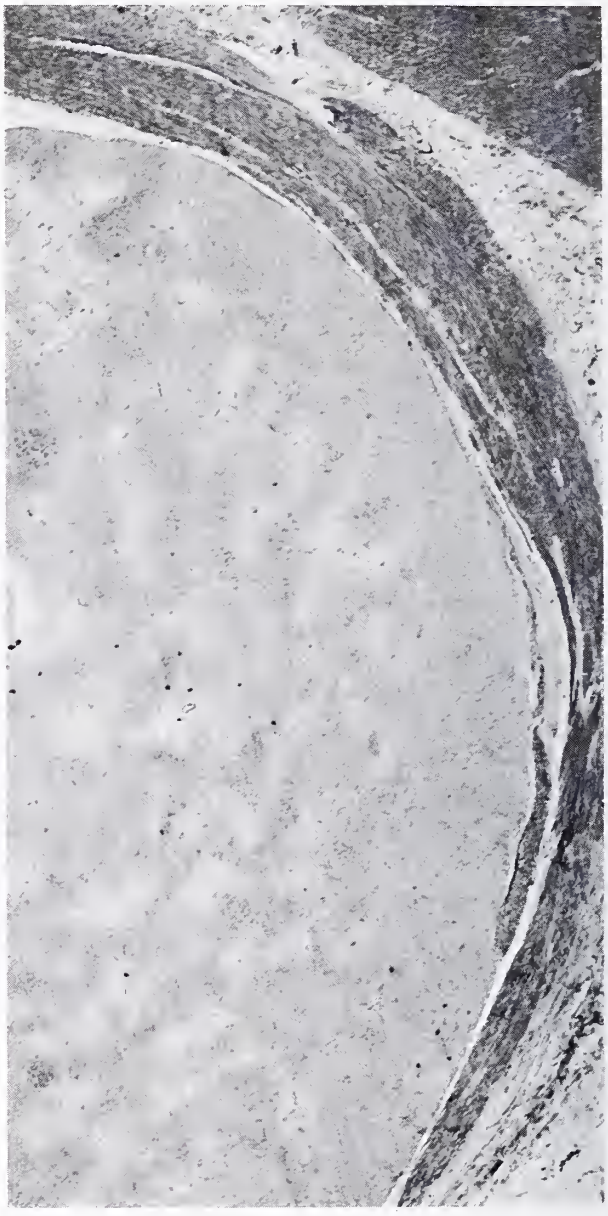

Fig. 202

LEIOMYOMA

(Figures 203 and 204 from same case)

Fig. 203

Tangled bundles of elongated smooth muscle cells are seen in this photomicrograph of a 12 x 8 x 8 cm. leiomyoma involving the lesser curvature of the stomach of a 47-year-old woman who had gastrointestinal bleeding and weight loss. Focal areas of hemorrhage and necrosis were present. × 119

Fig. 204

This photomicrograph of a different area of the tumor seen in figure 203 reveals prominent nuclear palisading of elongated tumor cells. × 115

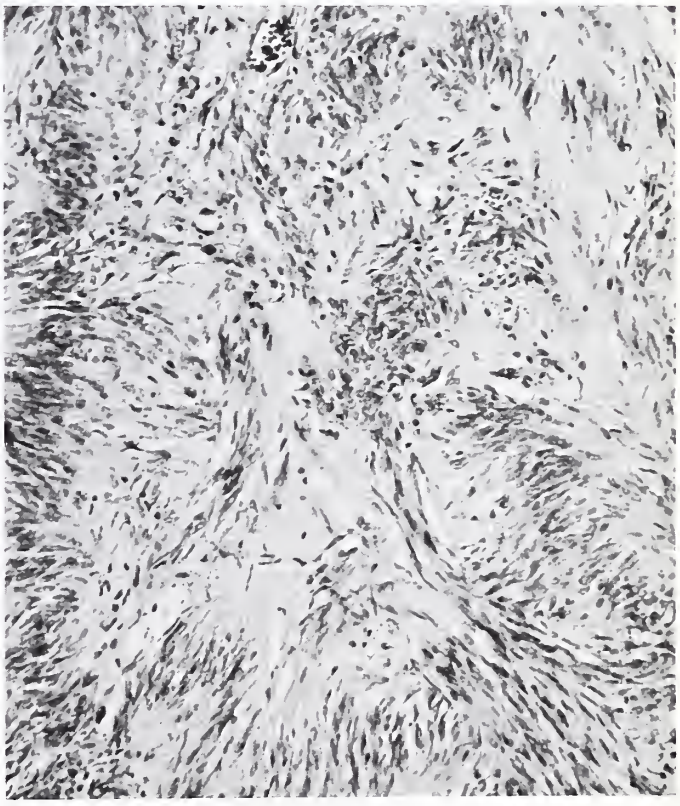

Fig. 204

LEIOMYOMA

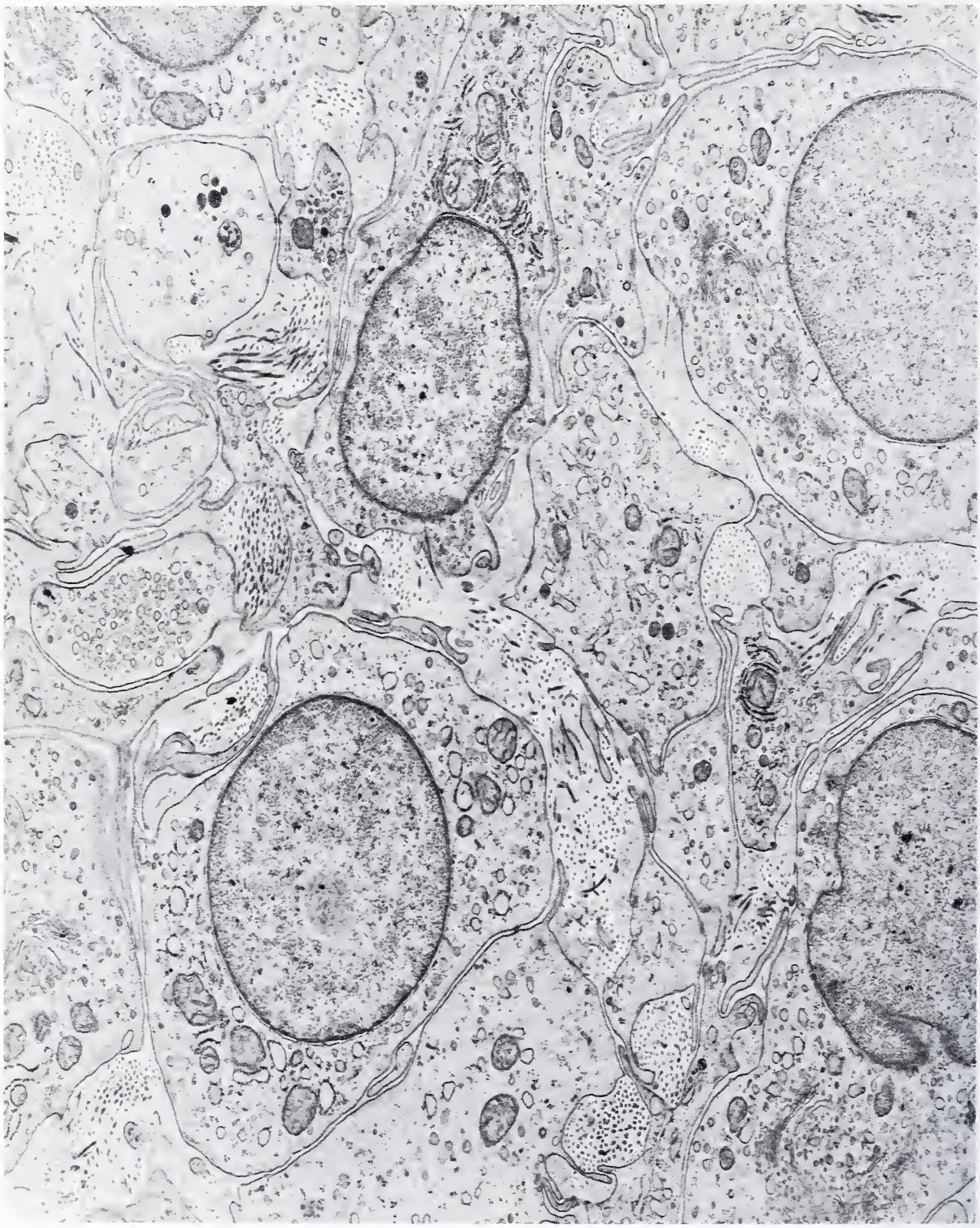

Fig. 205

An electron micrograph of the ultrastructure of a gastric leiomyoma reveals tumor cells with short cytoplasmic processes that are separated by collagen fibers. There are no micropinocytotic vacuoles or myofibrillar filaments, which are seen only infrequently in gastric leiomyomas. × 12,740 (Courtesy of Dr. R. A. Welsh, New Orleans, La; also fig. 6 from Welsh, R. A., and Meyer, A. T. Ultrastructure of gastric leiomyoma. Arch. Path. 87:71–81, 1969.)

LEIOMYOBLASTOMA

In 1960, Martin and associates reported six cases of gastric myoma that showed a bizarre histologic appearance with large, round or polygonal cells, often with a perinuclear clear zone rather than the familiar spindle cells. In 1962, Stout reviewed 69 such cases and proposed the term leiomyoblastoma for these tumors. Despite their bizarre cellular characteristics and mitoses, only two cases revealed metastases. Smithwick and associates reviewed 22 cases reported since 1962, seven of which had metastasized. From these reports, leiomyoblastoma appeared to be an intermediate tumor between regular leiomyoma and leiomyosarcoma in its biologic behavior. Its malignant potential was apparently related to the number of mitoses. With few exceptions, tumors with five or more mitoses per 50 high power fields had metastasized.

The gross appearance of leiomyoblastoma resembles that of leiomyoma. The tumor is round or oval and variable in size. It is generally circumscribed but not encapsulated, and soft or rubbery in consistency. Larger tumors are often ulcerated and may have areas of hemorrhage, necrosis, and cystic degeneration (fig. 206; pl. V-B). Bleeding from the tumor is a common and often serious complication. Tumors on the serosal surface can bleed massively into the peritoneal cavity (Wolf). Infiltration into the surrounding tissue may be seen grossly (fig. 207). The microscopic appearance is characterized by the presence of large pleomorphic cells. The nuclei are usually located at the center and often contain nucleoli. The cytoplasm is eosinophilic and contains clear areas (fig. 208). The perinuclear clear halo is considered characteristic. When collagen

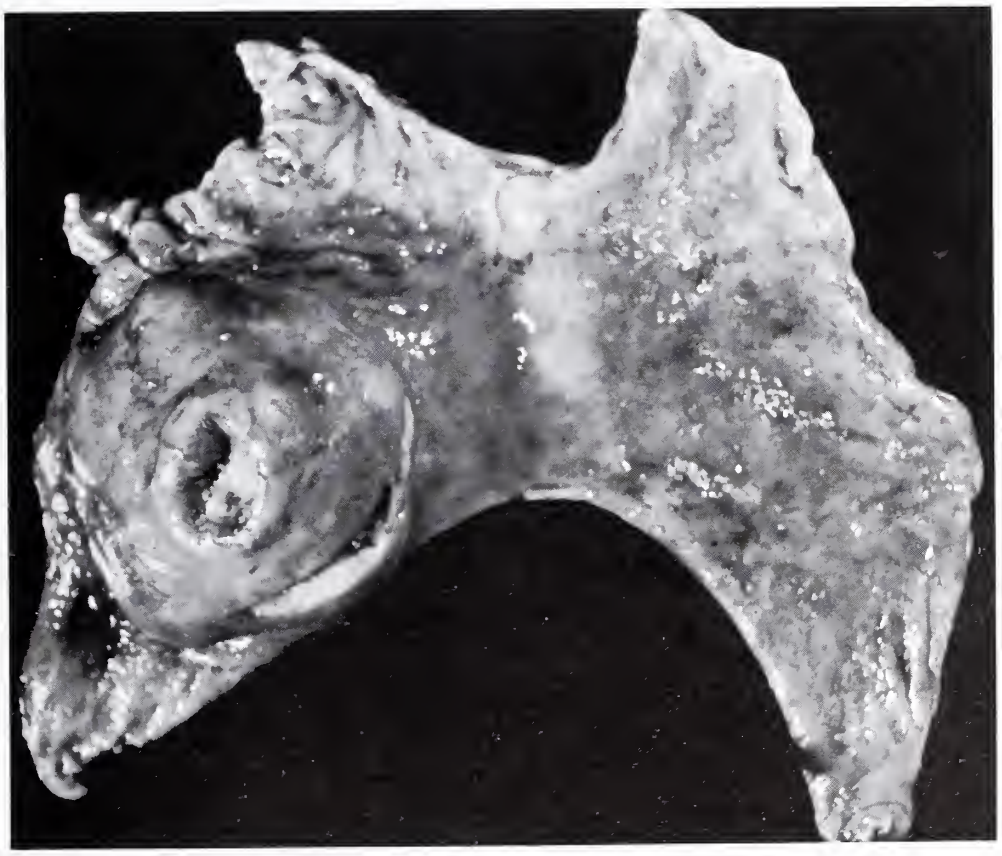

Fig. 206

LEIOMYOBLASTOMA

(Figure 206 and Plate V-B from same case)

This leiomyoblastoma, which measures 8 x 7 x 5.5 cm., was found in the posterior wall of the stomach in a 63-year-old woman. The mucosa shows a deep ulceration. (Courtesy of Beth Israel Hospital, Boston, Mass.)

LEIOMYOBLASTOMA

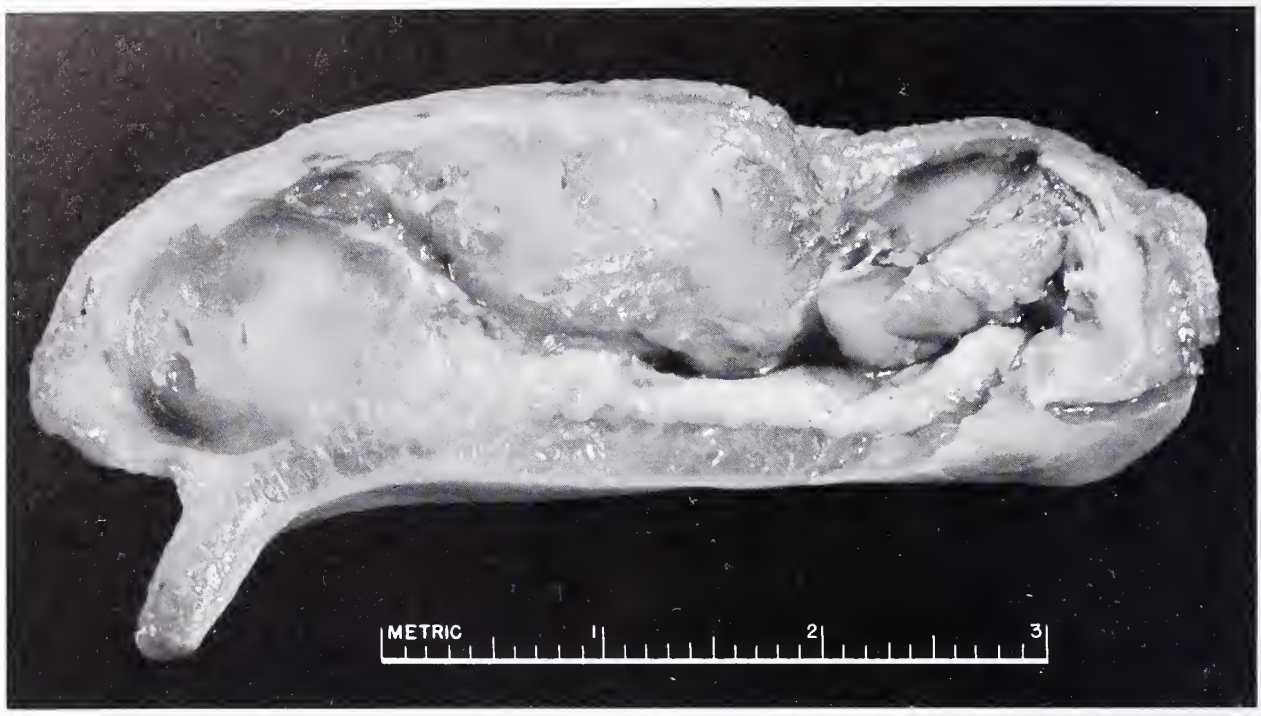

Fig 207

This photograph of the cut surface of a leiomyoblastoma in the posterior wall of the stomach reveals a nodular appearance and cystic areas. The tumor, which measured 6 cm. in greatest dimension, invaded the muscle layer. (Courtesy of Dr. I. W. Grossman, Brattleboro, Vt.)

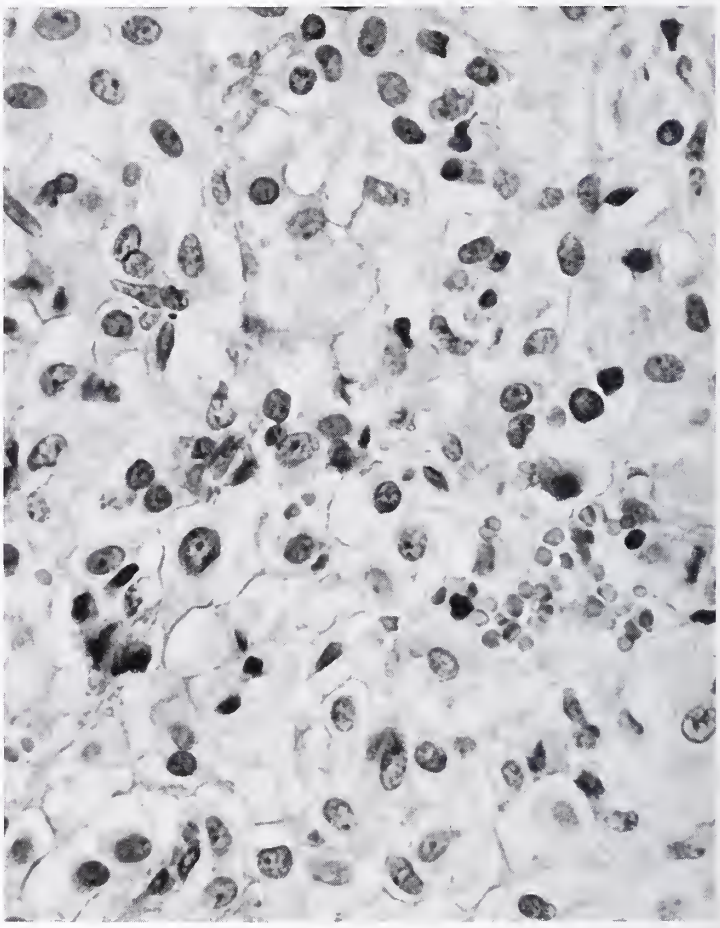

Fig. 208

This photomicrograph of a leiomyoblastoma shows round and polygonal tumor cells. The nuclei are variable in size and nucleoli are prominent. The cytoplasm is abundant and contains clear spaces. Cell membranes are prominent. × 500. (Courtesy of The Massachusetts General Hospital, Boston, Mass.)

Fig. 208

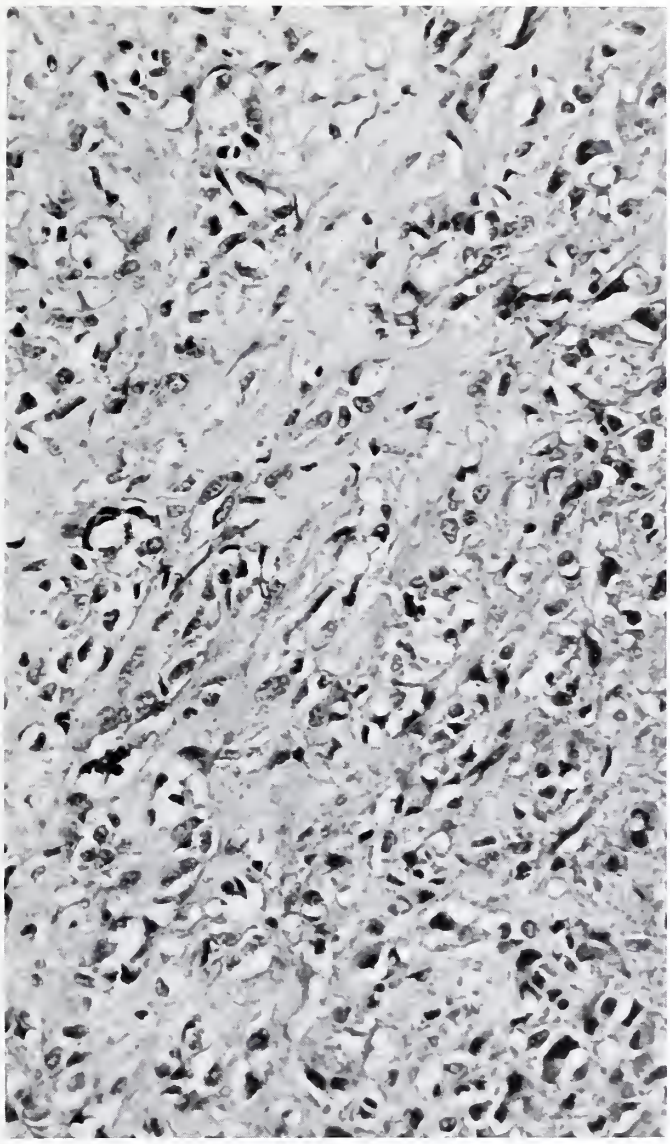

Fig 209

LEIOMYOBLASTOMA

(Figures 209 and 210 from same case)

This is a photomicrograph from a dumbbell-shaped tumor, measuring 5 cm. in greatest dimension, in a 54-year-old man. The tumor cells are pleomorphic with vacuolated cytoplasm in many cells. Collagen fibers intermingle with tumor cells. × 268.

Fig. 210

LEIOMYOBLASTOMA

(Figures 209 and 210 from same case)

This photomicrograph of the tumor seen in figure 209 reveals prominent reticulum completely or partially encircling individual or small groups of tumor cells. Reticulum stain. × 350.

fibers are present, tumor cells are scattered randomly among them rather than in bundles (fig. 209). Myofibrils are usually absent, but a reticulum pattern surrounding the individual or small groups of cells is usually present (fig. 210). Ultrastructural studies reveal varying amounts of intracytoplasmic microfilaments, occasional pinocytotic vesicles (fig. 211), and segments of basement membrane compatible with smooth muscle cell origin (Salazar and Totten). The perinuclear vacuoles are not seen and probably represent fixation artifact in paraffin sections. The tumor cells may be mistaken for carcinoma cells, particularly in frozen sections. The differentiation between leiomyoblastoma and carcinoma can usually be made grossly. The former is usually circumscribed and soft and mucosal ulceration is limited, whereas the carcinoma is ill-defined and extensively ulcerated. The lack of mucus secretion in tumor cells also favors leiomyoblastoma.

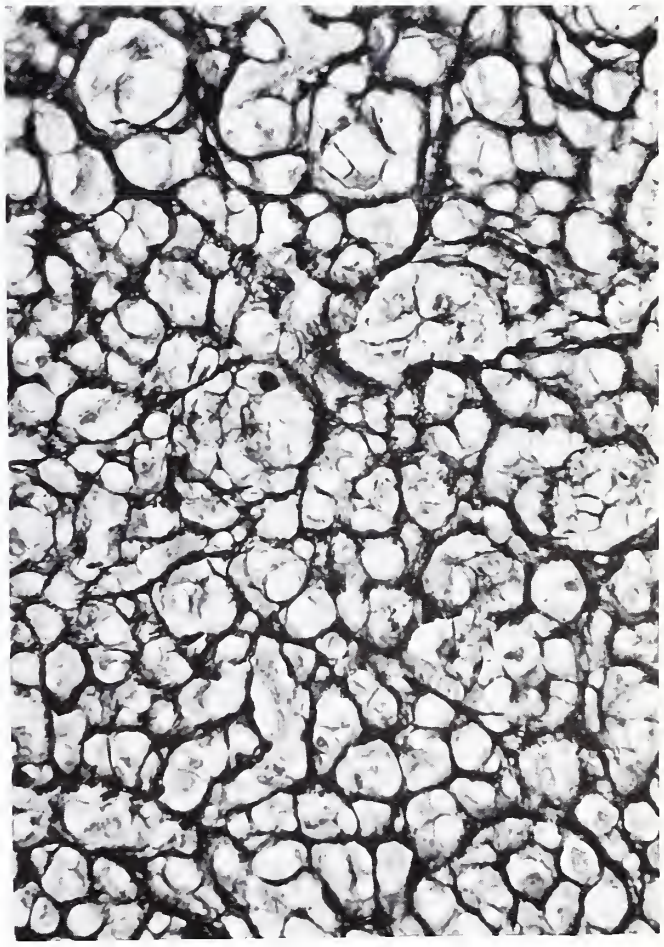

Fig 210

LEIOMYOBLASTOMA

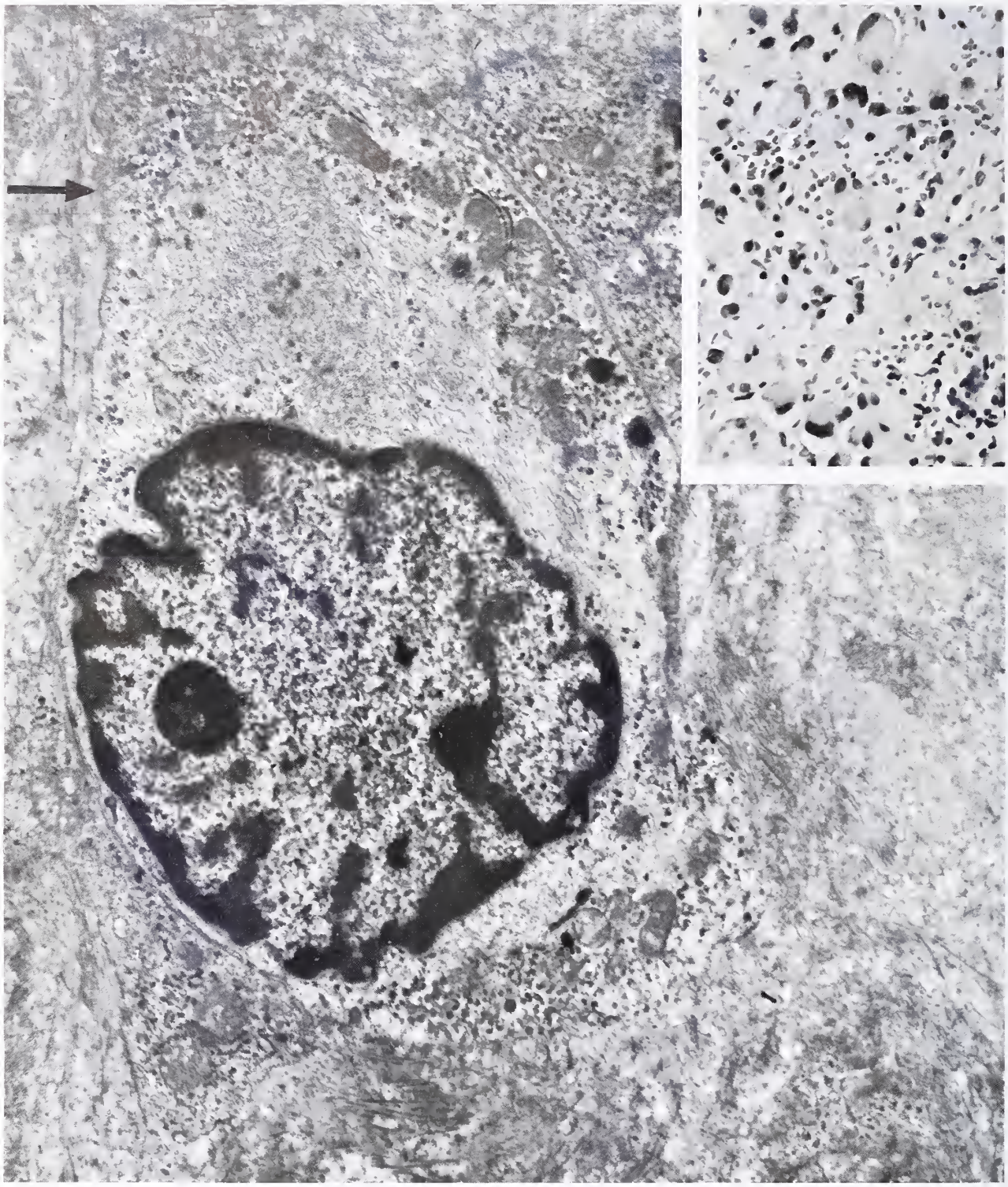

Fig. 211

This electron micrograph of a 1 cm. submucosal nodule found in the midportion of the stomach of a 70-year-old woman illustrates a tumor cell with a large nucleus and a moderate amount of cytoplasm. Many free ribosomes, microfilaments, and a few micropinocytotic vesicles (arrow) are present. × 9100. The insert shows pleomorphic tumor cells surrounded by fibrous tissue. × 268.

Clinically, there is a slight predominance in women. Most of the patients are in the older age group. Stout (1962) mentioned a case in a 14-year-old girl, and at Beth Israel Hospital in Boston, an ulcerated tumor, measuring 3 cm. in diameter, was found in a 7-month-old girl who had tarry stools. The tumor was very cellular and had many vascular spaces (figs. 212, 213). Diagnosis of bizarre leiomyoma was made by Dr. Arthur Purdy Stout. Smithwick and associates reported about half of their patients with leiomyoblastoma had gastric bleeding and in 40 percent of cases an abdominal mass was palpable. Treatment is surgical excision. Metastases, when present, involve the regional lymph nodes, peritoneum, and liver.

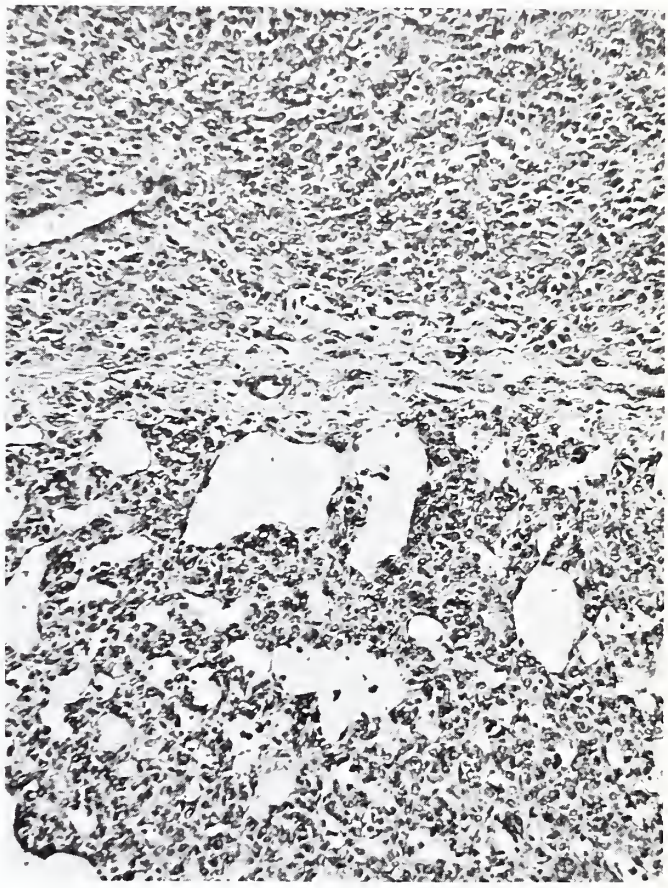

Fig. 212

Fig. 212

VASCULAR LEIOMYOBLASTOMA

(Figures 212 and 213 from same case)

This is a photomicrograph of an ulcerated submucosal mass, measuring 3 cm. in greatest dimension, which was found in the stomach of a 7-month-old girl who had tarry stools. The tumor is cellular and solid in some areas and contains many thin-walled vessels in others. The cells are uniformly small and many have clear cytoplasm. × 119. (Courtesy of Beth Israel Hospital, Boston, Mass.)

Fig. 213

Fig. 213

VASCULAR LEIOMYOBLASTOMA

(Figures 212 and 213 from same case)

This photomicrograph reveals the reticulum fiber pattern of the tumor shown in figure 212. The reticulum fibers around the tumor cells are continuous with those in the vessel wall shown on the right. This pattern suggests the vascular origin of the tumor. Reticulum stain. × 95. (Courtesy of Beth Israel Hospital, Boston, Mass.)

LEIOMYOSARCOMA*

Leiomyosarcoma comprises about one percent of all gastric tumors (Table VI). There is a wide age range and an equal sex distribution. Leiomyosarcoma grossly resembles leiomyoma and particularly leiomyoblastoma, and there is great variation in size. The consistency of this tumor is often soft, focal areas of hemorrhage and necrosis are common, and the covering mucosa is ulcerated in about one-half the cases (figs. 214, 215). Cystic degeneration may be prominent in the larger tumors (fig. 216). Leiomyosarcoma occurs

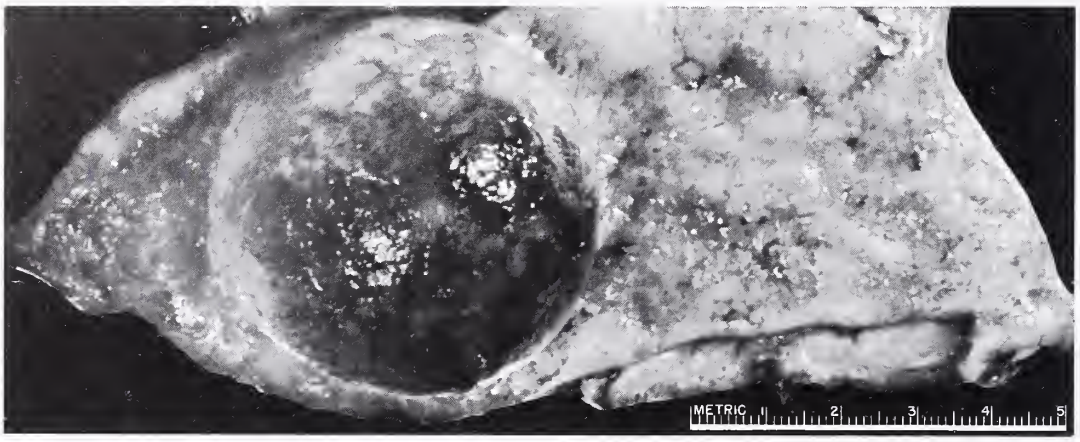

Fig. 214

LEIOMYOSARCOMA

This round mass is in the posterior wall of the midportion of the stomach of a 56-year-old man who had abdominal pain. The covering mucosa is atrophic, hemorrhagic, and superficially eroded. (Courtesy of Beth Israel Hospital, Boston, Mass.)

Fig. 215

Fig. 215

LEIOMYOSARCOMA

This photograph shows a large ulcerated area of the mucosa over this pedunculated tumor from a 66-year-old man, who had experienced weight loss and recent gastric bleeding. The tumor invaded through the posterior gastric wall and metastasized to the liver.

LEIOMYOSARCOMA

Fig. 216

This 9031 gm. tumor arose from the stomach and grew mainly into the peritoneal cavity of a 68-year-old woman, who had had a slowly enlarging mass in the upper abdomen for two years. The serosal covering was intact. The mucosa was focally ulcerated. This cut section shows many cystic areas.

anywhere in the gastric wall; about half are intragastric and form round or oval masses detectable roentgenologically (fig. 217). Many lesions, especially the larger ones, project outward on the serosal surface (fig. 216). A small number of these tumors are hourglass-shaped and have both intragastric and extragastric components. Clinical manifestations consist mainly of hemorrhage, pain, and a palpable mass, related partially to the location in the gastric wall. Obstruction may be a prominent feature when the tumor is located at or near the orifices.

Fig. 217

LEIOMYOSARCOMA

(Figures 217 and 218 from same case)

This roentgenogram reveals a large filling defect in the upper part of the stomach of an 87-year-old man who complained of weakness and had tarry stools. A portion of his stomach was resected. The tumor measured 6 cm. in diameter and extended to the subserosa. The mucosa was ulcerated.

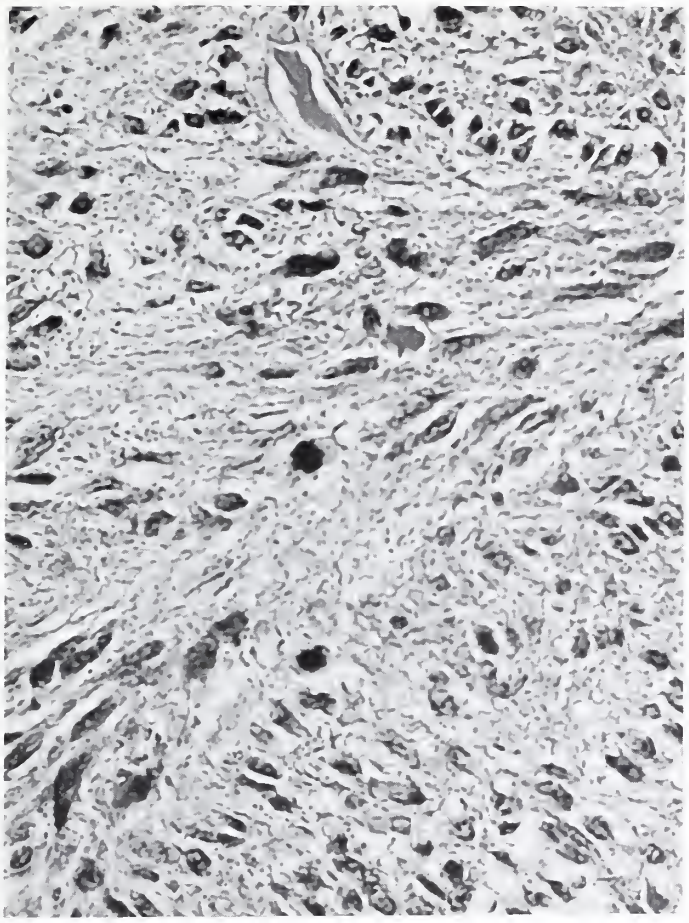

Fig. 218

LEIOMYOSARCOMA

(Figures 217 and 218 from same case)

This photomicrograph of the tumor seen in figure 217 reveals moderately differentiated cells. Mitoses are frequent. The cytoplasm has abundant fibrillar material. × 485.

Microscopically, most leiomyosarcomas are composed of spindle-shaped cells with varying amounts of cytoplasm in which myofibrils are identifiable (figs. 218, 219). Less differentiated cells with plump or polygonal configuration, similar to cells seen in leiomyoblastoma, may be present in some parts of the tumor (figs. 220, 221). In either instance, reticulum fibers around individual cells are generally present which probably represents basement membrane of cells seen by electron microscopy (fig. 222). The malignant nature of leiomyosarcoma is indicated by frequent mitoses (fig. 218), and by infiltration into adjacent tissues (fig. 219). Metastases are present in about one-fourth of cases (Skandalakis et al.). The treatment of choice is surgical removal of the tumor. Giberson and associates report a 5-year survival rate of 53.8 percent of surgically treated cases. Long survivals have been reported, even in the presence of metastases.

Fig. 219

LEIOMYOSARCOMA

This photomicrograph of a well differentiated leiomyosarcoma in a 32-year-old man shows invasion of the gastric mucosa. The tumor measured 7 cm. in diameter and had metastasized to the liver. × 90

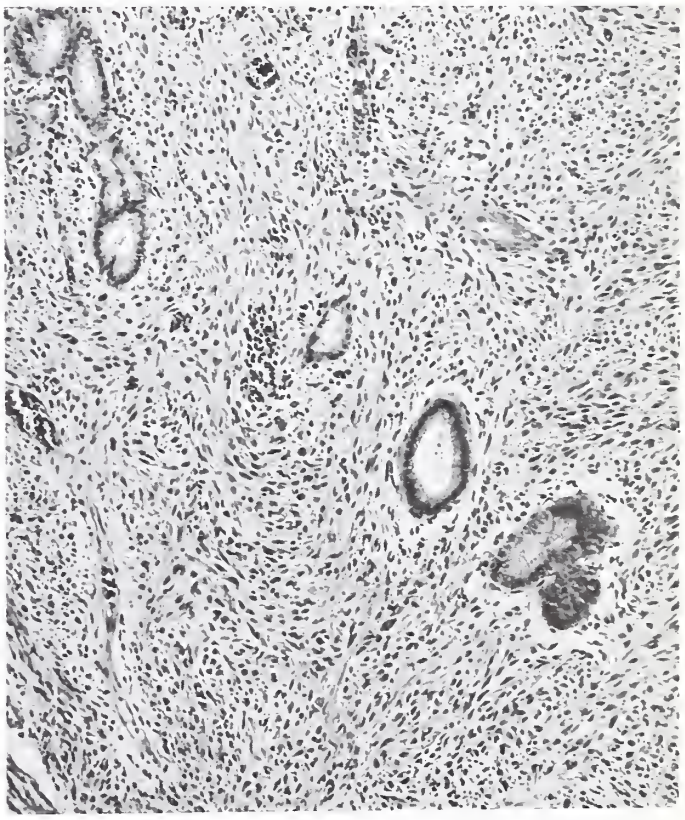

Fig. 219

LEIOMYOSARCOMA

(Figures 220–222 from same case)

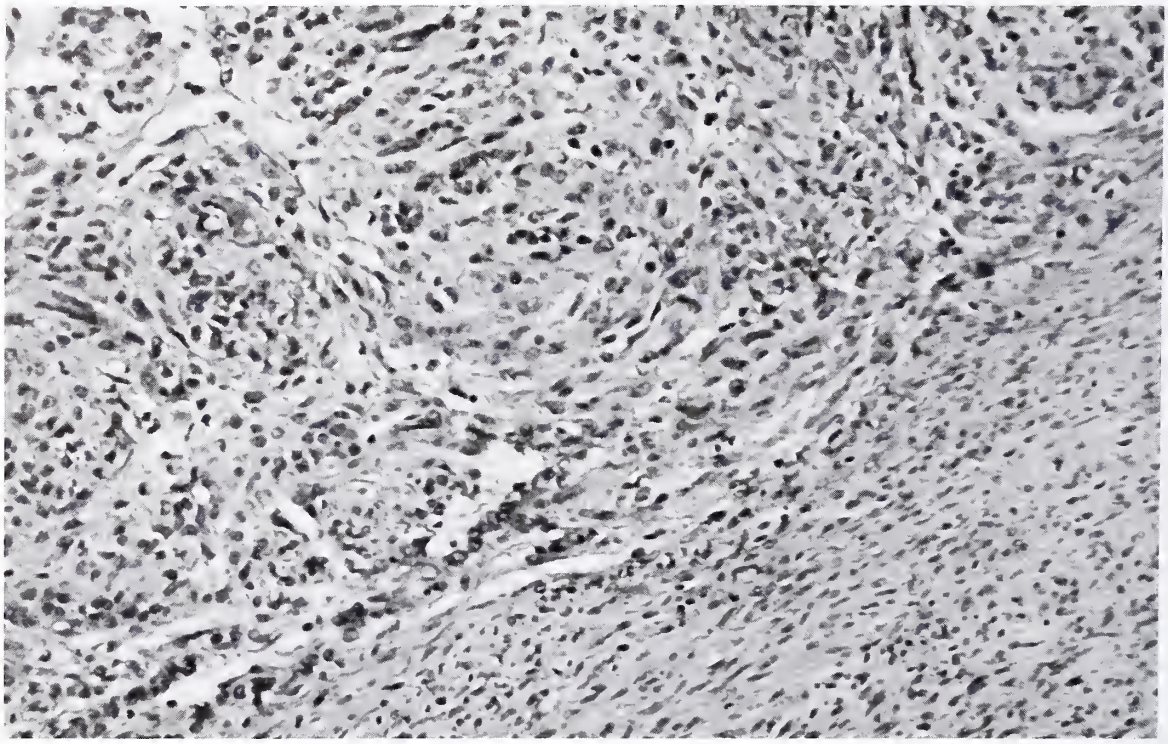

Fig. 220

This photomicrograph of a circumscribed submucosal tumor, in the stomach of a 69-year-old woman, shows spindle cells (lower right) and plump, more pleomorphic cells forming swirled bundles (upper left) × 168

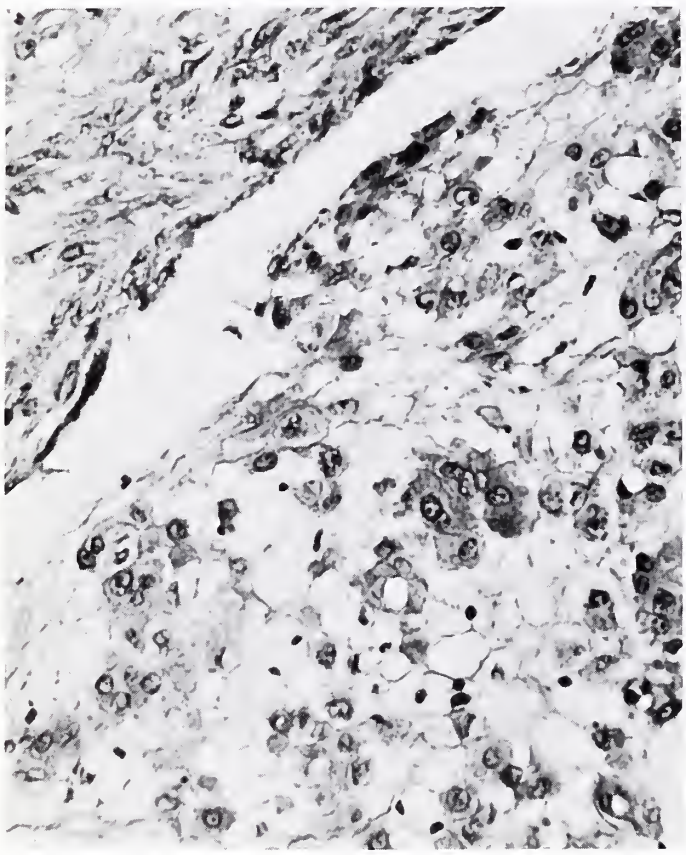

Fig. 221

Fig. 221

This photomicrograph of the same tumor shows a group of large polyhedral cells with granular cytoplasm. These cells somewhat resemble those in the leiomyoblastoma in figure 208 × 268

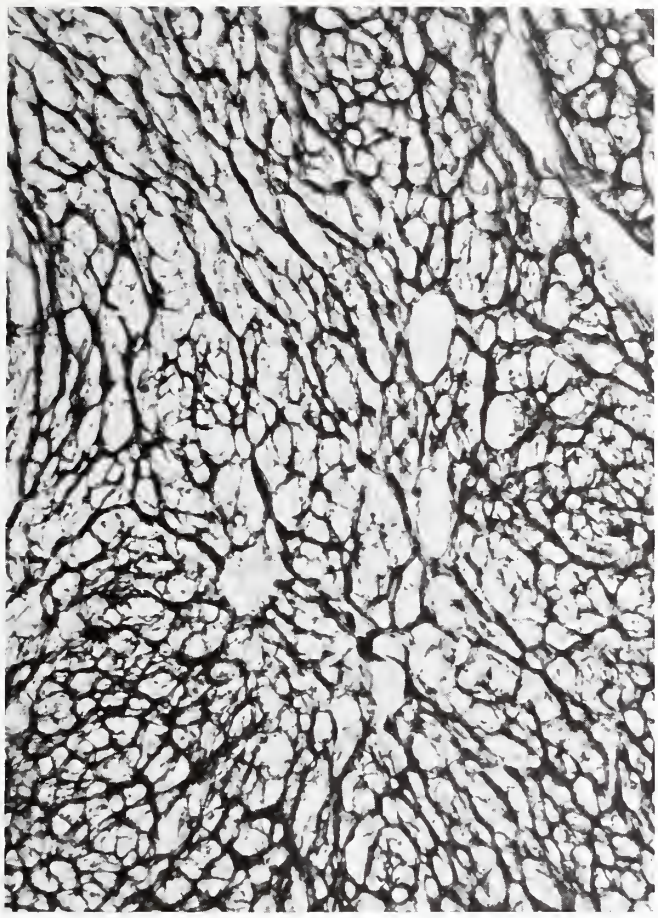

Fig. 222

LEIOMYOSARCOMA

(Figures 220–222 from same case)

In this photomicrograph of the same tumor shown in figure 220, the intricate pattern formed by dense reticulum fibers around individual cells is evident. Reticulum stain. × 350.

RHABDOMYOMA* AND RHABDOMYOSARCOMA*

Tuazon reported the incidental finding of gastric rhabdomyoma in a 47-year-old woman who had a rectal carcinoma. The gastric tumor measured 4.3 by 2.5 by 2.5 cm. and was composed of mature skeletal muscle cells. Stout (1953) illustrated a case of rhabdomyosarcoma coexisting with glandular carcinoma. Templeton and Heslin reported a 3-year-old boy with a huge rhabdomyosarcoma involving the entire stomach, with metastases to the regional and cervical lymph nodes.

References

Garvie, W. H. H. Leiomyosarcoma of the stomach. Brit. J. Surg. 52:32–38, 1965.

Giberson, R. G., Dockerty, M. B., and Gray, H. K. Leiomyosarcoma of the stomach. Clinicopathologic study of 40 cases. Surg. Gynec. Obstet. 98:186–196, 1954.

Kay, S., and Still, W. J. S. A comparative electron microscopic study of a leiomyosarcoma and bizarre leiomyoma (leiomyoblastoma) of the stomach. Amer. J. Clin. Path. 52:403–413, 1969.

Martin, J. F., Bazin, P., Féroldi, J., and Cabanne, F. Tumeurs myoïdes intra-murales de l'estomac, considération microscopiques à propos de 6 cas. Ann. Anat. Path. 5:484–497, 1960.

Meissner, W. A. Leiomyoma of the stomach. Arch. Path. 38:207–209, 1944.

Palmer, E. D. Benign intramural tumors of the stomach: a review with special reference to gross pathology. Medicine 30:81–181, 1951.

Salazar, H., and Totten, R. S. Leiomyoblastoma of the stomach. An ultrastructural study. Cancer 25:176–185, 1970.

Salmela, H. Smooth muscle tumours of the stomach. A clinical study of 112 cases. Acta Chir. Scand. 134:384–391, 1968.

Skandalakis, J. E., Gray, S. W., and Shepard, D. Smooth muscle tumors of the stomach. Int. Abstr. Surg. 110:209–226, 1960.

Smithwick, W., III, Biesecker, J. L., and Leand, P. M. Leiomyoblastoma: behavior and prognosis. Cancer 24:996–1003, 1969.

Stout, A. P. Tumors of the Stomach. Fascicle 21, Atlas of Tumor Pathology. Washington: Armed Forces Institute of Pathology, 1953.

———. Bizarre smooth muscle tumors of the stomach. Cancer 15:400–409, 1962.

Tallqvist, G., Salmela, H., and Lindström, B. L. Leiomyoblastoma of the stomach. A clinico-pathological study of 10 cases. Acta Path. Microbiol. Scand. 71:194–202, 1967.

Templeton, A. W., and Heslin, D. J. Primary rhabdomyosarcoma of the stomach and esophagus. Amer. J. Roentgen. 86:896–899, 1961.

Tuazon, R. Rhabdomyoma of the stomach. Report of a case. Amer. J. Clin. Path. 52:37–41, 1969.

Welsh, R. A., and Meyer, A. T. Ultrastructure of gastric leiomyoma. Arch. Path. 87:71–81, 1969.

Wolf, J. S. Massive leiomyoblastoma of the stomach. Arch. Surg. 96:284–288, 1968.

A

ULCERATED INFILTRATIVE CARCINOMA OF STOMACH

A An ulcerated, infiltrative carcinoma in the distal stomach, at the junction of the pyloric and fundic areas, has a raised tumor border and a broad ulcer at the center (Courtesy of Beth Israel Hospital, Boston, Mass.)

LEIOMYOBLASTOMA OF STOMACH

(Plate V-B and Figure 206 from same case)

B A bisected, submucosal leiomyoblastoma from the posterior wall of the stomach in a 63-year-old woman reveals focal areas of hemorrhage and necrosis. The mucosal surface is shown in figure 206 (Courtesy of Beth Israel Hospital, Boston, Mass.)

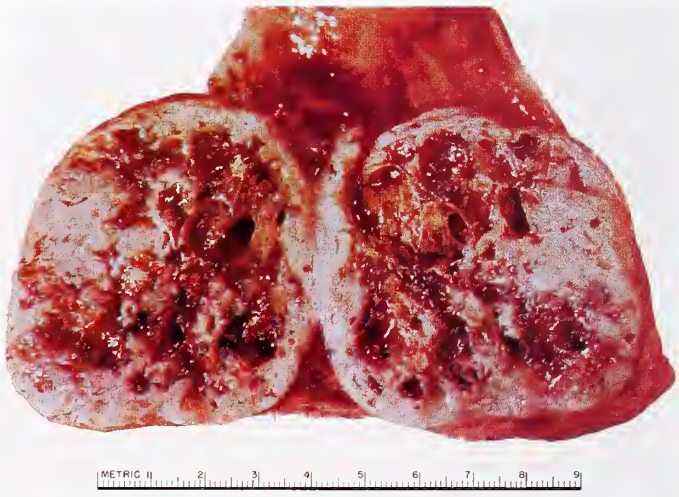

B

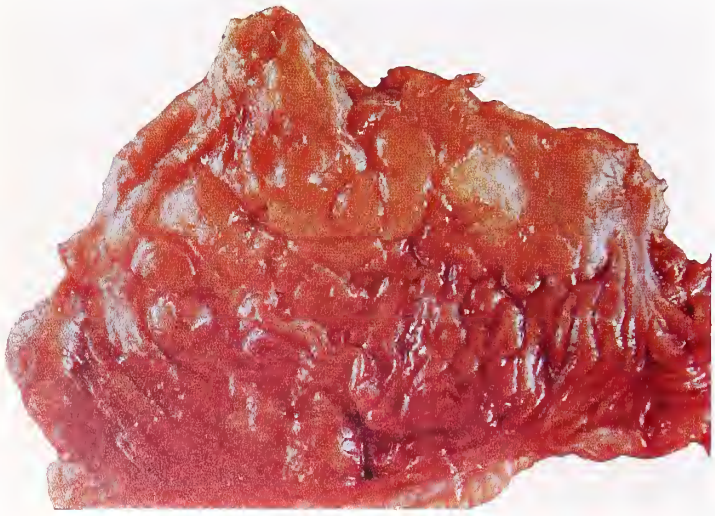

C

LYMPHOMA OF STOMACH

C Multiple mucosal and submucosal nodules and plaques in the stomach are composed of lymphomatous tissue. The mucosal surface of the small nodules is intact and that of the large plaques is superficially eroded (Courtesy of Beth Israel Hospital, Boston, Mass.)

PLATE V

TUMORS OF LYMPHOID TISSUE

MALIGNANT LYMPHOMA

SYNONYMS AND RELATED TERMS **Lymphocytic lymphosarcoma.**

The gastric mucosa in infants and children has no lymphoid tissue. In adults, aggregates of lymphocytes are commonly present, occasionally containing germinal follicles. Malignant lymphoma develops in the mucosa from which the tumor cells infiltrate into the submucosa and muscularis. This mode of growth is the same as that of carcinoma. Lymphoma, therefore, often assumes the gross characteristics of carcinoma, and gross distinction between carcinoma and lymphoma may be difficult. Lymphomas are the most common sarcomas of the stomach (Table VI). In most instances, the gastric lymphomas, particularly the small ones, are local manifestations of a disseminated disease which is already evident or will be manifest later; only occasionally, the tumor is limited to the stomach and regional lymph nodes. Gall and Mallory reported involvement of the gastrointestinal tract in 13 percent of lymphoma cases; in 2 percent, the lesion was initially localized in the stomach.

Grossly, many of the tumors are ulcerated, with rolled elevated borders (figs. 223—225). The thickness of the margin and the tumor mass vary from case to case. Some tumors are polypoid (fig. 224) and others cause extensive thickening of the gastric wall (fig. 226). Occasionally, marked infiltration in the mucosa results in a rigid giant rugal pattern. Multiple lymphomatous nodules may be present in the same stomach (figs. 227, 228; pl. V—C). Of 65 cases of primary gastric lymphoma studied by Joseph and Lattes, multiple tumors were present in 13 and large rugae were found in five cases. In most of their cases, the tumor was ulcerated.

Fig 223

Fig. 223

LYMPHOMA, HISTIOCYTIC TYPE

This ulcerated lymphoma found in the distal portion of the stomach of a 66-year-old woman has a large, deep ulcer and raised borders. It had infiltrated through the gastric wall, but regional lymph nodes were not involved. A glimpse of the cut section reveals its gray homogeneous appearance. (Courtesy of Beth Israel Hospital, Boston, Mass.)

LYMPHOMA, HISTIOCYTIC TYPE

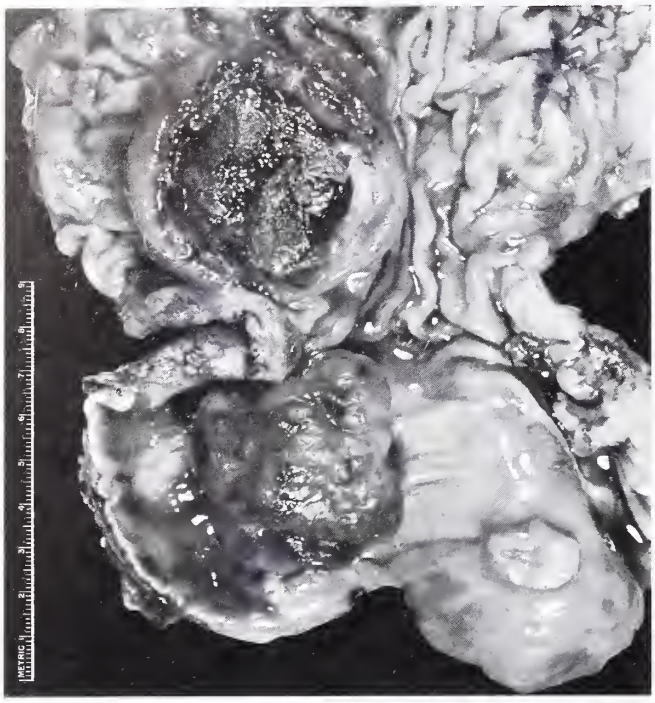

Fig. 224

Fig 224

This photograph shows three areas of lymphomatous infiltration in the stomach of a 48-year-old man. The upper lesion in the anterior wall of the midportion of the stomach is ulcerated, with raised borders. The lesion just below is a necrotic nodular mass. The third lesion (lower right) in the distal portion of the stomach is mainly submucosal, with ulceration of the mucosa. Regional lymph nodes were not involved.

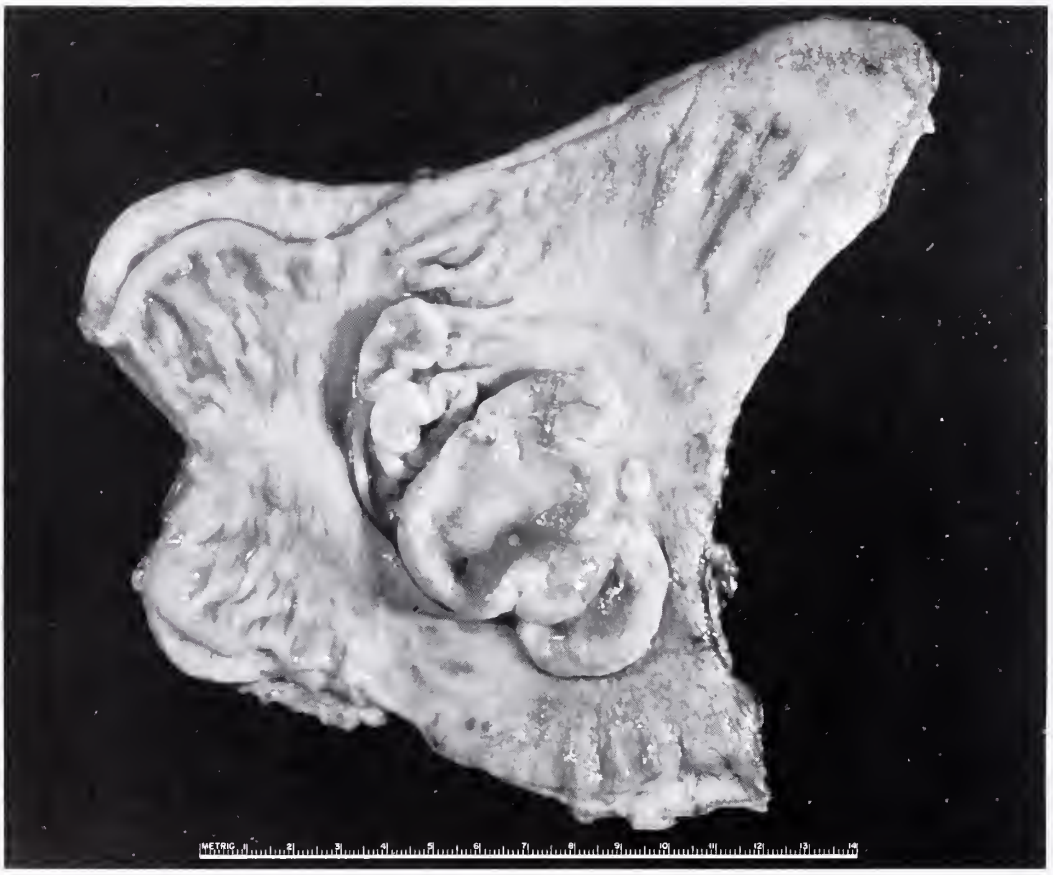

Fig. 225

This photograph shows one large and two small ulcerated lesions on the lesser curvature of the distal part of the stomach and several small, nonulcerated, submucosal nodules in other areas. (Courtesy of The Massachusetts General Hospital, Boston, Mass.)

LYMPHOMA, HISTIOCYTIC TYPE

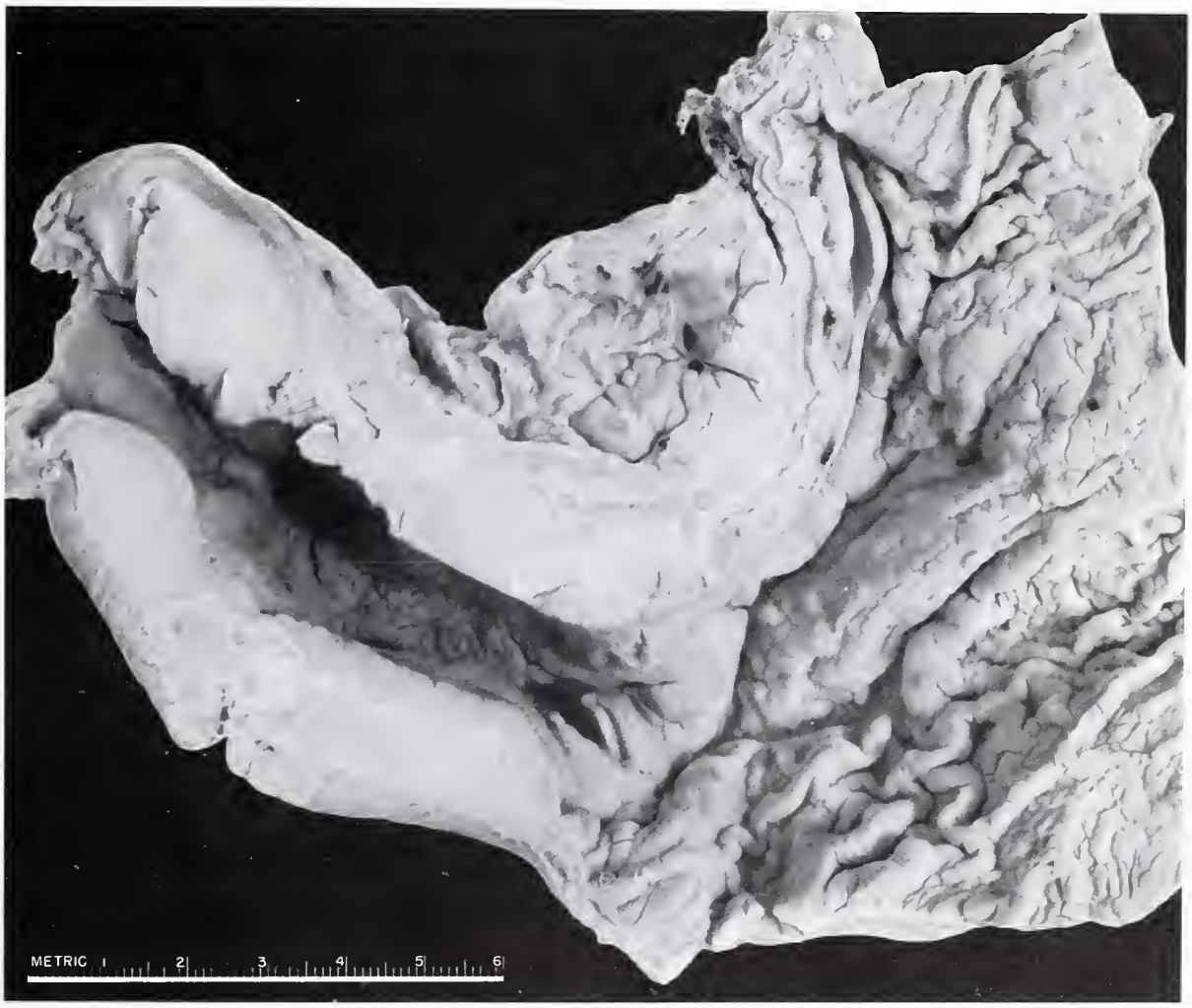

Fig 226

A 34-year-old man had dyspepsia for four months and died of peritonitis, following perforation of an ulcerated tumor This large lymphoma involved the distal half of the stomach. Zones of necrosis are seen on the cut surface as pale geographic areas

LYMPHOMA, HISTIOCYTIC TYPE

(Figures 227 and 228 from same case)

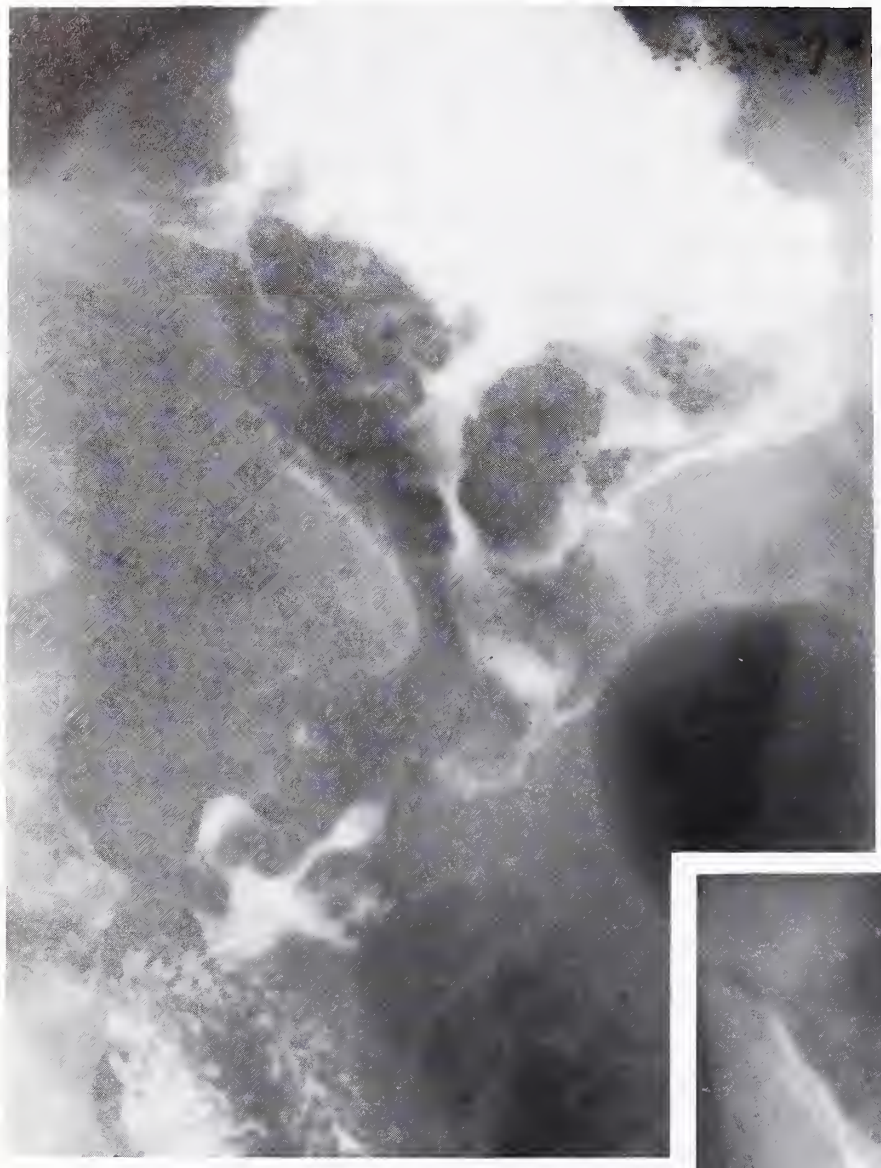

Fig. 227

This roentgenogram of the stomach of a 60-year-old woman, taken after a barium meal, shows large filling defects in the upper and midportions.

Fig. 228

Fig. 228

This roentgenogram, taken with barium in the distal segment of the stomach, shows round, soft tissue shadows in the area illustrated in the previous figure. There were two large tumor nodules in the upper portion and nodular thickening in the midportion of resected stomach. Regional lymph nodes and the spleen were not involved.

The histologic appearance of gastric lymphomas is the same as lymphomas in other organs. There are dense accumulations of tumor cells with a seemingly uniform pattern. Close inspection, however, often reveals varying degrees of an admixture of mature and immature lymphoid cells and histiocytic (reticulum) cells. Stobbe and associates classified lymphomas into four grades, according to the proportion of mature and immature cells, in about an equal number of cases. In other reports, the tumors were generally classified into lymphocytic or lymphoblastic type, histiocytic (reticulum cell) type, Hodgkin's disease, and follicular (nodular) type. About 60 percent of gastric lymphomas reported were of the lymphoblastic or lymphocytic type, 4 percent were Hodgkin's disease, and the remaining tumors were histiocytic lymphoma. Histologic differentiation between histiocytic lymphoma and undifferentiated carcinoma may be difficult. The dense cellular infiltration with relatively sudden demarcation from normal tissue, and lack of concomitant fibrous tissue proliferation favors lymphoma (figs. 229, 231). Mucosal glands may be absent in lymphoma, but any remaining glands generally retain their normal architecture (fig. 230). Carcinoma cells are usually pleomorphic with a moderate amount of cytoplasm, and adjacent mucosal glands frequently reveal atypical hyperplasia. Pleomorphism in lymphoma is most prominent in the histiocytic type; even in such cases, variations in the nuclear pattern are rather mild (fig.

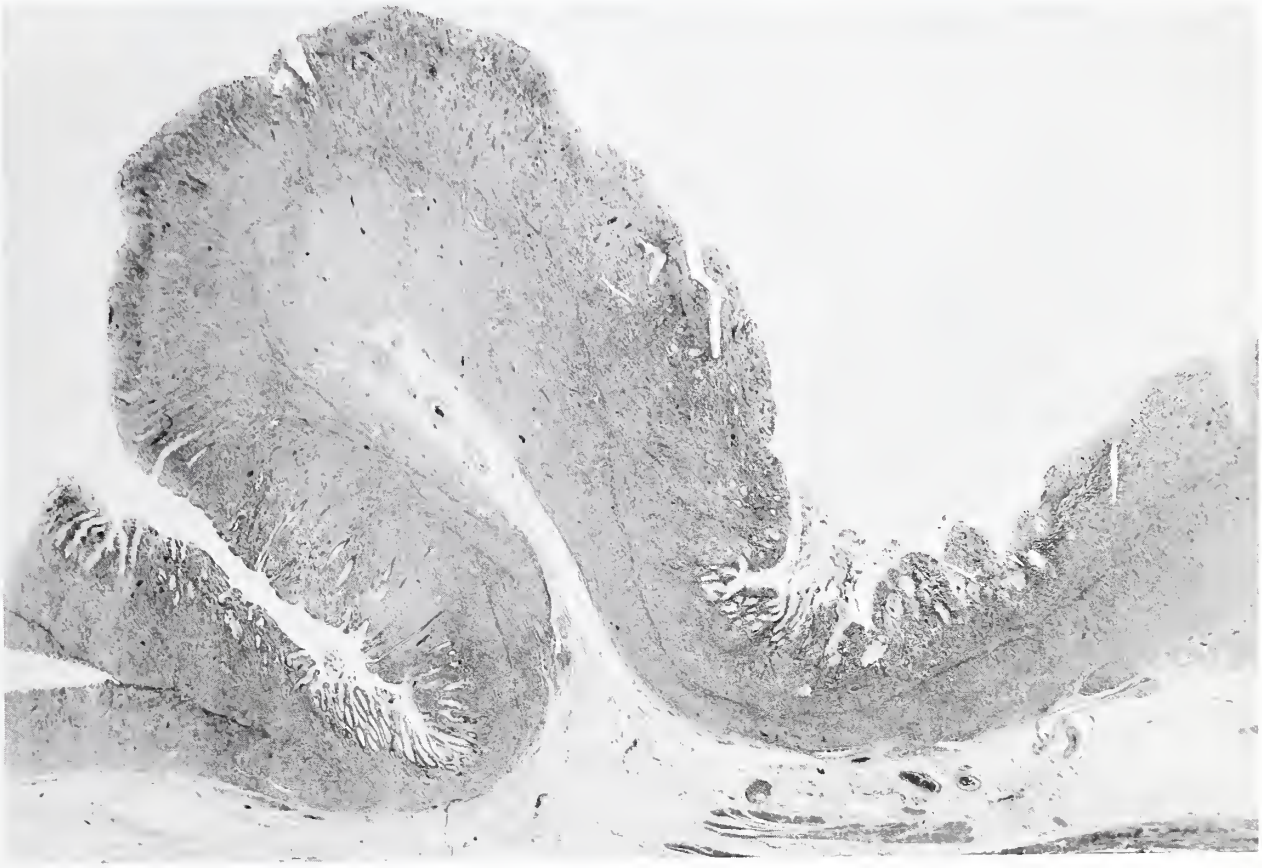

Fig 229

LYMPHOMA, LYMPHOBLASTIC TYPE

(Figures 229 and 230 from same case)

Lymphomatous infiltration mainly involves the mucosa, which produces the gross appearance of giant rugae. Scattered mucosal glands are seen. The dark line in the tumorous area represents muscularis mucosae. × 7 (Courtesy of Beth Israel Hospital, Boston, Mass.)

232). The presence of reticulum fibers (fig. 233) and absence of stainable mucin are additional features favoring lymphoma. Hodgkin's disease (pl. VI – A) is characterized by the presence of Sternberg-Reed cells (fig. 234). The differentiating features between lymphoma and pseudolymphoma have been discussed on pages 110 – 113.

Lymph nodes were involved in gastric lymphoma in 23 percent (Joseph and Lattes) to 62 percent of cases (Sherrick et al.), and distant organs were involved in about 10 percent of cases (Naqvi et al.). Depending upon location and extent of the tumor, treatment of choice has been partial or total gastrectomy, followed by radiation therapy. The survival rate is influenced by cell types, degree of extension, and status of the lymph nodes. The overall 5-year survival rate in gastric lymphoma was 29 percent (Naqvi et al.) and in resected cases, 40 percent (Nicoloff et al.; Salmela) to 67 percent (Stobbe et al.).

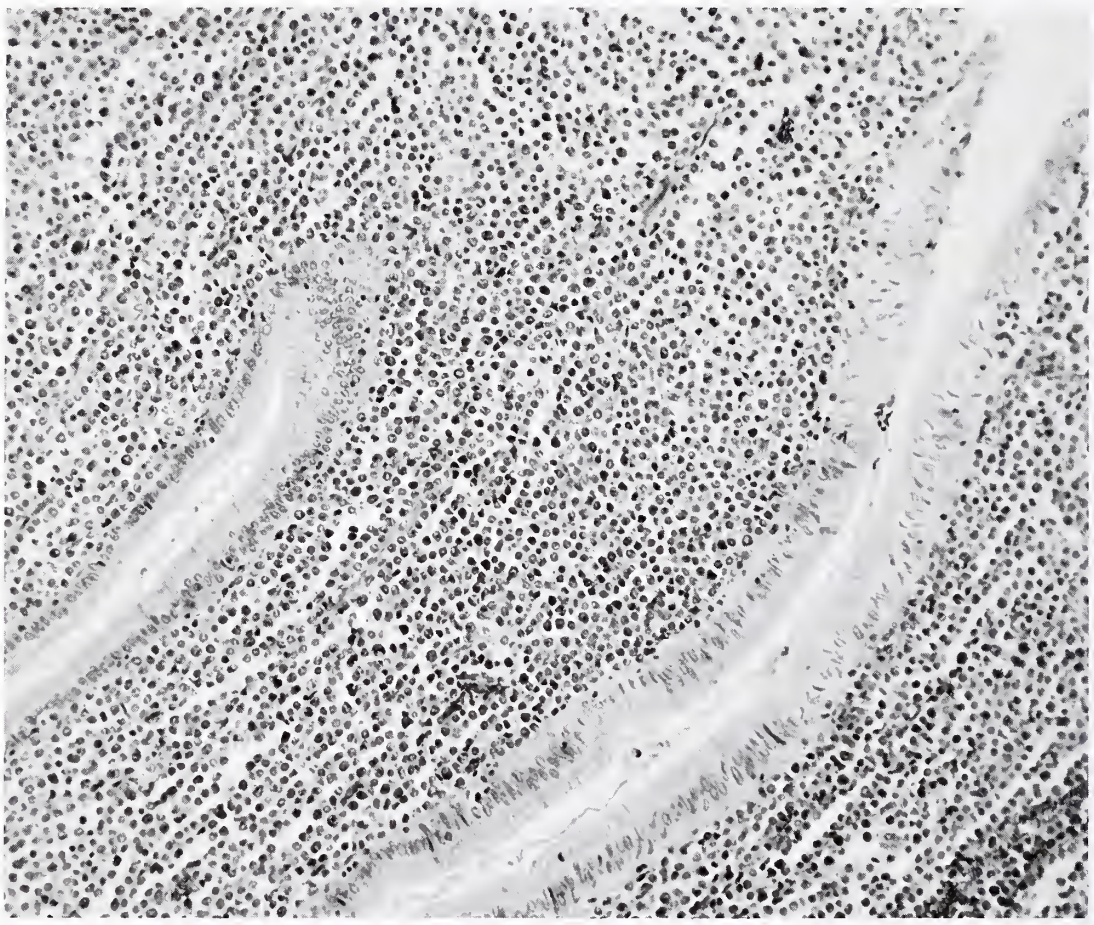

Fig. 230

LYMPHOMA, LYMPHOBLASTIC TYPE

(Figures 229 and 230 from same case)

A higher power view of the mucosa reveals the uniform distribution and cellular pattern of the lymphoma cells. The interposed glands are unaltered. × 150 (Courtesy of Beth Israel Hospital, Boston, Mass.)

LYMPHOMA, HISTIOCYTIC TYPE

(Figures 231 and 232 from same case)

Fig 231

This is a photomicrograph showing diffuse uniform infiltration of lymphoma cells throughout the gastric wall. The surface is eroded, and only a few gastric glands remain × 20 (Courtesy of Beth Israel Hospital, Boston, Mass.)

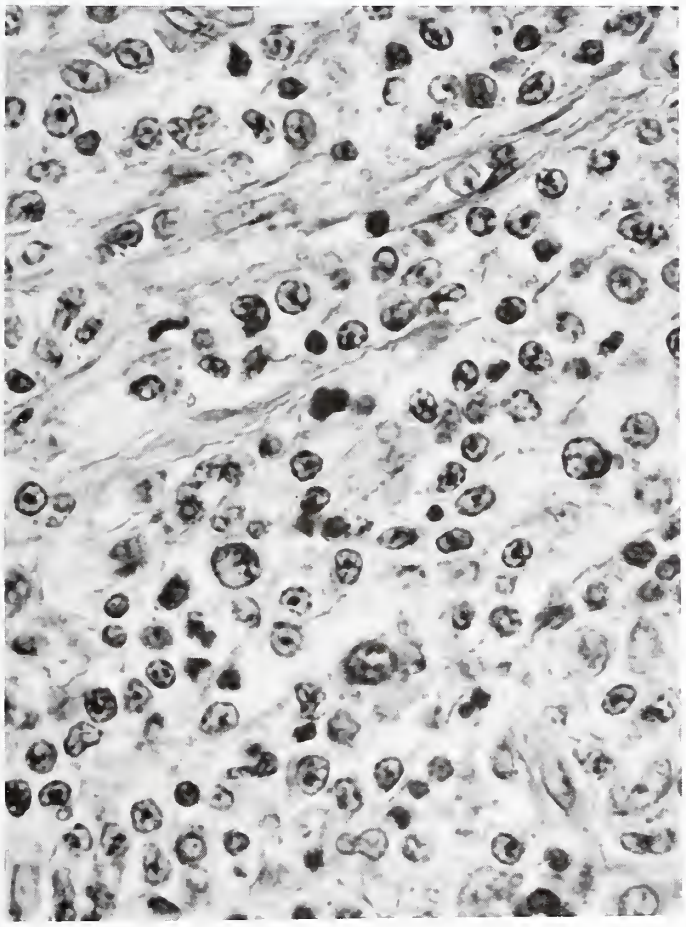

Fig. 232

Fig. 232

This illustrates the cellular elements of the lymphoma seen in figure 231, which consist of immature histiocytic cells with prominent nucleoli and slight variation in nuclear size. The cytoplasm is scanty × 670. (Courtesy of Beth Israel Hospital, Boston, Mass.)

Fig. 233

LYMPHOMA, HISTIOCYTIC TYPE

This photomicrograph shows reticulum fibers in a histiocytic lymphoma of the stomach of a 58-year-old man. Tumor cells were large with a moderate amount of cytoplasm and frequent nucleoli. The tumor also involved the retroperitoneum. Reticulum stain. × 490.

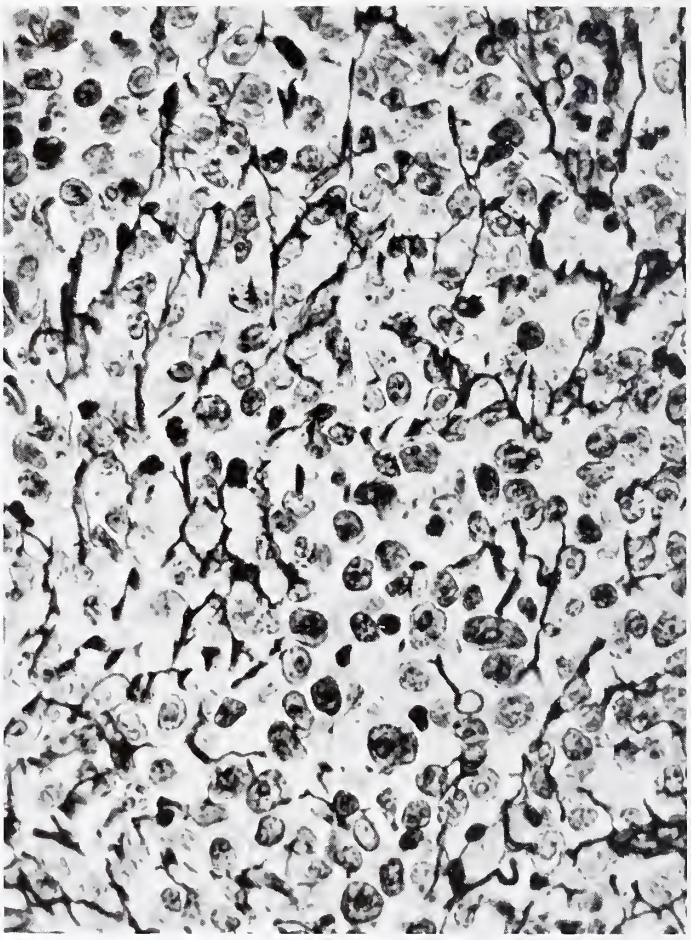

Fig. 233

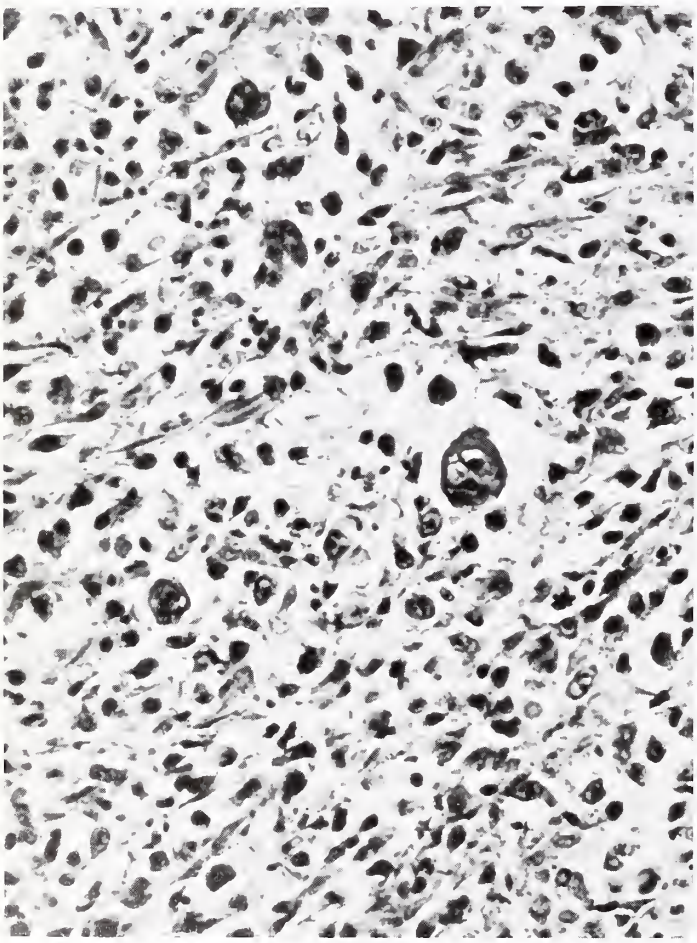

Fig. 234

Fig. 234

HODGKIN'S DISEASE

This photomicrograph of a gastric tumor in a 38-year-old woman shows mixed small and large lymphoid tumor cells and scattered Sternberg-Reed cells. × 225.

PLASMACYTOMA

SYNONYMS AND RELATED TERMS **Extraosseous plasmacytoma (benign or malignant);** extramedullary plasmacytoma; multiple myeloma.

Primary gastric plasmacytoma is very rare. In 1959, Annamunthodo and Robertson collected 10 reported cases; three had gastric as well as intestinal involvement and seven cases were isolated gastric plasmacytomas. The latter number was increased to 21 cases by 1966 according to Fraser and associates. These tumors were found in both men and women, generally over 40 years of age. Many of these patients had a long history suggestive of peptic ulcer. The tumors were usually ulcerated masses located in the distal stomach, and grossly resembled lymphoma or carcinoma (pl. VI–B). The regional lymph nodes were involved in most cases and bone lesions developed in a few (Line and Lewis; Remigio and Klaum). Thus, the gastric lesion may be the initial manifestation of multiple myeloma. Laboratory tests generally revealed normal serum protein patterns, and Bence-Jones proteins were absent.

Treatment has been radical gastrectomy because of the usual diagnosis of carcinoma at operation. The tumor is radioresponsive, but the prognosis is poor. Plasmacytoma should be differentiated from plasma cell granuloma of inflammatory nature (Soga et al.). Plasmacytoma consists of both mature and immature cells in dense conglomeration (fig. 235). In plasma cell granuloma, the plasma cells are mature, often contain Russell bodies, and they are mixed with other inflammatory cells and fibrous tissue.

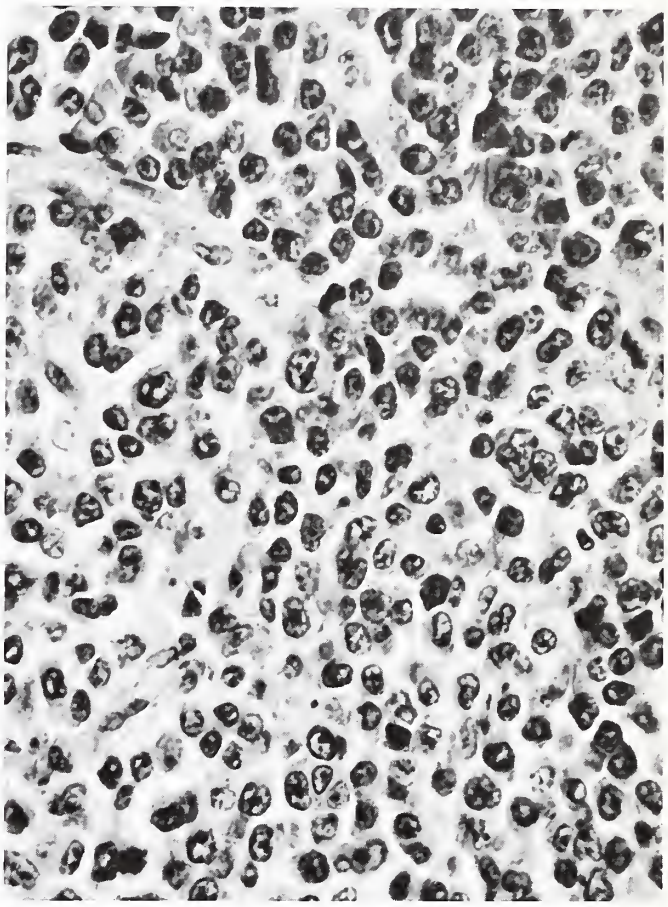

Fig. 235

PLASMACYTOMA

(Figure 235 and Plate VI-B from same case)

This photomicrograph of the tumor illustrated in plate VI-B reveals plasma cells showing mild pleomorphism. Some have nucleoli and some are binucleated. × 450. (Courtesy of Dr. H. T. Enterline, Philadelphia, Pa.)

References

Annamunthodo, H., and Robertson, W. B. Primary plasmacytoma of the stomach. Brit. J. Surg. 46:449–453, 1959.

Brock, D. P., Floyd, C. E., and Bliss, B. O. Gastric plasmacytoma: case report. Amer. Surg. 31:519–524, 1965.

Fraser, R. W., Jr., Schuh, F. D., and Mullen, E. E. Gastric myeloma: case report of extramedullary plasmacytoma and review of literature. Amer. Surg. 32:71–77, 1966.

Gall, E. A., and Mallory, T. B. Malignant lymphoma, a clinico-pathologic survey of 618 cases. Amer. J. Path. 18:381–429, 1942.

Joseph, J. I., and Lattes, R. Gastric lymphosarcoma: Clinicopathologic analysis of 71 cases and its relation to disseminated lymphosarcoma. Amer. J. Clin. Path. 45:653–669, 1966.

Line, D. H., and Lewis, R. H. Gastric plasmacytoma. Gut 10:230–233, 1969.

Loehr, W. J., Mujahed, Z., Zahn, F. D., Gray, G. F., and Thorbjarnarson, B. Primary lymphoma of the gastrointestinal tract: A review of 100 cases. Ann. Surg. 170:232–238, 1969.

Naqvi, M. S., Burrows, L., and Kark, A. E. Lymphoma of the gastrointestinal tract: Prognostic guides based on 162 cases. Ann. Surg. 170:221–231, 1969.

Nicoloff D M., Haynes, L B., and Wangensteen, O. H Primary lymphosarcoma of the gastrointestinal tract Surg. Gynec. Obstet 117.433–437, 1963

Remigio, P A., and Klaum, A Extramedullary plasmacytoma of stomach Cancer 27.562–568, 1971.

Salmela, H Lymphosarcoma of the stomach. A clinical study of 39 cases Acta Chir. Scand. 134.567–576, 1968.

Sherrick, D W., Hodgson, J R., and Dockerty, M. B The roentgenologic diagnosis of primary gastric lymphoma. Radiology 84.925–932, 1965.

Soga, J., Saito, K., Suzuki, N., and Sakai, T Plasma cell granuloma of the stomach. A report of a case and review of the literature Cancer 25.618–625, 1970.

Stobbe, J A., Dockerty, M B., and Bernatz, P E Primary gastric lymphoma and its grades of malignancy Amer J Surg 112.10–19, 1966

TUMORS OF VASCULAR TISSUE

Vascular tumors of the stomach are rare (Tables VI, VIII). Older literature contains reported cases of endothelioma and angiosarcoma (Palmer). It is difficult to evaluate the exact nature of such cases; the author has not seen any example.

HEMANGIOMA

SYNONYMS AND RELATED TERMS Capillary hemangioma, cavernous (venous) hemangioma; arterial hemangioma

Hemangioma of the stomach has been reported in a wide range of age groups; about one-fourth of these lesions occurred in patients less than 30 years old. Occasional large tumors have been seen. Kerekes reported a lesion composed of large vascular structures involving the entire greater curvature of the stomach in a 22-year-old woman. Such cases probably represent vascular malformations. Many hemangiomas are small, measuring less than 1 cm. in diameter. They may become ulcerated, and bleeding is the main clinical manifestation (Bongiovi and Duffy; Thyssen).

LYMPHANGIOMA*

Few lymphangiomas have been reported. They form cystic submucosal nodules (fig. 236) consisting of dilated lymphatic vessels (fig. 237). Some cases probably represent only lymphangiectasis rather than tumor (Chodack and Hurwitz).

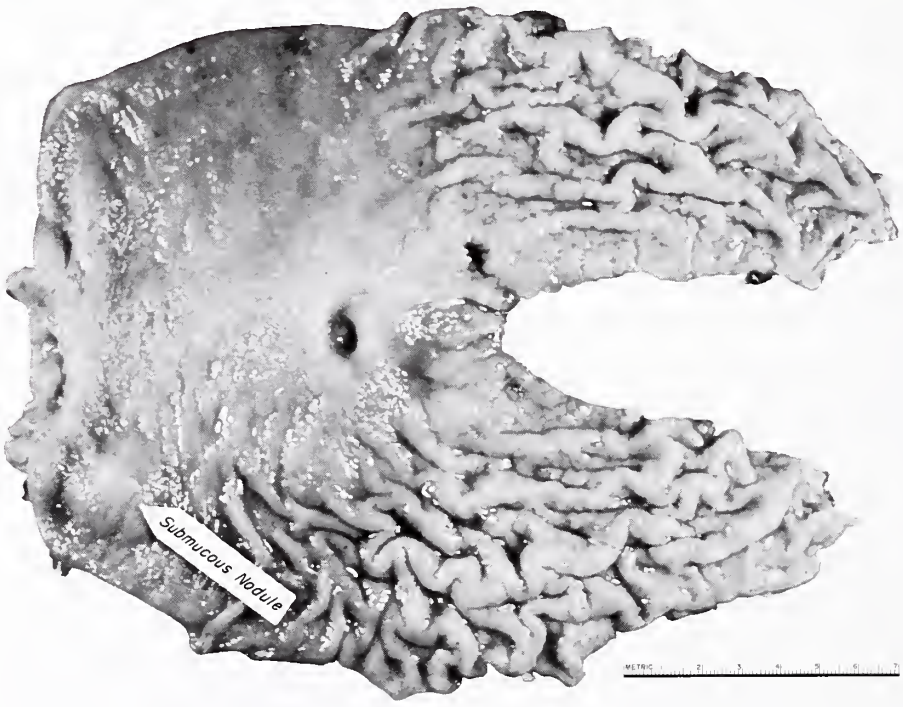

Fig. 236

LYMPHANGIOMA

(Figures 236 and 237 from same case)

A submucosal lymphangioma (arrow) was found incidentally near the pylorus in this stomach resected for an ulcer of the lesser curvature. (Fig. 27 from Stout, A P. Tumors of the Stomach. Fascicle 21, Atlas of Tumor Pathology. Washington. Armed Forces Institute of Pathology, 1953.)

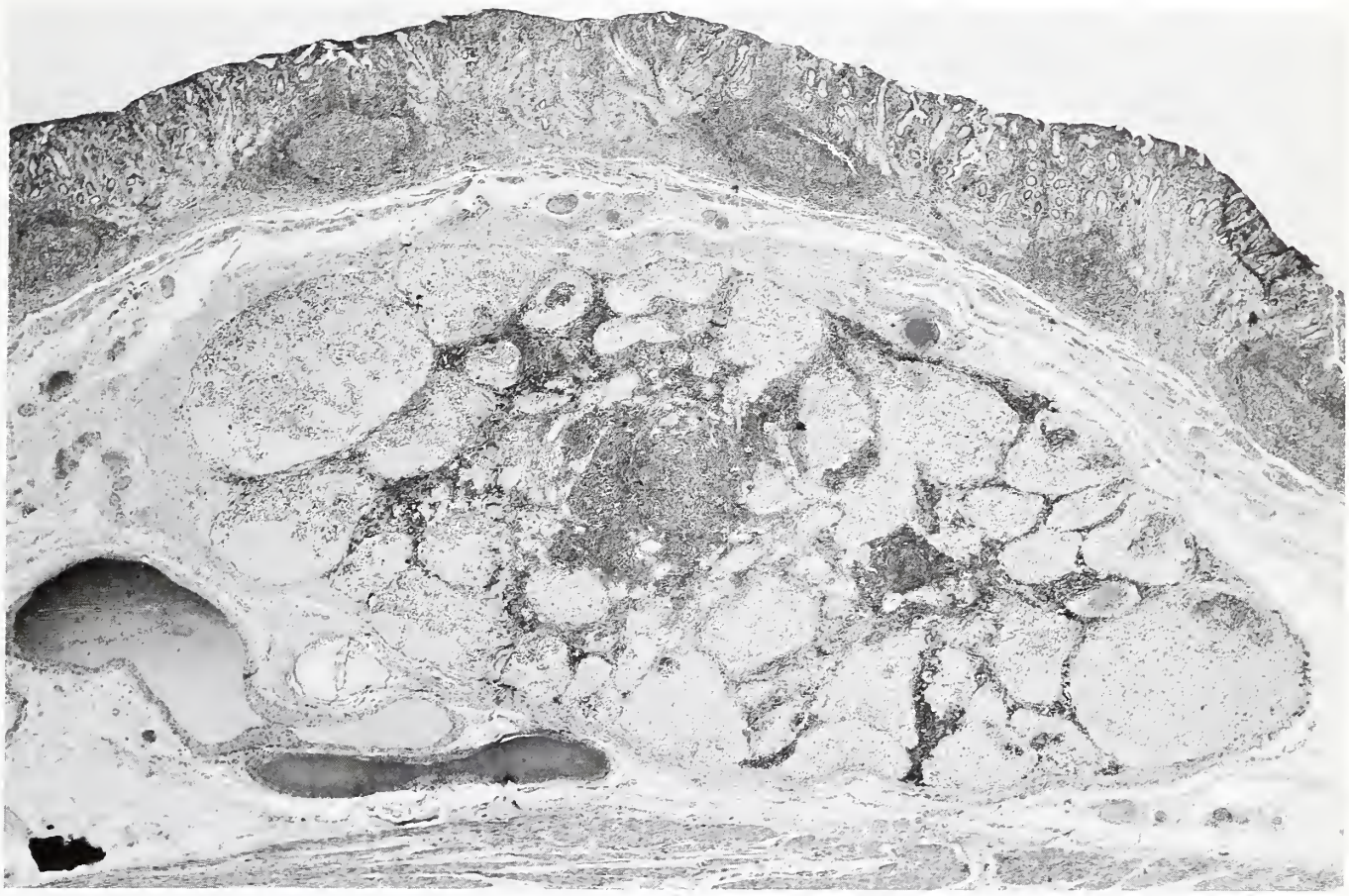

Fig 237

LYMPHANGIOMA

(Figures 236 and 237 from same case)

This photomicrograph of the same tumor shows dilated lymphatics and lymphoid tissue. (Fig. 28 from Stout, A. P. Tumors of the Stomach. Fascicle 21, Atlas of Tumor Pathology. Washington. Armed Forces Institute of Pathology, 1953.)

GLOMUS TUMOR*

Glomus tumor is the most frequently reported vascular tumor in the stomach since Kay and associates reported three cases in 1951. Weitzner collected 24 reported cases in 1969, and Appelman and Helwig described 12 cases from the files at the Armed Forces Institute of Pathology. The age of patients ranges between 30 and 89 years. There is an equal sex distribution. Most tumors are found in the distal portion of the stomach (pl. VI–C). They are located primarily in the submucosa, but extension into the muscularis externa is common. Glomus tumors form sessile masses measuring 1 to 4 cm. in diameter. Ulceration of the covering mucosa results in bleeding which is the major clinical symptom. Microscopically, the tumor is composed of thin-walled vascular structures surrounded by masses of uniform cells (figs. 238, 239). The cells have round nuclei and scanty or moderate amounts of cytoplasm which may have a clear zone around the nucleus (Kay et al.). Electron microscopic studies reveal many free ribosomes, sparse endoplasmic reticulum, indentations of cytoplasmic membrane, dense particles, fine fibrils, and pinocytotic vesicles resembling features of smooth muscle cells (Toker). Complete excision of the tumor has resulted in cure.

GLOMUS TUMOR

Fig 238

This photomicrograph shows the characteristic uniform tumor cells and many vessels of a glomus tumor, found by chance in the stomach of a 50-year-old man who had carcinoma of the pylorus (Fig 1 from Kay, S., Callahan, W P., Jr., Murray, M R., Randall, H T., and Stout, A P Glomus tumors of the stomach. Cancer 4 726–736, 1951; also fig 25 from Stout, A P Tumors of the Stomach. Fascicle 21, Atlas of Tumor Pathology. Washington: Armed Forces Institute of Pathology, 1953.)

Fig 239

A 71-year-old man had his stomach resected for duodenal ulcer This is a photomicrograph of an incidental well circumscribed submucosal mass, measuring 3 cm. in greatest dimension, in the posterior wall of the stomach. The tumor is composed of uniform cells, with round nuclei and thin-walled vascular spaces. × 520. (Courtesy of Dr. I W Grossman, Brattleboro, Vt.)

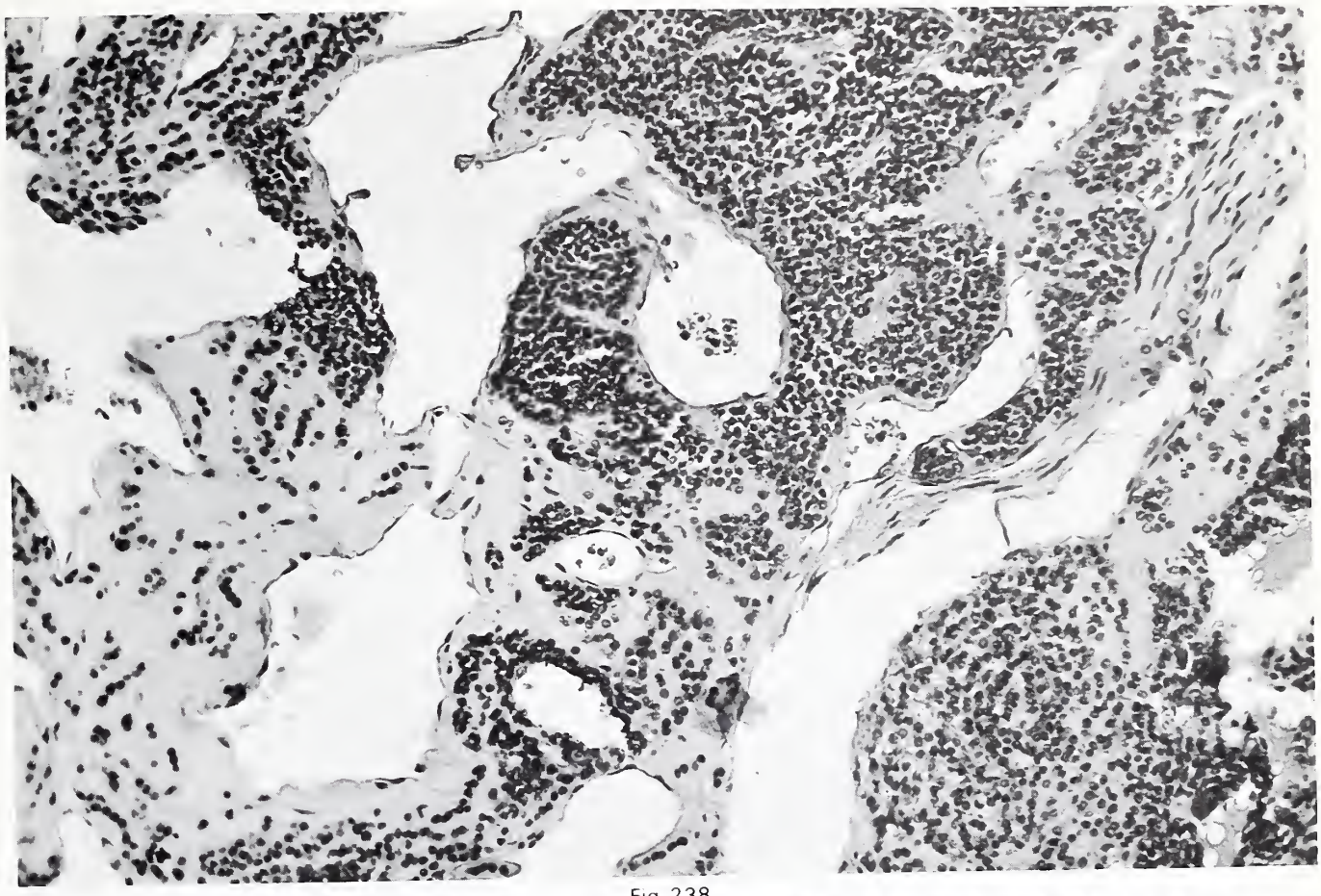

Fig. 238

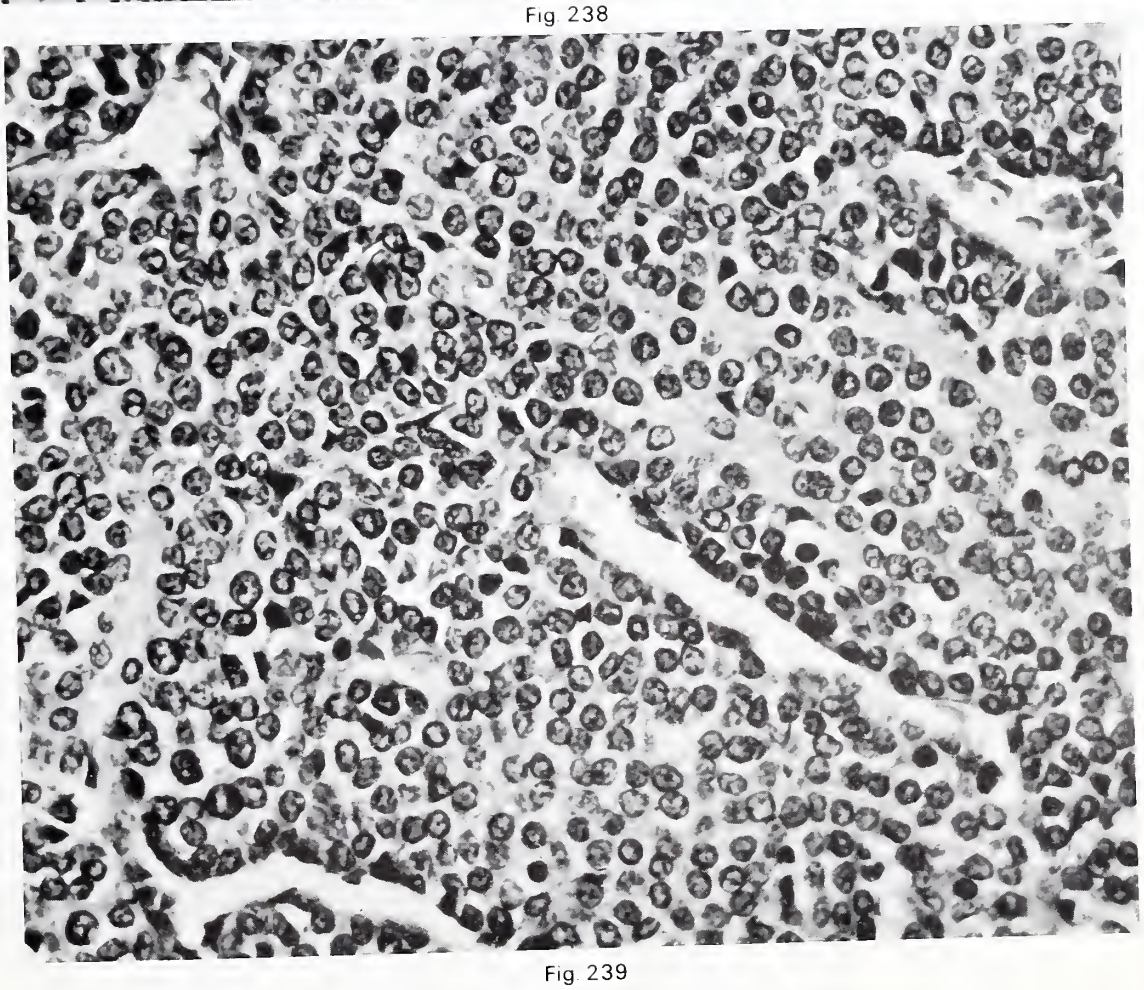

Fig. 239

HODGKIN'S DISEASE OF STOMACH

A. The tumor was deeply ulcerated, with a thick border covered by intact mucosa (Pl. VI-B from Stout, A. P. Tumors of the Stomach. Fascicle 21, Atlas of Tumor Pathology. Washington: Armed Forces Institute of Pathology, 1953.)

PLASMACYTOMA OF STOMACH

(Plate VI-B and Figure 235 from same case)

B. This is a portion of stomach resected from a 61-year-old man. The gastric wall is pale gray, firm, and measures up to 5 cm. in thickness. The luminal aspect is hemorrhagic and necrotic. (Courtesy of Dr. H. T. Enterline, Philadelphia, Pa.)

GLOMUS TUMOR OF STOMACH

C. The round tumor was mainly submucosal; the covering mucosa was intact except for a central ulcer (Pl. IV-B from Stout, A. P. Tumors of the Stomach. Fascicle 21, Atlas of Tumor Pathology. Washington: Armed Forces Institute of Pathology, 1953.)

PLATE VI

HEMANGIOPERICYTOMA*

SYNONYMS AND RELATED TERMS: **Malignant hemangiopericytoma**; angiosarcoma; hemangioendothelioma, hemangiopericytic sarcoma, perithelial angiosarcoma; perithelioma.

Hemangiopericytoma resembles glomus tumor microscopically in its general vascular pattern. However, the cells in hemangiopericytoma are larger and either round, resembling epithelial cells, or elongated. These cells are surrounded by reticulum fibers, but this feature is not diagnostic. The reported gastric hemangiopericytomas have been polypoid tumors composed of fibrous-appearing tissue surrounding scattered blood vessels (Marangos; Stout). Many of these tumors were probably inflammatory fibroid polyps (Helwig and Ranier), in which a perivascular arrangement of elongated cells and reticulum fibers are also present (figs. 89, 90). Of 12 reported cases of hemangiopericytoma collected by Marangos, none were malignant. Ernst and associates reported a malignant hemangiopericytoma of the stomach in a 40-year-old woman who had multiple nodular masses and metastases to regional lymph nodes. A similar tumor had been removed from her stomach when she was 15 years of age.

KAPOSI'S DISEASE

SYNONYMS AND RELATED TERMS: **Hemorrhagic sarcoma (Kaposi)**; angiosarcoma multiplex; granuloma multiplex hemorrhagicum; multiple idiopathic hemorrhagic sarcoma; perithelioma multiplex.

In Kaposi's disease, Byrne found visceral involvement in 10 percent of cases, appearing most commonly in the gastrointestinal tract. Lesions in the stomach resemble those in the skin. They are small and sessile with a hemorrhagic or bluish discoloration. The lesions are located mainly in the submucosa, but the mucosa may also be involved and occasionally is ulcerated. Microscopically, they are composed of elongated cells and anastomosing capillaries with foci of recent hemorrhage and deposits of hemosiderin pigment (fig. 240).

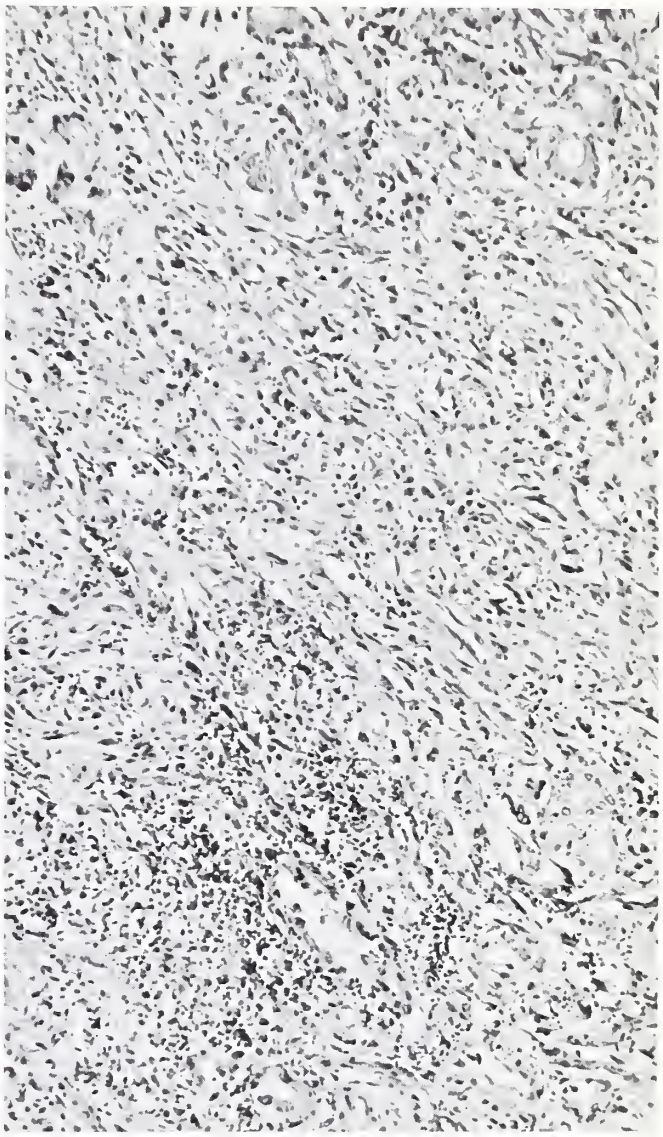

Fig 240

KAPOSI'S DISEASE

This is a photomicrograph of one of several slightly raised and hemorrhagic mucosal lesions of the stomach in a patient with disseminated Kaposi's disease. It is composed of vascular tissue, with interstitial cellular fibrous elements and focal hemorrhage. × 160. (Courtesy of Beth Israel Hospital, Boston, Mass.)

References

Appelman, H. D., and Helwig, E. B. Glomus tumors of the stomach. Cancer 23:203–213, 1969.

Bongiovi, J. J., Jr., and Duffy, J. L. Gastric hemangioma associated with upper gastrointestinal bleeding. Arch. Surg. 95:93–98, 1967.

Byrne, J. J. Kaposi's sarcoma. New Eng. J. Med. 266: 337 – 338, 1962.

Chodack, P., and Hurwitz, A. Lymphangiectasis of stomach simulating polypoid neoplasm. Arch. Intern. Med. 113: 225 – 229, 1964.

Ernst, C. B., Abell, M. R., and Kahn, D. R. Malignant hemangiopericytoma of the stomach. Surgery 58:351 – 356, 1965.

Helwig, E. B., and Ranier, A. Inflammatory fibroid polyps of the stomach. Surg. Gynec. Obstet. 96:355 – 367, 1953.

Kay, S., Callahan, W. P., Jr., Murray, M. R., Randall, H. T., and Stout, A. P. Glomus tumors of the stomach. Cancer 4:726 – 736, 1951.

Kerekes, E. S. Gastric hemangioma: A case report. Radiology 82:468 – 469, 1964.

Marangos, G. N. Haemangiopericytoma of the stomach. Gut 6:77 – 79, 1965.

Palmer, E. D. Benign intramural tumors of the stomach: a review with special reference to gross pathology. Medicine 30: 81 – 181, 1951.

Richey, L. E., Jr., and Cooley, R. N. Kaposi's sarcoma the radiographic manifestations of involvement of the stomach. Gastroenterology 44:195 – 198, 1963.

Stout, A. P. Tumors of the Stomach. Fascicle 21, Atlas of Tumor Pathology. Washington: Armed Forces Institute of Pathology, 1953.

Thyssen, J. Haemangioma of the stomach. A cause of ulcer and of gastric haemorrhage. Acta Chir. Scand. Suppl. 343:227 – 233, 1965.

Toker, C. Glomangioma. An ultrastructural study. Cancer 23: 487 – 492, 1969.

Weitzner, S. Glomus tumor of the stomach. Report of a case and review of the literature. Amer. J. Gastroent. 51:322 – 328, 1969.

TUMORS AND TUMOR-LIKE LESIONS OF ADIPOSE TISSUE

LIPOMA*

Lipoma of the stomach is usually a submucosal tumor located primarily in the distal portion of the stomach (fig. 241). Turkington found 157 cases in the literature with the patients' ages ranging from 29 to 83 years. The tumor was submucosal in 95 percent and subserosal in 5 percent of cases. Most of the tumors were sessile; a few were pedunculated. Ulceration of the covering mucosa resulted in hemorrhage in 53 percent, and symptoms of obstruction appeared in 33 percent of cases reported by Chodoff and DeLeon. The average diameter of the tumor measured 5 cm. Roentgenogram may at times reveal the radiolucent aspects of the tumor (Culver and Toffolo). Microscopically, lipomas are composed of well differentiated adipose tissue. Rarely, the cells may be less differentiated with round eccentric nuclei and a myxomatous appearance (figs. 242, 243). The term **lipoblastoma** may be applied to a tumor containing such areas.

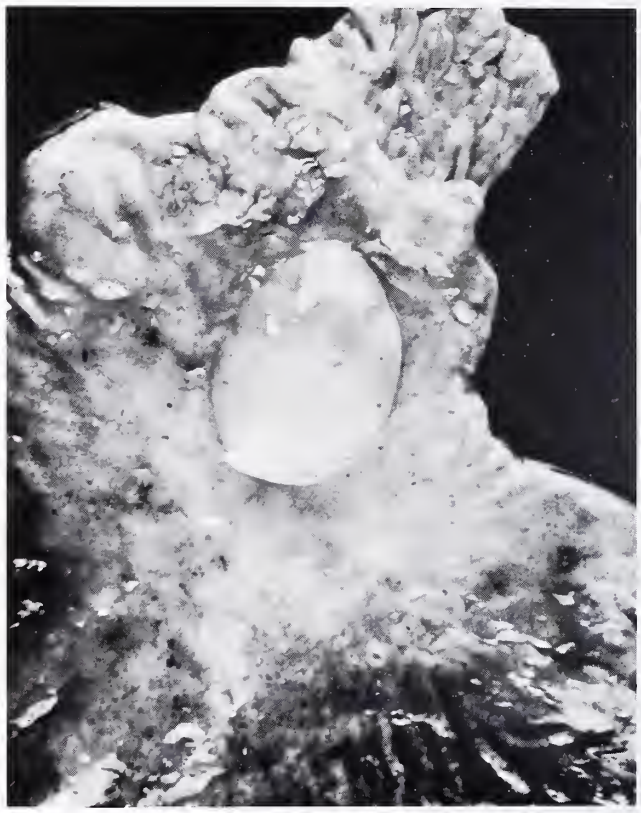

Fig. 241

LIPOMA

This oval submucosal nodule in the gastric antrum is composed of mature adipose tissue covered by intact mucosa. (Courtesy of Beth Israel Hospital, Boston, Mass.)

MYXOMATOUS LIPOMA

(Figures 242 and 243 from same case)

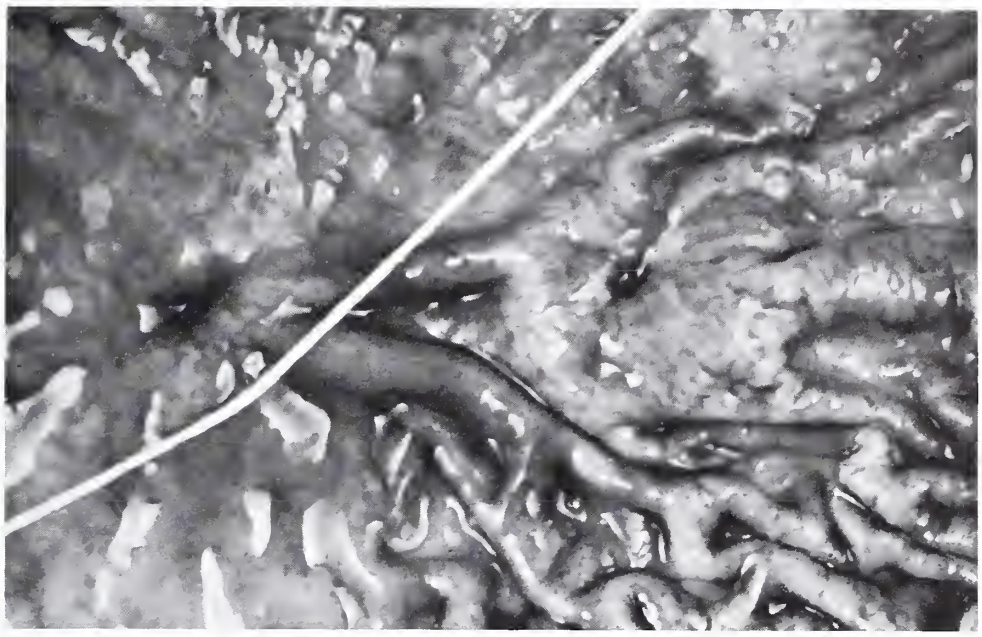

Fig 242

A 48-year-old woman had a subtotal gastrectomy for the gastric ulcer shown on the left of the white line A freely movable, yellow, 2 4 x 2 4 x 1 0 cm submucosal lesion is about 1 5 cm proximal to it, just to the right of center. The center of the raised covering mucosa contains a small ulcer (Courtesy of Beth Israel Hospital, Boston, Mass)

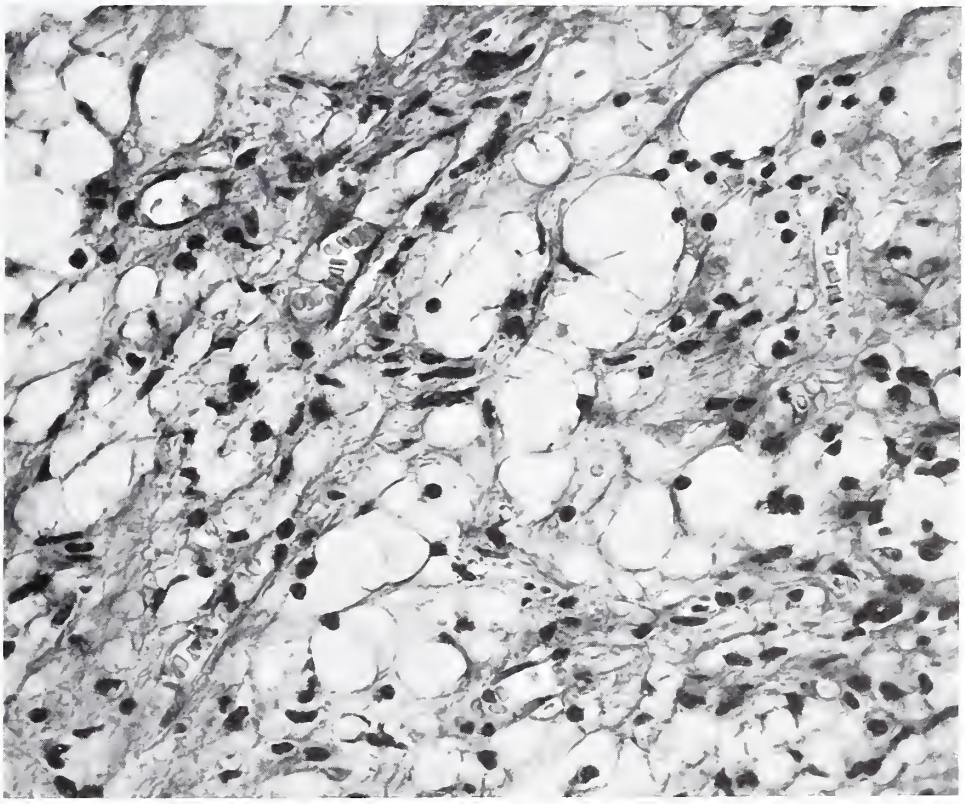

Fig 243

A photomicrograph of the tumor shown in figure 242 reveals well differentiated adipose tissue with myxomatous changes × 350 (Courtesy of Beth Israel Hospital, Boston, Mass)

LIPOSARCOMA*

A few liposarcomas of the stomach have been reported (Abrams and Turberville; Hawkins and Terrell; Hohf et al.). The patients were elderly men. The tumors presented as large infiltrating masses, measuring up to 15 cm. in greatest dimension. The tumor reported by Abrams and Turberville had metastasized to the liver.

XANTHOMA*

The stomach may have focal accumulations of lipid-laden histiocytes in the mucosa resulting in grossly visible yellow patches. These are not neoplasms and are clinically insignificant. Kimura and associates found these lesions in 58 percent of 193 autopsied cases. Halpert and associates reported similar lesions, composed of fibrous tissue mixed with foam cells, in a 38-year-old man. In rare instances, a sizable mass is present (Alerte). Reports are available of nodular histiocytic tumors in the stomach having no foam cells; they were designated **histiocytoma** or **reticuloma** (Chomet et al.). The histologic appearance of such reported tumors resembles leiomyoblastoma, and they may be leiomyoblastomas.

References

Abrams, M. J., and Turberville, J. S. Liposarcoma of the stomach. Report of a case. Southern Surgeon 10: 891–896, 1941.

Alerte, F. Xanthofibroma of the stomach. Report of a case with severe secondary hypochromic anemia. Arch. Path. 75:99 – 104, 1963.

Chodoff, R. J., and DeLeon, A. D. Lipoma of the stomach. Surgery 46:841–844, 1959.

Chomet, B., Martin, G. B., and Gibbel, M. I. Histiocytoma of stomach. Amer. J. Gastroent. 38:653 – 658, 1962.

Culver, G. J., and Toffolo, R. R. Criteria for roentgen diagnosis of submucosal gastric lipoma. Radiology 82: 254 – 257, 1964.

Halpert, B., Györkey, F., and Paulsen, P. F. Xanthomatosis of the stomach. Surgery 39:325 – 328, 1956.

Hawkins, P. E., and Terrell, G. K. Liposarcoma of the stomach. a case report. J.A.M.A. 191:758 – 759, 1965.

Hohf, R. P., Engel, K. L., and Capos, N. J. Liposarcoma of the stomach. Ann. Surg. 142:1029 – 1033, 1955.

Kimura, K., Hiramoto, T., and Buncher, C. R. Gastric xanthelasma. Arch. Path. 87:110 – 117, 1969.

Rooney, J. A., and Guzauskas, A. C. Submucous lipoma of the stomach. Amer. J. Surg. 110:967 – 969, 1965.

Turkington, R. W. Gastric lipoma; report of a case and review of the literature. Amer. J. Dig. Dis. 10:719 – 726, 1965.

TUMORS OF NERVOUS TISSUE

Small **neuromas** have occasionally been seen in an ulcer bed or scar. Patients manifesting diffuse **neurofibromatosis** may also have a tumor in the stomach. Perea and Gregory found 29 such cases in the English literature up to 1962. Some of these tumors appearing in the gastrointestinal tract have been leiomyomas (Lukash et al.). There have been many reported cases of **neurilemomas*** or **schwannomas** in the stomach. Stout pointed out that leiomyoma may be mistakenly diagnosed as neurilemoma, which only rarely occurs in the stomach. Palmer reviewed several reported cases of neurilemoma in which the tumors were chiefly located in the midportion of the stomach. There was great variation in size; a 780 gm. tumor was reported by Warren and Wittman. Gross hemorrhage was the chief manifestation. Nerve tissue tumors containing ganglion cells are rare. Pack encountered one case each of **ganglioneuroma*** and **paraganglioma,** and Tapp reported a case of **ganglioneuroblastoma*** located in the posterior wall of the stomach.

Granular cell tumor (myoblastoma or **schwannoma)** is a tumor of uncertain origin, with evidences strongly in favor of a neural origin (Sobel et al.). It occurs rarely in the stomach. Of 95 cases reviewed by Strong and associates, only one tumor was found in the stomach. Goodman and associates reported one example; the tumor measured 0.9 cm. in greatest dimension. The tumor illustrated by Stout was also small. Schwartz and Gaetz reported a case of multiple submucosal tumors of this type, measuring up to 2.5 cm. in greatest dimension, in the stomach of a 39-year-old Negro man.

References

Goodman, M L, Gottlieb, L S., and Zamcheck, N Granular-cell myoblastoma of the stomach and colon Amer J Dig Dis 7 432 – 441, 1962

Lukash, W M, Morgan, R I, Sennett, C O, and Nielson, O F Gastrointestinal neoplasms in von Recklinghausen's disease. Arch Surg 92 905 – 908, 1966

Pack, G T Unusual tumors of the stomach Ann N Y Acad Sci 114 985 – 1011, 1964

Palmer, E D Benign intramural tumors of the stomach a review with special reference to gross pathology Medicine 30 81 – 181, 1951

Perea, V D, and Gregory, L J, Jr Neurofibromatosis of the stomach Report of a case associated with von Recklinghausen's disease and review of the literature J A M A 182 259 – 263, 1962

Schwartz, D T, and Gaetz, H P Multiple granular cell myoblastomas of the stomach Amer J Clin Path 44 453 – 457, 1965

Sobel, H J, Marquet, E., Avrin, E, and Schwarz, R Granular cell myoblastoma An electron microscopic and cytochemical study illustrating the genesis of granules and aging of myoblastoma cells. Amer J Path 65 59 – 78, 1971

Stout, A P Tumors of the Stomach Fascicle 21, Atlas of Tumor Pathology Washington Armed Forces Institute of Pathology, 1953

Strong, E W, McDivitt, R W, and Brasfield, R D Granular cell myoblastoma Cancer 25 415 – 422, 1970

Tapp, E Ganglioneuroblastoma of the stomach J Path Bact 88 79 – 82, 1964

Warren, K W, and Wittman, C J., Jr Neurilemoma of the stomach appearing as an abdominal mass Report of a case Lahey Clin Found Bull 17 96 – 98, 1968

TUMORS OF FIBROUS TISSUE

Fibrous tissue tumors are extremely rare in the stomach. At the University of Maryland Hospital, there were two **myxofibromas** composed of loosely arranged spindle cells in a markedly myxomatous tissue (fig. 244). Both these tumors appeared in the submucosa of the pyloric antrum and were ulcerated. Shockman and Rosen reported two similar lesions and found reports of six previous cases. Seven of these eight tumors were located in the antrum; they were round, smooth, and measured 3 to 8 cm. in greatest dimension. Five of these lesions were in men and three in women. Palmer reviewed the available information on reported **fibromas***. Most of the tumors were submucosal, spherical or ovoid, and randomly distributed in the stomach. Mucosal ulceration was common. **Fibrosarcoma*** was not encountered in specimens studied by this author. Stout questioned the validity of this diagnosis in the few cases reported; he concluded they were probably leiomyosarcomas.



Fig 244

MYXOFIBROMA

This photomicrograph of an antral lesion in a 64-year-old woman shows loosely arranged, elongated fibroblasts scattered within basophilic acellular material. × 260

References

Palmer, E. D Benign intramural tumors of the stomach a review with special reference to gross pathology Medicine 30.81 – 181, 1951

Shockman, A T., and Rosen, J H Fibromyxoma of the stomach Delaware Med J 37 225 – 228, 1965.

Stout, A P Tumors of the Stomach Fascicle 21, Atlas of Tumor Pathology Washington. Armed Forces Institute of Pathology, 1953

TUMORS OF MIXED TISSUE ORIGIN

TERATOMA*

SYNONYMS AND RELATED TERMS **Benign teratoma**; benign cystic teratoma; dermoid cyst

Teratoma of the stomach has been reported as occurring primarily in male infants and young children. Meadow and DeAngelis each reported one case and collected a total of 13 other cases from the literature. The tumors were large, often described as larger than the stomach itself. In one case, the tumor weighed 1,000 gm. A distended abdomen was evident in many of the patients. The tumor may involve any part of the stomach, but the posterior wall is the favored site. It may project outward into the peritoneal cavity, or into the gastric lumen. Grossly, gastric teratoma is encapsulated; cysts and areas of hemorrhage and calcification are commonly present (fig. 245). Microscopically, many types of tissue have been found, such as skin, respiratory and intestinal epithelia, neuroepithelial tissue, and cartilage (fig. 246). Although the tissue is often immature, successful surgical excision generally results in cure. Cases of dermoid cysts of the stomach have been reported (Love; Palmer; Plachta and Speer); presumably these are teratomas with prominent dermal elements.

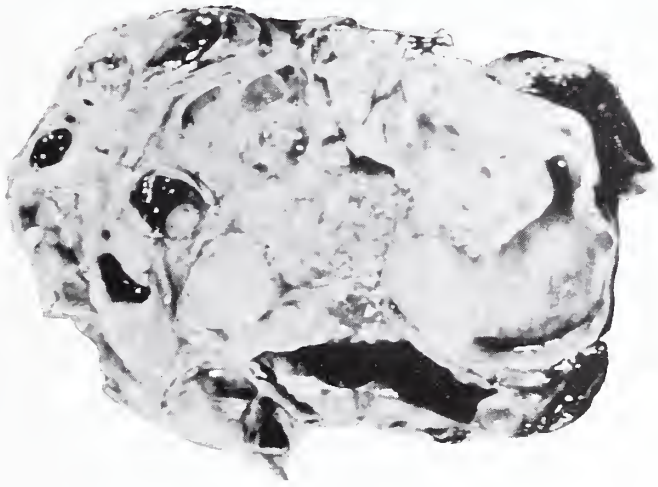

Fig. 245

TERATOMA

(Figures 245 and 246 from same case)

A newborn male had a large mass broadly attached to the posterior wall of the stomach. The entire stomach and the mass were surgically removed. This cut surface of the mass reveals its variegated appearance and cystic areas. (Courtesy of Dr. J. M. Kissane, St. Louis, Mo.)

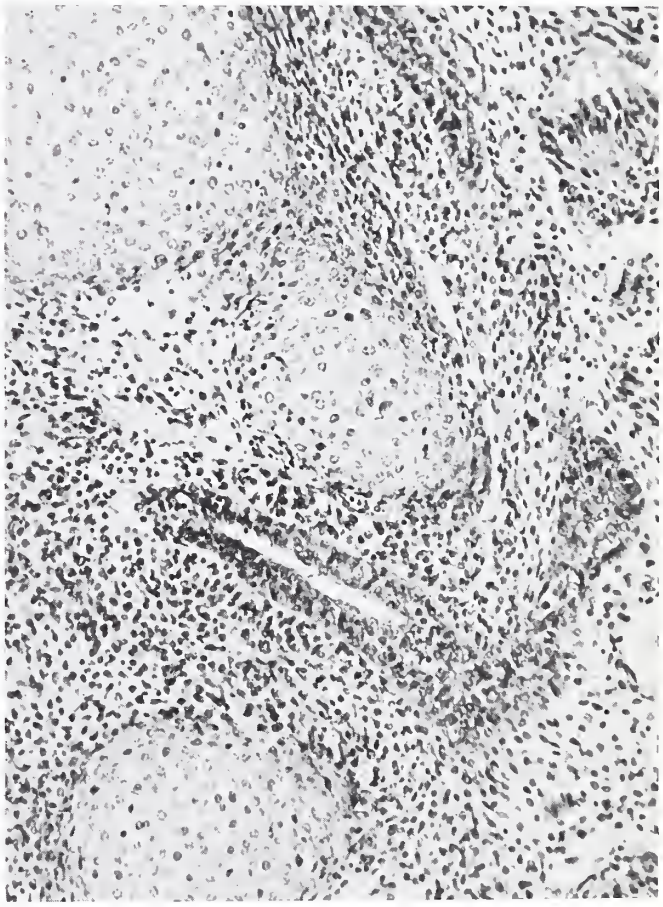

Fig. 246

TERATOMA

(Figures 245 and 246 from same case)

A photomicrograph of a portion of the same tumor shows ductlike structures lined by epithelial tissue, surrounded by immature mesenchymal tissue containing cartilage. Skin, intestinal elements, and neuroepithelial tissue were found in other areas. × 150 (Courtesy of Dr. J. M. Kissane, St. Louis, Mo.)

CARCINOSARCOMA AND COLLISION TUMOR

Carcinosarcoma is composed of both carcinomatous and sarcomatous tissues admixed within the same tumor (fig. 247). The two tissues may have their origin in the totipotential cells capable of differentiating into different tissues, thus resulting in a combination tumor in which the carcinomatous and sarcomatous elements are well mixed and a parenchyma-stroma relationship is roughly maintained. The two tissues may also have originated from different cell lines in the same region either simultaneously or sequentially; the resultant tumor is a composite tumor in which the malignant components are irregularly distributed. Occasionally, two separate tumors may merge or become contiguous. The resultant collision tumor has an admixture of different cell types only at the junction. Stout noted two tumors of the last variety where adenocarcinoma coexisted with rhabdomyosarcoma. Arganaras and Rigdon reported a polypoid sarcoma abutting an ulcerated gastric adenocarcinoma with foci of squamous cells in both areas. Tanimura and Furuta collected 24 reported cases; nine were in women and 15 in men, and most of the tumors were in the pyloric region. Of these 24 tumors, nine were collision tumors, seven combination tumors, six composite tumors, and two of uncertain origin.

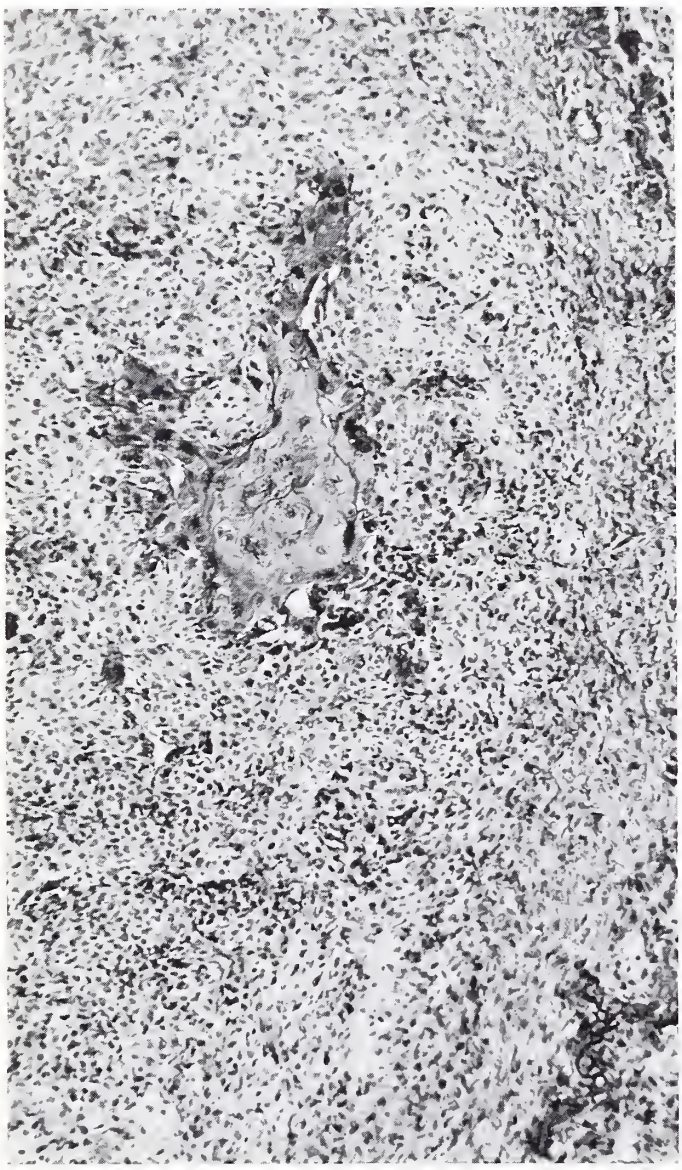

Fig 247

CARCINOSARCOMA

A 10 x 10 x 3 cm. polypoid tumor was removed from the distal part of the stomach of a woman. The center of the tumor was ulcerated. Most of the tumor consisted of a group of squamous carcinoma cells in sarcomatous tissue. Osteoid was present in other areas. × 110. (Courtesy of The Massachusetts General Hospital, Boston, Mass.)

References

Arganaras, E., and Rigdon, R. H. Carcinosarcoma of the stomach. Gastroenterology 44:322–329, 1963.

DeAngelis, V. R. Gastric teratoma in a newborn infant: Total gastrectomy with survival. Surgery 66:794–797, 1969.

Love, R. J. M. Dermoid cyst simulating gastric ulcer. Brit. J. Surg. 18:339–340, 1930.

Meadow, S. R. Gastric teratoma. Postgrad. Med. J. 44: 183–185, 1968.

Palmer, E. D. Benign intramural tumors of the stomach; a review with special reference to gross pathology. Medicine 30:81–181, 1951.

Plachta, A., and Speer, F. D. Gastric polyps and their relationship to carcinoma of the stomach; review of literature and report of 65 cases. Amer. J. Gastroent. 28:160–175, 1957.

Stout, A. P. Tumors of the Stomach. Fascicle 21, Atlas of Tumor Pathology. Washington: Armed Forces Institute of Pathology, 1953.

Tanimura, H., and Furuta, M. Carcinosarcoma of the stomach. Amer. J. Surg. 113:702–709, 1967.

METASTATIC TUMORS IN THE STOMACH

The stomach is rarely the site for metastatic tumors. When generalized lymphomas and leukemias are present, tumorous infiltration may be found in the stomach. Similar observations have been made in disseminated Kaposi's disease and it is possible the tumor in the gastric wall developed *de novo*. Davis and Zollinger reported 67 metastatic tumors in the stomach among 23,019 autopsied cases which included 13 lymphoid tumors, 3 fibrosarcomas, and 51 carcinomas. Higgins found 64 cases of metastatic carcinoma in the stomach among 31,541 autopsied cases. The incidence in both series was 0.2 percent. In these two series, the primary carcinoma was in the lung in 31 cases, breast in 14, pancreas and uterus in 9 each, melanoma in 7 cases, and various other organs in the remainder. Among approximately 14,000 autopsied cases at the University of Maryland Hospital, there were 26 metastatic tumors in the stomach, as follows: primary tumor in the pancreas, 8; in the breast and uterus, 3 each; melanoma, and primary tumor in the lung, kidney, and colon, 2 each; pancreatic islet cell tumor, and primary tumor of ovary, liver, and bile duct, 1 each. The metastatic lesions were usually small (fig. 248) and occasionally formed ulcerated

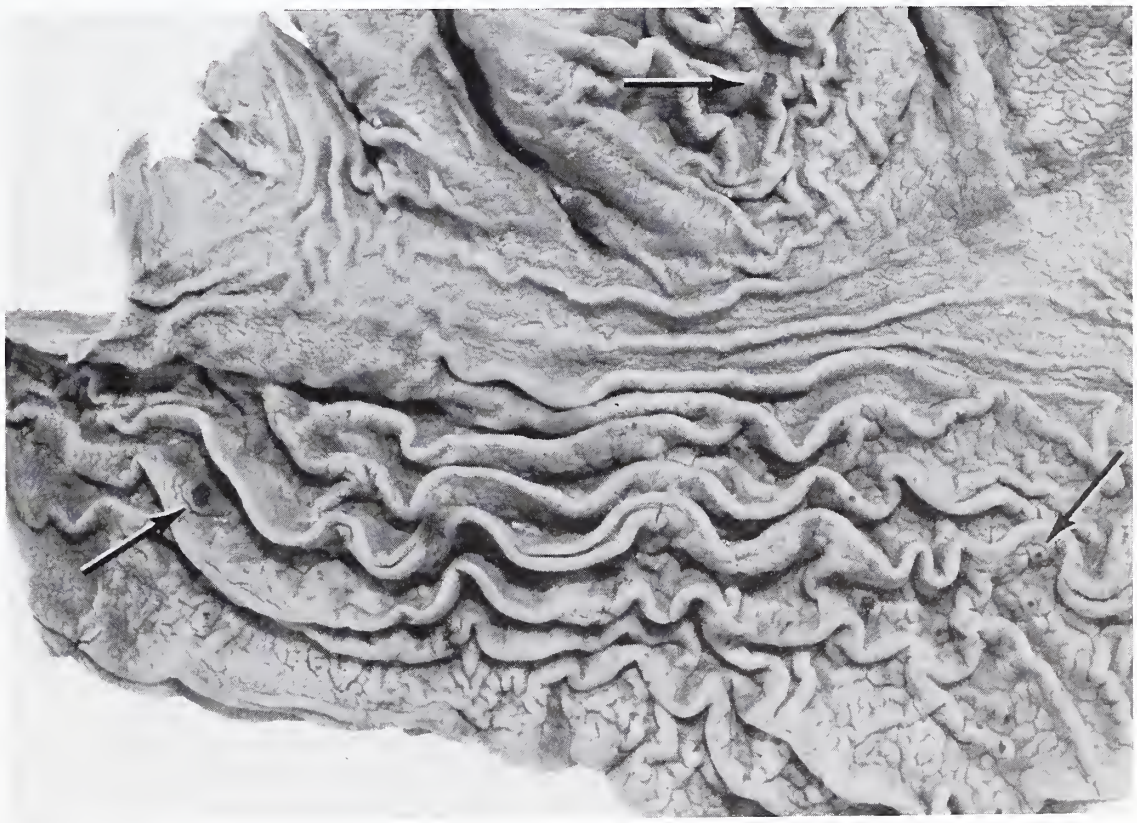

Fig. 248

METASTATIC MELANOMA

A 47-year-old white man had a melanoma of the skin in the left axilla with widespread metastases. The largest of many small, pigmented, metastatic spots in the gastric mucosa measured 5 mm. in diameter, and is shown on the left. Three of the lesions are indicated by arrows.

or polypoid nodules (fig. 250). Microscopically, the metastatic tumor cells were located mainly in the submucosa (fig. 249). When tumor cells were present in the mucosa, the gastric glands were displaced and degenerated, but cellular atypism was not seen (fig. 251). These features serve to differentiate metastatic lesions from primary gastric tumors.

Incidence of gastric metastases from breast carcinoma varied from 8 to 15 percent (Choi et al.; Graham and Goldman; Hartmann and Sherlock). Twenty-one of the 28 cases reported by Choi and associates had gross lesions, six of which showed thickening of the gastric wall that resembled linitis plastica. This feature was also seen in 7 of 11 cases reported by Graham and Goldman. Hartmann and Sherlock noted the high incidence of steroid therapy in patients with gastric metastases, but this aspect was not significant in other reports. In melanoma cases, gastric metastases occurred in about 20 percent; at times, the circumscribed disklike nodule with central ulceration may present a bull's eye appearance on the roentgenogram (Potchen et al.). Gastric metastatic lesions from bronchogenic carcinomas are usually small, but a case with pyloric obstruction was reported by Higgins.

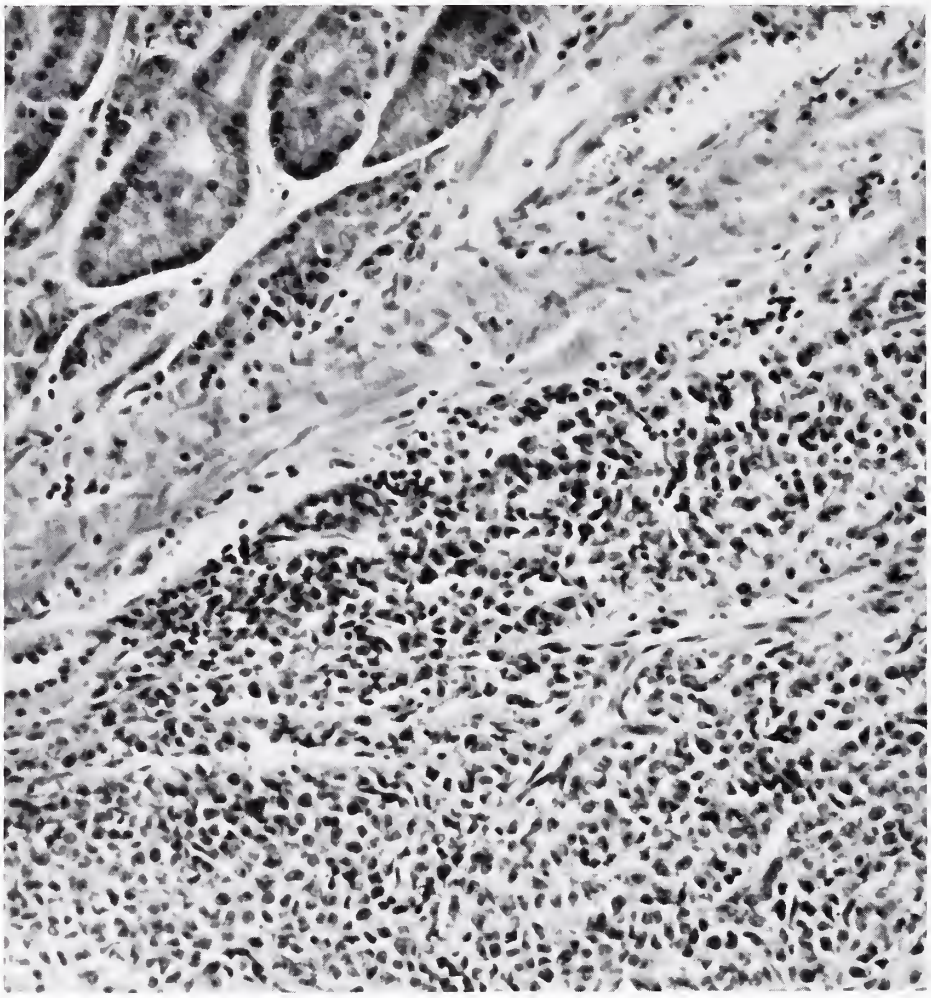

Fig 249

METASTATIC MELANOMA

This is a photomicrograph of an ulcerated nodule in the stomach of a 47-year-old man who had metastatic melanoma from the skin. Melanoma cells lie in the submucosa, and the overlying mucosa is normal. × 168.

Fig 250

METASTATIC RENAL CELL CARCINOMA

A 62-year-old woman had a renal cell carcinoma of the left kidney with widespread metastases Several polypoid, superficially eroded, metastatic nodules are seen in the stomach.

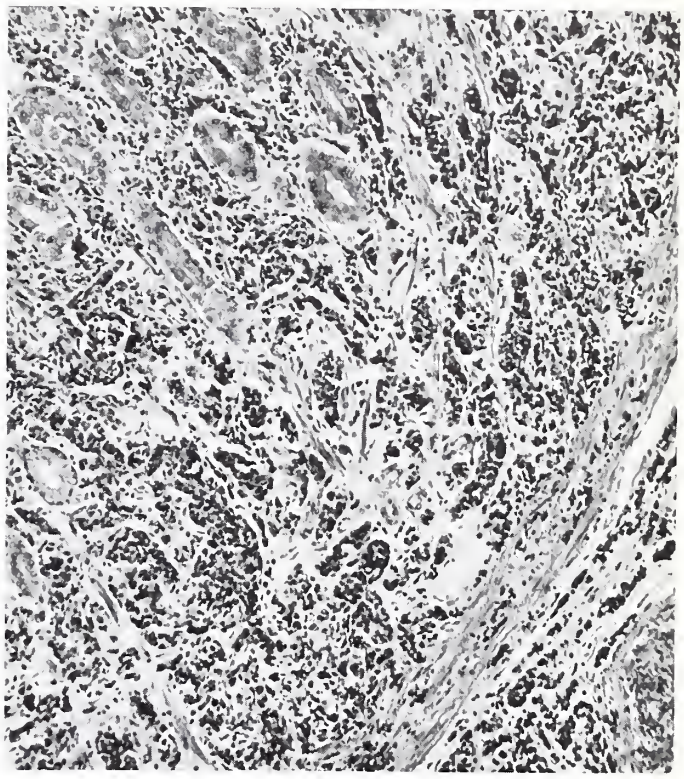

Fig 251

METASTATIC SMALL CELL CARCINOMA OF LUNG

This photomicrograph shows darkly stained nests of metastatic undifferentiated small carcinoma cells from the lung in the lamina propria of the mucosa and in the submucosa (right lower corner). The gastric glands are normal. × 90.

References

Choi, S. H., Sheehan, F. R., and Pickren, J W Metastatic involvement of the stomach by breast cancer Cancer 17 791 – 797, 1964

Davis, G H., and Zollinger, R W Metastatic melanoma of the stomach. Amer J Surg 99 94 – 96, 1960.

Graham, W P, III, and Goldman, L. Gastro-intestinal metastases from carcinoma of the breast Ann. Surg 159 477 – 480, 1964

Hartmann, W H., and Sherlock, P Gastroduodenal metastases from carcinoma of the breast An adrenal steroid-induced phenomenon. Cancer 14 426 – 431, 1961

Higgins, P M. Pyloric obstructions due to a metastatic deposit from carcinoma of the bronchus. Canad J Surg 5 438 – 441, 1962.

Potchen, E J., Khung, C L., and Yatsuhashi, M X-ray diagnosis of gastric melanoma New Eng J Med 271 133 – 136, 1964.

INDEX

Abell, M. R., 104,109
Abrami, G., 23, 123, 124
Abrams, H. L., 63
Abrams, M. J., 248
Abrikossoff's tumor, 73
Abscess formation with carcinoma, incidence, 54
Achalasia
  carcinoma with, 27, 59, 76, 78
  clinical manifestation of gastric carcinoma, 203
  incidence, 27
  invading trachea, **55**
  occurrence, 27
Achlorhydria
  clinical manifestation of gastric carcinoma, 203
  mucosal atrophy, 152
Acland, J. D., 203, 204
Adenoacanthoma, 44, 206, **207**
  definition, 45
  differentiated cells, **46**
  esophagogastric junction, incidence, 47
  stomach, 206, **207**
Adenocarcinoma, 23, 44 – 47, 144 – 206
  esophagus
    columnar epithelium lining esophagus, association with, 27
    differentiation of gastric cardia associated with, **44**
    gastric epithelium in esophagus, association with, 26
    gross characteristics, 44, 48
    incidence with hiatus hernia, 26
    infiltrating, degrees of glandular differentiation and infiltration of chronic inflammatory cells, **46**
    location, 44
    microscopic appearance, 45 – 46, 48 – 51
    mucinous, see Mucinous adenocarcinoma
    mucus producing, 44
    origin, 44
    relationship with hiatus hernia, 23
    subepithelial extension at esophagogastric junction, **49**
  esophagogastric junction, **48, 71**
    differentiated cells and striated border, **50**
    histologic appearance, **49**
    incidence, 47
    penetration of squamous epithelium, **51**
    ulcerated and narrowed lumen, **48**
  papillary, see Papillary adenocarcinoma
  stomach
    alcian blue reaction, **189**
    alkaline phosphatase positive, **191**
    cytologic appearance, **185**
    degrees of gland formation, focal lymphocytic infiltration, and fibrosis, **182**
    epidemiology and geographic incidence, 144 – 145
    etiologic factors, 146 – 147
  experimental, **148 – 149**
    extension to peripancreatic tissue, **149**
    extension to subserosa, **150**
  experimental carcinogenesis, 147 – 151
    effective carcinogens, 147
  gastric, see Gastric adenocarcinoma
  goblet cells, pernicious anemia, **185**
  histogenesis, 157 – 161
  microvilli, elongated terminal webs, and slightly dilated endoplasmic reticulum, **187**
  microvilli forming striated borders, erratic terminal webs, large pale mucin globules, and dilated endoplasmic reticulum in cytoplasm, **186**
  mucosal hyperplasia, age of patient, 153
  papillary at periphery and poorly differentiated in center, **181**
  poorly differentiated with peptic ulceration, **156**
  positive periodic acid-Schiff reaction, **189**
  pyloric area, moderately differentiated tumor cells with perineural and neural invasion, **183**
  rhabdomyosarcoma, associated with, 252
  sclerosing, 144
  tissue factors, local, 151
Adenoid-cystic carcinoma, 47
Adenoma, 22 – 23
  Brunner's gland, see Brunner's gland adenoma
  esophagus
    definition, 22
    incidence, 16, 22
    inflammatory lesion, 22
    location, 17
  papillary, see Papillary adenoma
  stomach
    villous, 125, 131 – 137
Adenomatous hyperplasia
  hamartomatous polyp, Peutz-Jeghers syndrome, **139**
Adenomatous lesions, experimental
  glandular stomach without invasion, 147
Adenomatous polyp
  benign, 125
  incidence, 22
Adenomyoma, 122, 141
  heterotopic pancreas, **122**
Adenosarcoma of esophagus, 76
Adipose tissue tumors
  esophagus, 68 – 72

Adipose tissue tumors–continued
stomach 246 – 248
Adler, R. H., 22, 23
Adrenal, metastasis to, from carcinoma of
esophagus, 56
stomach, 201
Aggregated tumor cells, 182
Ahlbom, H. E., 27
Akuamoa, G., 27
Alaghemand, A., 202, 204
Alerte, F., 248
Alimentary tract, carcinoma, hot and spicy foods, associated with, 25
Allen, M. S., Jr., 72
Allergic granulomatosis
asthma, **104**
chronic inflammation, **105**
coagulative necrosis, **105**
diffusely infiltrative carcinoma, 174
gastrointestinal tract, 104
inflammatory fibrous tissue penetrates thickness of gastric wall into omentum, **104**
lung, 105
peritoneum, 105
spleen, 105
Allergy, eosinophilic gastritis, 104
Allison, P. R., 16
Alopecia, Cronkhite-Canada syndrome, 139
Amyloidosis, renal, clinical manifestation of gastric carcinoma, 203
Anatomy, stomach, gross, 84
Anemia
clinical manifestation of carcinoma, 203
hemolytic, see Hemolytic anemia
inflammatory fibroid polyp, 108
megaloblastic carcinoma, 59
normocytic carcinoma, 59
pernicious, see Pernicious anemia
Angiitis, 105
Angioma, incidence, 16
Angiomyofibroma, 65
Angioneuroma, 73
Angioneuromyoma, 73
Angiosarcoma, 245
perithelial, 245
Angiosarcoma multiplex, 73, 245
Annamunthodo, H., 239
Antrum
Brunner's gland adenoma, 141
carcinoma, incidence, 161
definition, 84
fibrous tissue tumors, 249
lesion development, 101
Aorta
adventitia, invaded by fungating squamous cell carcinoma, **30**
arch, relation to esophagus, 12
carcinoma penetration, **34**
incidence, 55
stomach, **85**
Aortoesophageal fistula, carcinoma, 58
Appelman, H. D., 241, 245
Arganaras, E., 252
Argentaffinoma, 209
Arterial hemangioma, 240
Arterial system, stomach, **85**
Ashley, D. J., 24, 26
Asphyxiation
intraluminal tumors, 16
obstruction of larynx by fibrous polyp, 68
Asthma and eosinophilia, eosinophilic gastritis, 104
Athanasoulis, C. A., 67
Atkins, J. P., 63
Attah, E. B., 16, 17, 21
Auerbach, O., 25, 26
Autopsy
asymptomatic leiomyoma, 65
incidence of benign tumors, 16
Azygous vein, papillary adenocarcinoma, **44**
Azzopardi, J. G., 45, 47, 183, 198

Barrett esophagus, 26
Barrett, N. R., 16, 22, 23, 65, 66
Bartholomew, L. G., 139, 143
Basal cell hyperplasia, see Hyperplasia, basal cells
Basque, G. J., 63
Bauer, J. T., 110
Beard, R. J., 101, 102
Benedict, E. B., 27
Benign adenomatous polyps, 125
Benign cystic teratoma, 251
Benign stricture
carcinoma, 76
esophagogastric junction, **53**
gross features, 53
incidence of carcinoma, 27
marked dilatation of lumen, **53**
ulcerated and lacks an intraluminal mass, **53**

Benign teratoma, 251
Bennington, J. L., 110
Berant, M., 122, 124
Berg, J. W., 142, 143
Bergman, F., 42, 60
Bergmann, M., 47
Berry, G. R., 111,113
Bertalanffy, F. D., 86, 87, 99
Bigelow, N. H., 27
Bile duct primary tumor with metastatic tumor, 253
Black, M. M., 205
Black, W. C., III, 210, 213
Blendis, L. M., 203, 204
Block, G. E., 60
Blood, supply of esophagus, 15
Blood vessel, carcinoma invasion, **200**
  incidence, 200
Body of stomach, definition, 84
Boley, S. J., 138, 143
Bone, metastasis to, from carcinoma of
  esophagus, 56
  stomach, 201
Bongiovi, J. J., Jr., 240, 245
Borrie, J., 67, 72
Borrmann, R., 161, 162, 164, 167, 172, 174, 178
Boswell, J. T., 206, 207
Botha, G. S. M., 11, 16, 83
Bottiglieri, N. G., 58
Botting, A. J., 65, 66
Boyd, D. P., 17, 22, 72, 73
Boyland, E., 25, 26
Bradshaw, E., 26
Bragg, D. G., 205
Brain metastasis from gastric carcinoma, 202
Breast carcinoma
  extension into esophagus, 63
  metastasis to stomach, 253, 254
Bremer, E. H., 143
Bremer, J. L., 123, 124
Brindley, G. V., Jr., 208, 209
Brock, D. P., 239
Bromberg, B. E., 51
Bronchial cyst, see Cyst, bronchial
Bronchus
  metastasis to, from carcinoma of esophagus, 56
  penetration by ulcerative carcinoma of esophagus, 34
  relation to esophagus, 12
Brown, W. G., 117 – 119
Browne, D. C., 102
Brunner's gland adenoma, **141**
  heterotopic adenomatous polyp, **141**
  histologic appearance, 141
  location, 141
Brunner's glands
  and heterotopic pancreas, **120 – 121**
  pancreatic tissue, 120
Burdette, W. J., 25, 26
Burge, J. P., 17, 22, 61, 62
Burkhart, C. R., 108, 109
Burrell, R. J., 25, 26
Busard, J. M., 120, 124
Butler, W. H., 147, 150
Butz, W. C., 117 – 119
Byrne, J. J., 245, 246

Calcification in mucinous carcinoma, clinical manifestation of gastric carcinoma, 203
Callanan, J. G., 75, 76
Camishion, R. C., 67, 68, 76
Cantrell, E. G., 203, 204
Capillary hemangioma, 72, 240
Carcinoid, 209 – 213
  age of patient, 209
  gastric, of Mastomys, **212, 213**
  gastrointestinal tract, incidence, 209
  histologic features, 209
  intestinal metaplasia, mucosa, muscularis mucosae, and submucosa involvement, **211**
  metastases, incidence, 210
  multiple, 209
    found at autopsy, **210**
  peptic ulcer, 210
  size, 210
  stomach, incidence, 82, 209
Carcinoma
  adenoid-cystic, 47
  associated with
    achalasia, 27, 76, 78
    columnar epithelium lining esophagus, 78
    hot and spicy foods, 25
    malnutrition, 25
    mucosal hyperplasia, **153 – 154**
  benign stenosis, 78
  benign stricture, 76
  benign tumor, differential diagnosis, 52 – 54
  clinical aspects
    age and sex, 202

Carcinoma – continued
clinical manifestations and diagnosis, 203
clinical findings, 58 – 59
coexisting with hyperplastic adenomatous polyp, 127
concomitant mesodermal tumor, 75
death rate according to sex and age, **59**
diagnosis, 60
diffusely infiltrative, see Diffusely infiltrative carcinoma
direct extension, percentage of cases involving neighboring organs, **57**
distribution of metastases of esophageal carcinoma, 56
epidemiology and geographic incidence, 23
epidermoid, 30
epithelial hyperplasia, 28
esophageal
associated conditions, 26 – 27
associated with other organs, 51
death rate, **24**
etiologic factors, 24 – 25
tylosis, 24
esophagogastric junction, 47 – 51
etiologic factors
alcoholic intake, 25
food, 25
genetic factors, 24
socioeconomic status, 25
tobacco, 25
experimental, 28
fungating, see Fungating carcinoma
gastric, see Gastric carcinoma
gastric ulcer, incidence, 155
gastritis, 81
hiatus hernia, 76, 78
incidence, 253
incidence with benign stricture, 27
increased incidence in presence of hiatus hernia, 26
infiltrating, 34 – 36
definition, 34
stenosis of lumen, 34
infiltrating stenotic, differentiated from benign strictures, 53
in situ
associated with
carcinosarcoma, 37
Plummer – Vinson syndrome, 37
pseudosarcoma, 37
in foveolae, **159**
in resected esophagus, 37
intraepithelial
formation of papillary projections, **42**
present with pseudosarcoma, **79**
invading trachea, **55**
invasive, metaplastic glands, **160**
involvement of esophagus, 34
leiomyoblastoma, differentiation, 221
leiomyosarcoma, 75
lipoma, 76
local extension, 56
location and size, 161 – 162
lymphatic spread, **43**
lymph node metastases, incidence, 54
metaplastic glands, **160**
metastasis and local extension according to level, 58
mucoepidermoid, see Mucoepidermoid carcinoma
multicentric, see Multicentric carcinoma
multiple, 51
fungating and ulcerated, **52**
incidence, 51
multiple and recurrent, 208 – 209
papillary adenoma, **138**
papilloma formation, 28
Plummer-Vinson syndrome, 27
Paterson-Kelly syndrome, 27
polypoid, see Polypoid carcinoma
primary
distribution similarities in various countries, 29
sites, 29
types, 29
pylorus, characteristic uniform cells and vessels of glomus tumor, **243**
recurrent, **208**
relationship to epithelial polyps, 142
renal cell, see Renal cell carcinoma
scirrhous, 144
secondary involvement in esophagus, 63
signet ring cell, see Signet ring cell carcinoma
spread, 200 – 202
complications, 54 – 58
duodenum, 200
location, 200
squamous cell, see Squamous cell carcinoma
stomach, incidence, 82
submucosal extension, **43**
superficial, see Superficial carcinoma
treatment and prognosis, 61 – 62
tylosis, 27
ulcerated, infiltration into paraesophageal tissue, **43**
ulcerated infiltrative, see Ulcerated infiltrative carcinoma
ulcerative, see Ulcerative carcinoma
undifferentiated, see Undifferentiated carcinoma

Carcinoma – continued
verrucous, 34
with peptic ulceration, **155**
poorly differentiated adenocarcinoma, **156**
Carcinoma sarcomatodes, 76
Carcinoma simplex, 183
Carcinoma solidum, 183
Carcinosarcoma, 252
cartilaginous and osteoid tissue, **79**
histologic appearance, 76
incidence, 76
in situ carcinoma, 37
polypoid, **71**
squamous cells of atypical fusiform cells of fibrous tissue nature, **78**
with ulcerated mucosal surface, **77**
polypoid, ulcerated, squamous carcinoma cells in sarcomatous tissue, **252**
pseudosarcoma, 76
differentiation, 79
resemblance to polypoid pseudosarcoma, **80**
sarcoma, differential diagnosis, 52
Cardia
carcinoma, incidence, 161
definition, 84
Cardiac glands, 81
carcinoma development, 23
composed of mucous and serous cells, **14**
covered by squamous epithelium, **13**
definition, 11, 85 – 86
with intestinal metaplasia, **14**
Carey, L. C., 59
Cartilage, cricoid, relation to esophagus, 12
teratoma, 251
Cassel, M. A., 20, 22
Cavernous hemangioma, 72, 240
Cavernous lymphangioma, 72
Central nervous system, metastases to, from carcinoma of esophagus, 56
Chodack, P., 246
Chodoff, R. J., 246, 248
Choi, S. H., 254, 255
Chomet, B., 248
Choriocarcinoma, 47, 207
Chorioepithelioma, 207
Chorionepithelioma, 207
Chronic gastritis, absence in early stages of experimental carcinogenesis, 148
Chronic hyperplastic gastritis, 115
histologic types, 115
large rugae with normal mucosa, **115**
Churg, J., 104, 109
Chusid, E. L., 153, 154
Citrin, Y., 117, 119
Clark, D. E., 72
Clarke, B. E., 122, 124
Coetzee, T., 29, 30
Cohen, N. N., 203, 204
Collins, W. T., 162, 178, 198
Collision tumor, 252
Colon
carcinoma invasion, incidence, 200
hamartomatous polyp, incidence, 139
primary carcinoma with metastatic tumor, 253
villous adenomas, papillary adenoma, 131
Comfort, M. W., 201, 202
Connective tissue, periesophageal, fungating squamous cell carcinoma penetration, **32**
Connor, T. B., 202
Crohn's disease
granulomas, 110
incidence, 110
Cronkhite-Canada syndrome, polyposis and ectodermal changes, 139
Crowder, B. L., II, 210, 213
Cullingworth, C. T., 202, 204
Culver, G. J., 246, 248
Cylindroma, 44, 47
Cyst
bronchial, **20 – 21**
definition, 20
interior showing mucus content and smooth lining, **21**
in upper mediastinum, **20 – 21**
lined by ciliated epithelium with underlying muscularis, **21**
location, 20
dermoid, 251
developmental origin, 20 – 21
duplication, 123 – 124
age of patient, 123
definition, 20
differentiate from inclusion cyst, 20
gastric mucosa and thick muscularis, **123**
lined by columnar cells, **124**
location, 20, 123
origin, 123
enteric duplication, location, 20
enterogenous, incidence in stomach, 82
esophageal, definition, 20
gastric

Cyst – continued
definition, 20
location, 20
occurrence of peptic ulceration, 21
incidence, 16
inclusion, 19
differentiate from duplication cyst, 20
location, 19
location, 17
retention, **19**
chronic inflammation, **19**
Cystic lymphangioma, 72
Cystic teratoma, benign, 251

Davidson, J. S., 62
Davis, G. H., 253, 255
Davis, W. McA., 44, 47
DeAngelis, V. R., 251, 252
Dedichen, H., 125, 143
De la Pava, S., 37, 42, 63
DeMarco, A. R., 37, 42, 80
DeMuth, W. E., Jr., 67, 68
Dermoid cyst, 251
Diaphragm, metastasis to, from carcinoma of esophagus, 56
Dickson, J. A., 20, 22
Dieter, R. A., Jr., 68, 72
Dietrich, R. A., 47, 51, 56, 58, 60
Diffusely infiltrative carcinoma, 174 – 178
gastric ulcer, stenosis of pylorus, **175**
indurated stomach, penetration of serosa into omentum, **177**
superficially eroded mucosa, **176**
thickened submucosa, penetration through muscularis, **176**
Diverticulum
epiphrenic, squamous cell carcinoma, 30
intestinal, duplication cyst, 20
leiomyoma, 65
pulsion, squamous cell carcinoma, 27
Doctor, V. M., 61, 62
Dodge, O. G., 45 – 47, 51, 52
Donald, K. J., 206, 207
Dormanns, E., 55, 56, 58
Druckrey, H., 28, 147, 148, 150
Dungal, N., 146
Duodenal ulcer
glomus tumor, uniform cells with round nuclei and thin-walled vascular spaces, **243**
heterotopic pancreas, Brunner's glands, and islets of Langerhans, **120**
Duodenum
Brunner's gland adenomas, 141
carcinoma invasion, incidence, 200
eosinophilic gastritis, 104
mucosal thickening and rigidity, 117
Du Plessis, L. S., 25, 26
Duplication cyst, see Cyst, duplication
Dysphagia
carcinoma, 58
extramural tumors, 16
incidence of benign tumors, 16
intraluminal tumors, 16
intramural tumors, 16
leiomyoma, 65
lymphoma, 75
occurrence of benign tumors and, 16
paraesophageal tumors, 16
Dysplasia
foveolar and surface epithelium, **157**
in association with invasive carcinoma, origin of esophageal carcinoma, 51
metaplastic epithelium, **158**
Dysplastic foveolar cells, cytologic appearance, **158**

Ectopic pancreas, 141
Eker, R., 161, 178, 198, 205
Eklöf, O., 99, 102
Eklund, A. E., 152, 202 – 204
Ellis, F. H., Jr., 29, 30, 44, 47
Embryo
congenital and acquired abnormalities, 11, 12
development of esophagus, 11
development of stomach, 83
Embryonal rhabdomyoblastoma, 73
Ende, N., 67, 68
Endocrine glands, Zollinger-Ellison syndrome, 116 – 117, **118 – 119**
Engle, R. L., Jr., 110
Ennuyer, A., 75
Enterogenous cyst, stomach, incidence, 82
Entwistle, C. C., 27, 37, 43
Eosinophilia and asthma, eosinophilic gastritis, 104
Eosinophilic gastritis, 102 – 109
asthma and eosinophilia, 104
definition, 103
diffusely infiltrative carcinoma, 174
duodenum, 104
incidence, 104

Eosinophilic gastritis – continued
jejunum, 104
location, 104
massive infiltration of eosinophilic leukocytes, **103**
pyloric antrum, **189**
Eosinophilic granuloma, 102 – 109
stomach, frequency of histologic diagnoses, 101
Epithelial polyp
benign, 124 – 125
relationship to carcinoma, 142
Epithelial tumors, malignant, 144 – 213
Epithelioma, squamous cell, 30
Epithelium
acquired columnar or glandular
associated hiatus hernia, 12
resulting from overgrowth of cardiac mucosa, 12
appearance in esophagus, 12
benign tumors, 22, 23
columnar
adenocarcinoma, 27
carcinoma, 78
esophageal lining, 26
lower esophagus, **13**
congenital columnar and glandular, retention, 12
gastric, adenocarcinoma, 26
involvement of squamous cell carcinoma, **37**
malignant tumors, 23 – 63
normal squamous, contiguous intraepithelial carcinoma, **38**
respiratory and intestinal, teratoma, 251
squamous, papillary adenocarcinoma, **44**
stratified columnar, **13**
stratified squamous, normal esophagus, **13**
surface, mucus-secreting, **13**
Ernst, C. B., 245, 246
Esophageal cyst, see Cyst, esophageal
Esophagitis
associated with hiatus hernia, 26
caused by hernia, 12
overgrowth of cardiac mucosa, acquired columnar or glandular epithelium, 12
Esophagobronchial fistula, carcinoma, incidence, 54
Esophagogastric junction
adenoacanthoma, incidence, 47
adenocarcinoma, **50, 71**
compressed squamous epithelium, **50**
differentiated cells and striated border, **50**
histologic appearance, **49**
incidence, 47
penetration of squamous epithelium, **51**
benign stricture, **53**
carcinoma, 47 – 51
infiltrating adenocarcinoma, **48**
leiomyoma, 65
mucoepidermoid carcinoma, incidence, 47
squamous cell carcinoma, **48**
incidence, 47
subepithelial extension of adenocarcinoma, **49**
Esophagopulmonary fistula
extension of ulcerative carcinoma into lung, **55**
Esophagotracheal fistula
carcinoma, incidence, 54
Esophagotracheobronchial fistula
lymphoma, 75
Esophagus
abnormalities, acquired, 11
adenoacanthoma or mucoepidermoid carcinoma, 45
adenocarcinoma, 44
adenoma, 22
anatomy, 12
carcinoid, 62
carcinoma at the esophagogastric junction, 47
carcinoma involving the esophagus secondarily, 63
carcinosarcoma and pseudosarcoma, 76
choriocarcinoma, 47
concomitant mesodermal tumor and carcinoma, 75
congenital, 11
cylindroma or adenoid-cystic carcinoma, 47
cysts, 19
inclusion cyst, 19
of developmental origin, 20
retention cyst (mucocele), 19
embryology, 11
extramural tumors, 16
fibroma and lipoma, 68
fibrosarcoma, 72
fibrous polyp, 68
glomus tumor, 73
granular cell tumor, 73
hemangioma, 72
intraluminal tumors, 16
intramural tumors, 16
Kaposi's disease, 73
leiomyoma, 65
leiomyosarcoma, 67
lymphangioma, 72
lymphoma, 75
malignant melanoma, 63
multiple carcinomas, 51
neurofibroma, 73

Esophagus – continued
osteochondroma, 75
rhabdomyosarcoma, 67
squamous cell carcinoma, 30
associated conditions, 26
achalasia, 27
benign stricture, 27
esophagus lined by columnar epithelium, 26
fungating carcinoma — verrucous type, 30
hiatus hernia, 26
infiltrating carcinoma, 34
pulsion diverticulum, 27
tylosis and Plummer-Vinson syndrome, 27
ulcerative carcinoma, 34
squamous cell papilloma, 22
Ewing, J., 161
Extramural tumors, dysphagia, 16

Fahimi, H D., 110
Familial polyposis, 125, 138 – 139
incidence, 138 – 139
location, 138
Faris, T D., 111, 113
Fermet, P., 200, 202
Feyrter, F., 99, 102
Fibrinolysis, fatal, clinical manifestation of gastric carcinoma, 203
Fibroleiomyoma, 65
Fibrolipoma, 68
Fibroma, 68, 249
incidence, 16
location, 17
stomach, frequency of histologic diagnoses, 101
Fibromatosis, 68
Fibromyoma, 65
telangiectatic, 65
Fibromyxosarcoma, 72
Fibrosarcoma, 72, 249
incidence, 253
Fibrosarcoma myxomatodes, 72
Fibrosis, differentiating congenital and acquired abnormalities, 12
Fibrous polyp, 68, **71**
histologic appearance, 68
obstruction of larynx, 68
papilloma differences, 22
size, 68
squamous cell carcinoma, **69**, 75, 76
Fibrous tissue tumors, 68 – 72, 249
stomach, incidence, 82
Finby, N., 75
Fistula, see Specific Type
Flege, J. B., Jr., 73, 74
Focal cystic dilatation of glands, hyperplastic mucosa, 116
Foveolar cells, acid mucin, alcian blue, **90**
Foveolar mucous cells, normal, **89**
Fraser, G M., 80
Fraser, R W., Jr., 239
French, W. E., 206, 207
Fridman, E. G., 209
Friesen, G., 161 – 163, 178, 201 – 205
Fundic glands, **15**
definition, 86
Fundic mucosa, intestinal metaplasia, alcian blue, **97**
normal, **86**
periodic acid-Schiff, **97**
Fundus, definition, 84
Fungating carcinoma, 30, 172 – 173
definition, 30
large polypoid mass extending to subserosa and infiltrating plane of gastric wall, **173**
metastases to liver, **174**
ulcerative carcinoma, differential diagnosis, 52

Gall, E A., 231, 239
Ganglioneuroblastoma, 248
Ganglioneuroma, 248
Gans, S. L., 21, 22
Gardner, E. J., 139, 143
Gardner's syndrome, polyps associated with osseous and soft tissue tumors, 138
Garvie, W. H H., 229
Gastric adenocarcinoma, ulcerated, with polypoid sarcoma, 252
Gastric carcinoma
adenoacanthoma, incidence, 206
biologic behavior, 182
classifications, 162 – 177
coexisting with polyp, incidence, 142
death rate, **24, 145**
death rate according to sex and age, **145**
gross appearances, 162, 175
metastases to ovaries, **201**
microscopic appearance, 178 – 199
multicellular, 198
nature of foodstuffs, 146
sequential development of gross patterns, **177**
squamous cell carcinoma, incidence, 206

Gastric carcinoma – continued
treatment and prognosis, 204 – 205
unusual manifestations, 203
Gastric cyst, see Cyst, gastric
Gastric glands, definition, 11
Gastric granulomas, relation to other granulomatous diseases, 110
Gastric lymphosarcoma, pseudolymphoma, 111
Gastric malignancy, experimental, criterion, 147
Gastric mucosa, aminopeptidase, **98**
Gastric sarcoid, incidence, 109
Gastric tumors, benign, incidence, 99
Gastric ulcer, 155 – 157
carcinoma, incidence, 155
myxomatous lipoma, **247**
Gastritis
chronic atrophic, definition, 81
chronic hypertrophic, definition, 81
eosinophilic, see Eosinophilic gastritis
granulomatous, see Granulomatous gastritis
Gastroduodenal artery, stomach, **85**
Gastrointestinal tract
allergic granulomatosis, 104
carcinoid, incidence, 209
malignant lymphoma, incidence, 231
myomas, incidence, 99
Gates, O., 28, 29
Gensler, S., 122, 124
Gentry, R. W., 72, 73
Giberson, R. G., 227, 229
Gilbertsen, V. A., 205
Glands
cardiac, see Cardiac glands
deep mucous, normal esophagus, **13**
endocrine, see Endocrine glands
fundic, see Fundic glands
gastric, see Gastric glands
metaplastic, see Metaplastic glands
mucosal, 81
pyloric, see Pyloric glands
Glandular hyperplasia, Zollinger-Ellison syndrome, **118**
Glandular tumor cell, definition, 182
Glandular type, hyperplastic mucosa, 116
Glass, G. B. J., 86, 99
Glomangioma, 73
Glomus tumor, 73, 241
characteristic uniform cells, carcinoma of pylorus, **243**
duodenal ulcer, uniform cells with round nuclei and thin-walled vascular spaces, **243**
incidence, 241
microscopic appearance, 241
stomach
frequency of histologic diagnoses, 101
location, 241
submucosal, **244**
ulceration, 241
Golby, M., 51, 52
Goldberg, H. I., 122, 124
Goldfarb, W. B., 122, 124
Goldgraber, M. B., 110
Goldman, H., 87, 90, 99, 152, 161, 182, 198
Goldman, R. L., 108, 109
Goldsmith, H. S., 51, 52
Goodman, M. L., 248, 249
Goodner, J. T., 51, 52, 62, 67, 68, 72
Goolden, A. W. G., 72
Gordon, T., 23, 26
Gowing, N. F. C., 66, 72
Graham, S., 146, 147
Graham, W. P., III, 254, 255
Grant, R., 147, 150
Granular cell myoblastoma, 73
Granular cell neurofibroma, 73
Granular cell schwannoma, 73
Granular cell tumor, 73, 248
pseudoepitheliomatous hyperplasia, **74**
small nuclei and abundant cytoplasm, **74**
stomach, frequency of histologic diagnoses, 101
Granular myoblastoma, 73
Granuloma
eosinophilic, see Eosinophilic granuloma
gastric, see Gastric granuloma
Granuloma multiplex hemorrhagicum, 73, 245
Granulomatosis, allergic, see Allergic granulomatosis
Granulomatous diseases, differentiation, 110
Granulomatous gastritis, 109 – 110
intestinal involvement, Crohn's disease, 110
isolated, incidence, 110
Griff, L. C., 65, 66
Griffith, G. W., 144, 146
Grimes, O. F., 73
Grossman, M. I., 85, 99
Guiss, L. W., 152
Gynning, I., 29, 30, 61, 62

Haenszel, W., 23, 26, 144, 146
Halpert, B., 248
Hamartoma, myoepithelial, 122

Hamartomatous polyp, 125, **139 – 140**
location, 139
Peutz-Jeghers syndrome, 139
duodenal polyp, **139**
gastric polyps, **139**
ileal polyp, **139**
jejunal polyp, **139**
Hare, W. V., 147, 148, 150
Hartmann, W. H., 254, 255
Harvey, H. D., 202, 204, 209
Harvey, W. F., 76, 77, 80
Hauge, M., 146, 147
Hawkins, P. E., 248
Hawley, P. R., 205, 206
Heart
and pericardium, metastasis to, from carcinoma of esophagus, 56
carcinoma metastases, incidence, 202
Helwig, E. B., 103, 108, 109, 245, 246
Hemangioendothelioma, 245
Hemangioma, 72, 240
arterial, 240
capillary, 72, 240
cavernous, see Cavernous hemangioma
location, 17
stomach, frequency of histologic diagnoses, 101
venous, see Venous hemangioma
Hemangiopericytic sarcoma, 245
Hemangiopericytoma, 245
reticulum fibers similar to inflammatory fibroid polyp, 108
stomach, frequency of histologic diagnoses, 101
Hemolytic anemia, microangiopathic, clinical manifestation of gastric carcinoma, 203
Hemorrhage
and necrosis
leiomyoblastoma, **230**
plasmacytoma of stomach, **244**
and superficial ulceration
hyperplastic adenomatous polyp, 125
intramural tumors, 16
Kaposi's disease, **245**
leiomyoma, 215, 216
leiomyosarcoma, 224
massive, erosion and ulceration of polypoid lesions, 16
neurilemoma, 248
penetration of ulcerative squamous cell carcinoma into aorta, **34**
result of ulceration, lipoma, 246
Hemorrhagic sarcoma, 73, 245
Hepatic artery, stomach, **85**
Hermann, G., 203, 204
Hernia, hiatus, see Hiatus hernia
Herrold, K. McD., 28, 29
Hess, R., 161, 162, 178
Heterotopic adenomatous polyp, 125, 141
Brunner's gland adenoma, **141**
Heterotopic pancreas
adenomyoma, **122**
and Brunner's glands, **120 – 121**
exocrine pancreatic acini and islet of Langerhans, **121**
location, 141
stomach, incidence, 82
Heterotopic pancreatic tissue
location, 120
stomach
age of patient, 100
incidence, 100
location, 100
size, 100
Heterotopic tissue, 120 – 122
Heterotopic tissue tumor, stomach, frequency of histologic diagnoses, 101
Hewlett, A. W., 44, 47
Hiatus hernia
accompanying acquired columnar or glandular epithelium, 12
acquired short esophagus, 12
associated with esophagitis, 26
carcinoma, 76, 78
increased incidence in presence of carcinoma, 26
relationship with adenocarcinoma, 23
Higgins, P. M., 253 – 255
Hirohata, T., 156
Hirose, F., 147, 150
Histiocytoma, 248
Hitchcock, C. R., 152
Hodgkin's disease
deeply ulcerated with border covered by intact mucosa, **244**
lymphoma, 75
Sternberg-Reed cells, 236, **238**
Hohf, R. P., 248
Hookman, P., 60
Horie, A., 28, 29
Howel-Evans, W., 24, 26
Howes, E. L., 147, 151
Hughes, J. H., 79, 80
Humphrey, C. R., 56, 58
Hunt, T. E., 86, 99

Huppler, E. G., 99, 102
Hurst, E. E., Jr., 26
Hyperpigmentation, skin, Cronkhite-Canada syndrome, 139
Hyperplasia
  adenomatous, see Adenomatous hyperplasia
  basal cell, esophageal cancer, 25
  epithelial, preceding carcinoma, 28
  glandular, see Glandular hyperplasia
  lymphoid, see Lymphoid hyperplasia
  mucosal, see Mucosal hyperplasia
Hyperplastic adenomatous polyp, 125 – 130, **126**, 142
  chronic inflammation, **129 – 130**
  chronic inflammation and fibrosis, **128**
  chronic superficial inflammation, **128**
  coexisting with carcinoma, 127
  cystic dilatation of foveolae, **129**
  focal cystic dilatation, **128**
  gross characteristics, 125
  hemorrhage, 125, **129**
  microscopic characteristics, 127
  regular arrangement of mucous cells, **130**
  rugal folds, **125**
  situated on rugal fold, **127**
  superficial ulceration, 125
  ulcerated, **126**
Hyperplastic gastritis, chronic, see Chronic hyperplastic gastritis
Hyperplastic gastropathy, 115 – 119
  definition, 115
  enlarged rugal folds, **116**
Hyperplastic mucosa, microscopic types, 116
Hypochlorhydria, clinical manifestation of carcinoma, 203
Hypoglycemia, clinical manifestation of gastric carcinoma, 203
Hypokalemic alkalosis, carcinoma, 59
Hypopharynx, carcinoma, extension into upper esophagus, 63
Hypoproteinemia, hyposecretion, 117
Hyposecretion
  achlorhydria or low acidity of gastric juice, 117
  hypoproteinemia, 117

Ihre, B. J., 155, 156
Inberg, M., 205, 206
Inclusion cyst, see Cyst, inclusion
Inferior gastric nodes, stomach, **85**
Infiltrative gastric carcinoma, ulcerated, **230**
Inflammation, chronic
  associated with retention cysts, **19**
  differentiating congenital and acquired abnormalities, 12
  presence in lower esophagus, **13 – 14**
Inflammatory fibroid polyp
  anemia, 108
  definition, 105
  loose stroma with elongated fibroblasts and inflammatory cells, **106**
  perivascular arrangement of elongated fibroblastic cells, **107**
  perivascular reticulum fibers, **108**
  pylorus, configuration of lesion, **106**
Inflammatory fibrous tissue, allergic granulomatosis of stomach wall, **104**
Inflammatory lesion
  adenoma, 22
  simulating tumor, 102
  stomach, incidence, 82
Inflammatory polyp, 124
  stomach, frequency of histologic diagnoses, 101
Inokuchi, K., 205, 206, 209
Interstitial inflammation, hyperplastic mucosa, 116
Intestinal diverticulum, duplication cyst, 20
Intestinal metaplasia, 90 – 99
  absence in early stages of experimental carcinogenesis, 148
  acid mucin in goblet cells, **91**
  and mucosal atrophy, 151 – 153
  carcinoid involvement in mucosa, muscularis mucosae, and submucosa, **211**
  cardiac glands, **14**
  columnar cells, **94**
    microvilli and mitochondria, **93**
  goblet cells
    filled with pale mucin granules, **93**
    prominent endoplasmic reticulum and supranuclear Golgi areas, **93**
  hyperplasia, **95**
  hyperplastic mucosa, 116
  incomplete, **98**
  Kultchitsky cells, 209
  lateral cell membrane, convoluted, interdigitated plication and desmosomes, **94**
  mucin granules, **93**
  multicentric carcinoma, **178**
  relation to carcinoma, 152
  villi and crypt formation, pyloric mucosa, **91**
Intestines, metastasis to, from carcinoma of esophagus, 56
Intraluminal tumors, 16
  asphyxiation, 16
  dysphagia, 16
Intramural tumors, 16

Intramural tumors – continued
dysphagia, 16
hemorrhage, 16
Irons, H. S., Jr., 209
Islets of Langerhans
pancreatic tissue, 120
tumors, Zollinger-Ellison syndrome, 117

Jackson, H., Jr., 75
Jacobs, D. S., 111, 113
Jang, G. C., 72
Jarnun, S., 139, 143
Järvi, O., 152, 161, 182, 198
Jejunum
eosinophilic gastritis, 104
mucosal thickening and rigidity, 117
Johansson, L., 17, 22
Johns, B. A. E., 16
Johnson, A. G., 113
Johnson, F. P., 83
Johnston, J. B., 17, 67, 68
Jordan, G. L., Jr., 156
Joseph, J. I., 231, 236, 239
Just-Viera, J. O., 27

Kamionkowski, M. D., 25, 26
Kaposi's disease, 73, 245
raised and hemorrhagic mucosal lesions, **245**
stomach, incidence, 82
vascular tissue with interstitial cellular fibrous elements and focal hemorrhage, **245**
Kaposi's syndrome, 73
Kay, S., 45, 47, 112, 113, 229, 241, 246
Kenney, F. D., 117, 119
Kerekes, E. S., 240, 246
Kettunen, K., 205, 206
Kidney
carcinoma metastases, incidence, 202
metastasis to, from carcinoma of esophagus, 56
primary carcinoma with metastatic tumor, 253
Kimura, K., 248
Kinnman, J., 27
Kirk, E. G., 83
Kirschenfeld, S., 156
Kolodny, M., 59, 203, 204
Konturek, S. J., 86, 99
Kowalewski, K., 150, 151
Krukenberg tumors
definition, 202
gastric carcinoma with metastases to ovaries, **201**
Kubo, T., 194, 199
Kultchitsky cells, intestinal metaplasia, 209
Kuru, M., 155, 156, 161, 163, 178

Ladd, W. E., 22
Laing, R. R., 110
Landboe-Christensen, E., 84, 99
Lane, N., 78, 80
Langston, H. T., 22
Larynx
carcinoma, extension into upper esophagus, 63
metastasis to, from carcinoma of esophagus, 56
obstruction, fibrous polyp, 68
pseudosarcoma, 78
Lattes, R., 210, 213
Laurén, P., 198, 199
Lawler, M. R., Jr., 62
Leand, P. M., 68, 72
Leborgne, R., 29, 30, 61, 62
Left gastric artery, stomach, **85**
Left gastroepiploic artery, stomach, **85**
Leiomyoblastoma, 219 – 223, **220 – 223, 230**
carcinoma, differentiation, 221
clinical aspects, 223
deep mucosa ulceration, **219**
focal areas of hemorrhage and necrosis, **230**
gastric bleeding, incidence, 223
gross appearance, **219**
nodular appearance and cystic areas with muscle layer invasion, **220**
pleomorphic tumor cells, **221 – 222**
reticulum encircling cells, **221**
ultrastructure, **222**
vascular, **223**
Leiomyoma, 215 – 218
age of patient, 215
annular, **66**
cells with short cytoplasmic processes separated by collagen fibers, **218**
definition, 65
differentiation of neurofibroma, 66
diverticulum, 65
dysphagia, 65
esophagogastric junction, 65
gross characteristics, 215
histologic characteristics, 65 – 66

Leiomyoma – continued
incidence, 16, 65, 215
located at junction of fundic and pyloric mucosa, **215**
location, 17
malignant, 67
mesodermal origin, 65
metastasizing, 67
microscopic appearance, **66**, 216
nodular, **65**
pale, fleshy, cut surface, **215**
polypoid, squamous cell carcinoma, 76
prominent nuclear palisading of elongated cells, **217**
round, sharply circumscribed periphery without fibrous capsule but delineated by compressed smooth muscle, **216**
squamous cell carcinoma 75
stomach
age of patient, 100
frequency of histologic diagnoses, 101
incidence, 82, 99, 100
location, 100
size, 100
tangled bundles of elongated smooth muscle cells, focal areas of hemorrhage and necrosis, **217**

Leiomyosarcoma, 67, 80, 224 – 229
carcinoma, 75
incidence, 208
clinical manifestations, 226
differentiated cells, mitoses, fibrillar material in cytoplasm, **227**
disorganized arrangement, **67**
extension to subserosa, ulcerated mucosa, **226**
focal areas of hemorrhage and necrosis, 224
gross appearance, 67, 224
incidence, 67
intact serosal covering, focally ulcerated mucosa, many cystic areas, **225**
intricate pattern formed by dense reticulum fibers, **229**
invasion of gastric mucosa, **227**
large hyperchromatic nuclei, **67**
location, 224 – 226
metastasis, 67
microscopic appearance, 227
moderate pleomorphism, **67**
mucosa is atrophic, hemorrhagic, and superficially eroded, **224**
polyhedral cells with granular cytoplasm, **228**
roentgenogram, **217**
scattered mitoses, **67**
spindle cells and plump, pleomorphic cells forming swirled bundles, **228**
stomach, incidence, 82
ulceration, **224**
LeRoux, B. T., 61, 62
Lev, R., 183, 199
Lewis, F. T., 20, 22
Lewis, P. L., 123, 124
Li, K. H. 24, 26
Line, D. H., 239
Linitis plastica, 144
Lipoblastoma, 246
Lipoma, 68, 246 – 247
antrum, mature adipose tissue, **246**
carcinoma, 76
incidence, 16, 246
location, 17
microscopic characteristics, 240
myxomatous
differentiated adipose tissue, **247**
gastric ulcer, **247**
pedunculated, 68
invasive squamous cell carcinoma, 76
stomach
age of patient, 100
frequency of histologic diagnoses, 101
incidence, 82, 100
location, 100
size, 100
Liposarcoma, 248
Liver
carcinoma invasion, incidence, 201
leiomyoblastoma, metastases, 223
leiomyosarcoma, metastases, **227**
metastasis to, from carcinoma of esophagus, 56
primary tumor, with metastasis to stomach, 253
Loehr, W. J., 239
Logan, A., 62
Lohrenz, F. N., 59
Long, E. L., 28, 29
Longcope, W. T., 110
Lortat-Jacob, J. L., 47
Loux, H. A., 205, 206
Love, R. J. M., 251, 252
Lu, Y. K., 29, 30, 61, 62, 75, 76
Lukash, W. M., 248, 249
Lumen
dilated, infiltrating squamous cell carcinoma, **36**
marked dilatation, benign stricture, **53**

Lumen, narrowed – continued
adenocarcinoma at esophagogastric junction, **48**
fungating squamous cell carcinoma, **32**
narrowed by intramural growth, ulcerative squamous cell carcinoma, **35**
no serious obstruction, fungating squamous cell carcinoma, **33**
stenosis, infiltrating carcinoma, 34
Lumpkin, W. M., 204, 206
Lung
abscess, extension of ulcerative carcinoma into lung, **55**
allergic granulomatosis, 105
and pleura, metastasis to, from carcinoma of esophagus, 56
carcinoma, extension into esophagus, 63
metastasis to, from carcinoma of stomach, 201
metastatic small cell carcinoma, mucosa and submucosa, **255**
primary carcinoma, with metastasis to stomach, 253
Lützow-Holm, G., 209, 213
Lymphangiectaticum, myofibroma, 65
Lymphangioma, 73, 240
cavernous, see Cavernous lymphangioma
cystic, 73
dilated lymphatics and lymphoid tissue, **241**
simple, 73
stomach, frequency of histologic diagnoses, 101
submucosal, near pylorus, **240**
Lymphatic system, stomach, **85**
Lymphatic vessels, esophagus, 15, 16
Lymph nodes
carcinoma invasion, incidence, 200
cervical, granular cell tumor, 73
containing necrotic tumor, fungating squamous cell carcinoma, **30**
leiomyoblastoma, metastases, 223
lymphoma, incidence, 236
metastasis to, from carcinoma of esophagus, 56
sarcoidosis, **109**
Lymph node metastases
esophageal carcinoma, incidence, 23, 54
gastric carcinoma, incidence, 201
Lymphocytic lymphosarcoma, 231
Lymphoid hyperplasia
benign, 110 – 113
fibrosis, **112**
mature lymphocytes, plasma cells, and histiocytes present, **113**
ulcerated raised lesion, **112**
differentiate from malignant lymphoma, 110
Lymphoid tissue tumors, 231 – 240
Lymphoid tumors, incidence, 253
Lymphoma
and carcinoma, incidence, 208
differentiate from lymphoid hyperplasia, 110
esophagus, 75
histiocytic type
cellular elements, **237**
differentiation from undifferentiated carcinoma, 235
diffuse uniform infiltration throughout gastric wall, **237**
gastric wall infiltration without lymph node involvement, **231**
incidence, 235
large filling defects in upper and midportion of stomach, **234**
large nodules and nodular thickening, **234**
reticulum fibers; large cells with moderate cytoplasm and frequent nucleoli, **238**
three ulcerated lesions; nonulcerated, submucosal nodules, **232**
ulcerated; necrotic nodular mass; submucosal with ulceration of mucosa, **232**
Hodgkin's disease
esophagus, 75
incidence, 235
Sternberg-Reed cells, **238**
lymph node involvement, incidence, 236
lymphoblastic or lymphocytic, incidence, 235
lymphoblastic type
mucosal involvement, **235**
uniform distribution and cellular pattern, **236**
lymphocytic type, ulcerated, with necrosis, **233**
malignant, 231 – 238
classification, 235
development, 231
gross characteristics, 231
histologic appearance, 235
multiple, 231
multiple mucosal and submucosal nodules and plaques, superficial erosion, **230**
stomach, incidence, 82
survival rate, 236
Lymphosarcoma, 231
gastric, see Gastric lymphosarcoma
lymphocytic, see Lymphocytic lymphosarcoma
Lynch, E. C., 203, 204
MacDonald, W. C., 60, 144, 146, 203, 204
Macklin, M. T., 146, 147
Magee, P. N., 28, 29
Magill, T. G., 61, 62

Magnus, H. A., 90, 99
Mahour, G. H., 75
Majima, S., 63, 147, 150, 151, 155, 156, 200, 202
Malabsorption syndrome, carcinoma, 59
Malignant hemangiopericytoma, 245
Mallory, T. B., 155, 156
Malnutrition, associated with esophageal cancer, 25
Marangos, G. N., 245, 246
Marcial, V. A., 29, 30, 61, 62
Marcial-Rojas, R. A., 47, 68, 72, 76
Marshak, R. H., 125, 127, 131, 142, 143
Marshall, S. F., 82, 83, 101, 102
Martin, C., 205, 206
Martin, J. F., 219, 229
Martinez, I., 25, 26
Martini, N., 58, 59
Mason, M. J., 25, 26
Mason, M. K., 156
Mastomys, gastric carcinoid
  cytoplasmic black argyrophilic granules, **213**
  massive infiltration extending from base of mucosa to outer region of muscularis, **212**
Masuda, M., 203, 204
Masuda, Y., 26
McConnell, R. B., 146, 147
McDonald, R. A., 210, 213
McGlashan, N. D., 25, 26
McKechnie, J. C., 47
McKeown, F., 43
McNeer, G., 81 - 83, 99, 100 - 102, 125, 143, 202, 204, 208, 209
McPeak, E., 45, 47, 51
Meadow, S. R., 251, 252
Mediastinitis, carcinoma, incidence, 54
Mediastinum
  posterior position at esophagus, 12
  upper position with esophagus, 12
Medullary carcinoma of stomach, 183
Meissner, W. A., 99, 100, 102, 215, 229
Melanoma
  incidence of gastric metastases, 254
  malignant, 63
  metastatic, see Metastatic melanoma
Ménétrier, P., 115, 119, 153, 154
Ménétrier's disease, 118
  symptoms, 118 - 119
Menzies, G., 83
Merliss, R. R., 146, 147
Mesodermal tumor, concomitant carcinoma, 75
Metaplasia
  intestinal, see Intestinal metaplasia
  pernicious anemia, 90
Metaplastic glands
  carcinoma in situ, **160**
  invasive carcinoma, **160**
Metaplastic mucosa, gastric
  alkaline phosphatase, **95**
Metastasis
  esophageal carcinoma to,
    leiomyosarcoma, 67
    liver, with lymph node involvement, 55
    lung, with lymph node involvement, 55
Metastatic melanoma, skin
  gastric mucosa, **253**
  ulcerated nodule in stomach, **254**
Metastatic tumors, stomach, 253 - 255
  incidence, 253
  microscopic appearance, 254
Meyerowitz, B. R., 34, 43
Michel, J. O., 26, 27
Miller, C., 59, 60
Ming, S.-C., 44, 47, 51, 52, 81, 83, 86, 99, 100, 102, 125, 127, 131, 132, 142, 143, 152, 157, 161, 182, 183, 199
Minielly, J. A., 30, 43
Mitoses, leiomyosarcoma, **67**
Mixed tumor, 76
Mixed type, hyperplastic mucosa, 116
Moeller, D. D., 153, 154
Moersch, H. J., 16, 17, 22, 23
Moertel, C. G., 51, 52, 205, 206, 208, 209
Monaco, A. P., 81, 83, 142, 143
Monafo, W. W., Jr., 162, 178
Moore, T. C., 76, 80
Morgenstern, L., 208, 209
Mori, K., 147, 151
Morphology, histologic, stomach, 84
Morson, B. C., 90, 99, 152
Mosbech, J., 24, 26
Mucinous adenocarcinoma, **186**
Mucocele, see Cysts, retention
Mucoepidermoid carcinoma, 44
  definition, 46
  esophagogastric junction, incidence, 47
Mucosa, aberrant gastric, found in upper esophagus, **15**
Mucosal atrophy
  achlorhydria, 152
  and intestinal metaplasia, 151 - 153
Mucosal glands, 81

Mucosal hyperplasia, 153–154
associated with carcinoma, **153–154**
incidence, 153
Mucosal nodule, 125, 142
Mucous cell hyperplasia
atrophic glands or cystic dilatation, **117**
chronic inflammation and mild fibrosis, **117**
Mucous cell type, hyperplastic mucosa, 116
Mucous producing adenocarcinoma, 144
Multicentric carcinoma, intestinal metaplasia, **178**
Multiple hemorrhagic sarcomatosis, 73
Multiple idiopathic hemorrhagic sarcoma, 73, 245
Murphy, R. T., 117, 119
Muscular tissue tumors, 65 – 80
mesodermal origin, 215–249
Mustard, R. A., 59
Muto, M., 204, 206
Myeloma, multiple, 239
Myoblastic myoma, 73
Myoblastoma, 73, 248
granular cell, see Granular cell myoblastoma
Myoepithelial hamartomas, 122
Myofibroma, 65
Myofibroma lymphangiectaticum, 65
Myoma, 65
gastrointestinal tract, incidence, 99
myoblastic, 73
Myosarcoma, 67
Myxofibroma, 68, 249

Nacklas, M. M., 99
Nagayo, T., 150, 151, 162, 164, 178
Nakamura, K., 198, 199
Nakayama, K., 62
Napalkov, N. P., 28, 29
Naqvi, M. S., 112, 113, 236, 239
Nealon, T. F., Jr., 29, 30
Neck, lower, position of esophagus, 12
Necrosis
and hemorrhage
leiomyoblastoma, **230**
plasmacytoma of stomach, **244**
leiomyoma, 216
leiomyosarcoma, 224
lymphocytic type of lymphoma, **233**
Nelson, R. S., 60
Neoplasm, mucosal folds, 116
Nephrotic syndrome, gastric carcinoma, 203
Nerves, vagus, position with esophagus, 12
Nerve tissue tumor, stomach
age of patient, 100
incidence, 82, 100
location, 100
size, 100
Nervous tissue tumors, 73–74, 248–249
Nese, G., 17, 22
Neurilemoma, 73, 248
Neurinoma, 73
Neuroepithelial tissue teratoma, 251
Neurofibroma, 73
differentiation of leiomyoma, 66
granular cell, see Granular cell neurofibroma
incidence, 16
location, 17
Neurofibromatosis, 248
Neurogenic tumors
incidence, 101
stomach, frequency of histologic diagnoses, 101
Neuromas, 248
Neuromyoarterial glomus tumor, 73
Nicoloff, D. M., 236, 240
Nora, P. F., 72
Nordenstam, H., 101, 102
Nowell, P. C., 147, 151

Obiditsch-Mayer, I., 73, 74
Ochsner, A., 56, 58
Ochsner, S. F., 99, 101, 102
Odashima, S., 147, 151
Oettlé, A. G., 147, 151
O'Gara, R. W., 25, 26
Oi, M., 84, 86, 99
Olansky, S., 140, 143
O'Leary, P. A., 102
Omentum and peritoneum, metastases to, from carcinoma of esophagus, 56
Onychatrophia, Cronkhite-Canada syndrome, 139
Oota, K., 155, 157
Oral cavity, pseudosarcoma, 78
Osteocartilaginous tissue tumors, 75
Osteochondroma, 75
Otto, D. L., 203, 204
Ottoman, R. E., 99, 102
Ovary
carcinoma metastases, incidence, 201

Ovary – continued
gastric carcinoma metastases, **201**
primary tumor, with metastasis to stomach, 253
Ovens, J. M., 75, 76
Oyen, O., 203, 204

Pack, G. T., 248, 249
Paget's disease, coexisting with squamous cell carcinoma, 51
Paile, A., 205, 206
Palmer, E. D., 81, 83, 100–102, 120, 124, 215, 229, 240, 246, 248, 249, 251, 252
Palumbo, L. T., 203, 204
Pancreas
carcinoma metastases, incidence, 201
ectopic, 141
heterotopic, see Heterotopic pancreas
metastasis to, from carcinoma of esophagus, 56
primary carcinoma, with metastasis to stomach, 253
Pancreatic nodes, stomach, **85**
Pancreatic tissue, microscopic features, 120
Papillary adenocarcinoma, **44**, 144
dilated cardiac glands, **45**
fungating carcinoma, intraluminal papillary projections, **184**
histologic appearance, **45**
striated borders at periphery and globules of intracellular and intraluminal mucin, **184**
Papillary adenoma, stomach, 125, 131–137, 142
abrupt transition from normal to neoplastic cells, **135**
gross characteristics, 131–132
illustration of neoplastic cells, **137**
incidence, 131
intestinal metaplasia, **137**
invasive carcinoma, 132
irregular outline, **132**
microscopic characteristics, 132
neoplastic cells continuous with glands, **137**
normal gastric mucosa, **133**
papillary areas separated by deep fissures, **131**
plaquelike carcinoma, **131**
structures at the base, **137**
villous adenomas of colon and rectum, 131
villous pattern, **135**
with carcinoma, **138**
Papilloma
incidence, 16
location, 17
preceding carcinoma, 28
squamous cell
definition, 22
incidence, 22

Paracardiac nodes, stomach, **85**
Paraesophageal tumors, dysphagia, 16
Paraganglioma, 248
Parnell, D. D., 27
Paterson-Kelly syndrome
Plummer-Vinson syndrome, carcinoma, 27
Pattison, J. N., 26, 27
Payson, B. A., 140, 143
Pearson, J. G., 61, 62
Peison, B., 51, 52
Pena, O., 101, 102
Peptic ulcer
carcinoid, 210
similarity to ulcerated tumors, 101
with lymphocytic infiltrations, **111**
Peptic ulceration
carcinoma, **155**
poorly differentiated adenocarcinoma, 156
occurrence with gastric cyst, 21
Perea, V. D., 248, 249
Perforation, free, of gastric carcinoma, 203
Pericardium
and heart, metastasis to, from carcinoma of esophagus, 56
metastasis from gastric carcinoma, 202
Perithelial angiosarcoma, 245
Perithelioma, 245
Perithelioma multiplex, 245
Peritoneum
allergic granulomatosis, 105
and omentum, metastasis to, from carcinoma of esophagus, 56
leiomyoblastoma, metastatic, 223
Pernicious anemia
adenocarcinoma with goblet cells, **185**
metaplasia, 90
mucosal atrophy, achlorhydria, 152
Pestana, C., 209, 213
Peters, P. M., 16
Peutz-Jeghers syndrome
gastrointestinal polyposis, mucocutaneous pigmentation, 138
hamartomatous polyp, 139
duodenal polyp, **139**
gastric polyp, **139**
histologic appearance, 138
hyperplasia of villi, focal cystic dilatation, and normal Brunner's glands, **140**
hypertrophic foveolar cells, normal glands, and narrow bundles of muscle, **140**

Peutz-Jeghers syndrome – continued
ileal polyp, **139**
jejunal polyp, **139**
Piaget, 75
Piccone, V A., 63
Pierce, W S., 27, 28
Pituitary, metastatic gastric carcinoma, 202
Plachta, A., 16, 17, 22, 68, 72, 99–102, 142, 143, 251, 252
Planteydt, H T., 86, 99, 161, 183, 199
Plasmacytoma, 239
extramedullary, 239
extraosseous, 239
plasma cells, mild pleomorphism, **239**
stomach
hemorrhagic and necrotic, **244**
incidence, 82
Pleomorphic-cell sarcoma, 73
Pleomorphism, leiomyosarcoma, **67**
Pleura and lung, metastases to, from carcinoma of esophagus, 56
Plummer-Vinson syndrome
incidence of esophageal cancer, 27
in situ carcinoma, 37
Paterson-Kelly syndrome, 27
Pneumonia, carcinoma, incidence, 54
Polyp
adenomatous, see Adenomatous polyp
epithelial, see Epithelial polyp
esophagus
fibrovascular, 68
incidence, 16
location, 17
fibrous, see Fibrous polyp
hamartomatous, see Hamartomatous polyp
heterotopic adenomatous, see Heterotopic adenomatous polyp
hyperplastic adenomatous, see Hyperplastic adenomatous polyp
inflammatory, see Inflammatory polyp
inflammatory fibroid, see Inflammatory fibroid polyp
stomach
absence in early stages of experimental carcinogenesis, 148
age of patient, 100
coexisting with gastric carcinoma, incidence, 142
definition, 124
frequency of histologic diagnoses, 101
gastritis, 81
histologic characteristics, 124
incidence, 82, 99, 100
location, 100
relationship between malignant potential and size, 142
size, 100
Polypoid carcinoma, 164–166, **165–166**
bronchopneumonia, **166**
Polypoid lesions
erosion and ulceration causing massive hemorrhage, 16
intraluminal tumors, 16
Polyposis, 125
familial, see Familial polyposis
Popoff tumor, 73
Potchen, E J., 254, 255
Prolla, J C., 60, 203, 204
Prostate, metastatic gastric carcinoma, 202
Pseudohyperparathyroidism, carcinoma, 59
Pseudolymphoma, 110–113
gross characteristics, 111
microscopic appearance, 112
Pseudosarcoma
bundles of fusiform cells with scattered bizarre forms, **80**
carcinosarcoma, 76
differentiation, 79
definition, 78
in situ carcinoma, 37
invasion into stalk and adjacent esophageal wall, **79**
larynx, 78
oral cavity, 78
polypoid, resemblance to carcinosarcoma, **80**
presence of intraepithelial carcinoma, **79**
Puestow, C B., 75, 76
Pulsion diverticulum, see Diverticulum, pulsion
Pygott, F., 156, 157
Pyloric glands, 81
aminopeptidase, **98**
definition, 86
Pyloric mucosa
incomplete metaplasia, combined periodic acid-Schiff and alcian blue, **97**
intestinal metaplasia, periodic acid-Schiff, **97**
normal, **87**
parietal cells, **88**
periodic acid-Schiff, **88**
Pylorus
Brunner's gland adenoma, 141
carcinoma
associated with glomus tumor, **243**
incidence, 161
lesion development, 101

Quisenberry, W. G., 144, 146

Rainer, W. G., 67, 68, 76
Raven, R. W., 63
Razi, M. D., 22
Rector, L. E., 16
Rectum
  hamartomatous polyp, incidence, 139
  villous adenomas, papillary adenoma, 131
Reese, D. F., 117, 119
Reeves, E. ,75
Regan, J. F., 207
Rella, A. J., 75, 76
Remigio, P. A., 240
ReMine, W. H., 204–206
Renal cell carcinoma, metastatic to stomach, **255**
Respiratory tract
  compression by extramural tumors, 16
  compression by paraesophageal tumors, 16
Retention cyst, see Cyst, retention
Reticuloma, 248
Reticulum cell sarcoma and carcinoma, incidence, 209
Retroperitoneum, metastatic gastric carcinoma, 201
Rhabdomyoblastoma, 67
  embryonal, 73
Rhabdomyoma, 229
  malignant, 67
Rhabdomyosarcoma, 67, 229
  incidence, 67
  stomach, incidence, 82
  with adenocarcinoma, 252
Richey, L. E., Jr., 246
Right gastric artery, stomach, **85**
Right gastroepiploic artery, stomach, **85**
Ringertz, N., 201, 202
Rintala, A., 140, 143
Rønnov-Jessen, V., 155, 157
Rooney, J. A., 248
Rosato, F. E., 100, 102
Rosenthal, I. I., 104, 109
Rubin, W., 90, 99
Rueff, F., 73
Rugae, with normal mucosa, **115**

Saito, T., 148, 151
Sakornpant, P., 63
Salazar, H., 221, 229
Salm, R., 103, 108, 109
Salmela, H., 229, 236, 240
Salmon, P. R., 103, 104, 109
Sanders, R. J., 209, 210, 213
Saphir, O., 76, 80
Sarcocarcinoma, 76
Sarcoid, gastric, incidence, 109
Sarcoidosis
  diffusely infiltrative carcinoma, 174
  disseminated, incidence, 110
  ulcerative lesion of pyloric antrum, chronic inflammation, **109**
Sarcoma
  carcinosarcoma, differential diagnosis, 52
  hemangiopericytic, 245
  hemorrhagic, 73, 245
  multiple idiopathic, hemorrhagic, 245
  neurogenic, 72
  pleomorphic cell, 73
  polypoid, ulcerated gastric adenocarcinoma, 252
  reticulum cell and carcinoma of stomach, 209
Sarcoma nodulosum cavernosum, 73
Sarcomatosis
  multiple hemorrhagic, 73
  multiple idiopathic, hemorrhagic, 73
Sasano, N., 182, 183, 199
Schindler, R., 81, 83, 115, 119, 153, 154
Schlaeger, R., 117, 119
Schmidt, H. W., 16, 17, 22, 66
Schoental, R., 147, 151
Schottenfeld, D., 209
Schutte, K. H., 28, 29
Schwannomas, 248
  granular cell, see Granular cell schwannoma
Schwartz, D. T., 248, 249
Scirrhous carcinoma, 144
Sclerosing adenocarcinoma, 144
Serlin, O., 205, 206
Sevier, A. C., 213
Shauffer, I. A., 132, 143
Sherrick, D. W., 236, 240
Shiffman, M. A., 138, 143
Shockman, A. T., 249
Short esophagus
  acquired
    associated with hiatus hernia, 12
    development, 12
  congenital
    development, 12

Siegel, J. H., 73
Signet ring cells
definition, 193
Krukenberg tumor, ovary, 202
Signet ring cell carcinoma, 194–195
cytologic appearance, **193**
infiltration of muscularis externa, **197**
mucosa and submucosa involvement only, **199**
mucosa infiltrated by isolated tumor cells throughout gastric wall, **193**
positive reaction of intracellular secretion, **195**
pyloric type glands, **197**
Sigurjonsson, J., 146
Silverstein, M. N., 203, 204
Simple lymphangioma, 72
Sirak, H. D., 109, 110
Siurala, M., 81, 83, 152
Skandalakis, J. E., 227, 229
Skin
sarcoidosis, **109**
teratoma, 251
Small intestine
carcinoma invasion, incidence, 200
hamartomatous polyp, incidence, 139
Smithers, D. W., 26, 28, 51, 52
Smithwick, W., III, 219, 223, 229
Smooth muscle cells, interlacing bundles, leiomyoma, **66**
Snedecor, P. A., 59, 60
Snell, K. C., 147, 151, 210, 213
Sobel, H. J., 73, 74, 248, 249
Soga, J., 210, 213, 240
Solitary nerve sheath tumor
solitary neurofibroma, 73
solitary nerve sheath tumor, 73
Spleen
allergic granulomatosis, 105
carcinoma metastases, incidence, 202
metastasis to, from carcinoma of esophagus, 56
Splenic artery, stomach, **85**
Splenic nodes, stomach, **85**
Squamous cell carcinoma, 23, 30–43, 206
absence of lymph node metastases, 23
after cobalt-60 treatment, **61**
associated with stricture, 27
coexisting with Paget's disease, 51
cytologic appearance, **39**
degenerated keratotic cells, **38**
epiphrenic diverticulum, 30
esophagogastric junction, **48**
incidence, 47
esophagus, carcinogens, 147
experimental, **28**
fibrous polyp, **69**, 75, 76
forestomach, carcinogens, 147
fungating, **30–32**
deep ulceration or less tumor involvement, **33**
filling defects in midportion of esophagus, **33**
in midesophagus, **39**
massive intramural extension and invasion, **32**
nodular mass on external surface, **32**
no serious obstruction of lumen, **33**
penetration to periesophageal connective tissue, **32**
gross, 30–36
hemorrhagic, superficially ulcerated, and necrotic, **31**
histologic appearances, 37–43, **38, 40**
epithelial involvement, 37
keratinization, 37
incidence, 30
infiltrating
circumferential involvement, **35**
dilated lumen, **36**
histologic appearance, 40
restricted superficial ulceration, **36**
stenosis with dilatation, **36**
transmural, **36**
intraepithelial
contiguous normal squamous epithelium, **38**
invasive tumor, **37**
intralymphatic, **43**
invasive, in pedunculated lipoma, 76
leiomyoma, 75
lymph node with necrotic tumor, **30**
nonkeratinizing, histologic appearance, **39**
polypoid excrescences, **31**
polypoid leiomyomas, 76
subepithelial extension, 42
ulcerative, **71**
found in midesophagus, **34**
hemorrhage, **34**
narrowed lumen, **35**
penetration into aorta, **34**
raised borders, **35**
verrucous, 30
papillary pattern, **42**
Stemmer, E. A., 27, 28
Stemmermann, G. N., 152, 153, 161, 182, 183, 199
Stempien, S. J., 117, 119
Stener, B., 37, 43, 76, 80

Stenosis
benign, with carcinoma, 78
with dilatation, by infiltrating squamous cell carcinoma, **36**
Sternberg-Reed cells, Hodgkin's disease, 236, **238**
Stewart, H. L., 147, 148, 151
Stobbe, J. A., 235, 236, 240
Stomach
adenoacanthoma and squamous cell carcinoma, 206
adenocarcinoma, 144
associated lesions, 151
diffusely infiltrative carcinoma, 174
fungating carcinoma, 172
gastric ulcer, 155
mucosal atrophy and intestinal metaplasia, 151
mucosal hyperplasia, 153
polypoid carcinoma, 164
superficial carcinoma, 162
ulcerated infiltrative carcinoma, 167
allergic granulomatosis, 104
anatomy, 83
surface and foveolar cells, 87
benign epithelial polyps, 124
familial polyposis, 138
hamartomatous polyp, 139
Peutz-Jeghers syndrome, 139
heterotopic adenomatous polyp, 141
adenoma of Brunner's glands, 141
heterotopic pancreas, 141
hyperplastic adenomatous polyp, 125
mucosal nodule, 142
papillary adenoma (villous adenoma), 131
relationship of epithelial polyps to carcinoma, 142
benign lymphoid hyperplasia (pseudolymphoma), 110
carcinoid, 209
carcinosarcoma and collision tumor, 252
chorionepithelioma, 207
chronic atrophic gastritis, 81
chronic hypertrophic gastritis, 81
duplication cyst, 123
embryology, 83
eosinophilic gastritis (eosinophilic granuloma), 102
fibroma, 249
fibrosarcoma, 249
ganglioneuroblastoma, 248
ganglioneuroma, 248
glomus tumor, 241
granular cell tumor (myoblastoma or schwannoma), 248
granulomatous gastritis, 109
hemangioma, 240
hemangiopericytoma, 245
heterotopic tissue, 120
adenomyoma, 122
Brunner's glands, 120
heterotopic pancreatic tissue, 120
histiocytoma, 248
hyperplastic gastropathy, 115
Zollinger-Ellison syndrome, 116
inflammatory fibroid polyp, 105
inflammatory lesions simulating tumors, 102
intestinal metaplasia, 90
Kaposi's disease, 245
leiomyoblastoma, 219
leiomyoma, 215
leiomyosarcoma, 224
lipoblastoma, 246
lipoma, 246
liposarcoma, 248
lymphangioma, 240
malignant lymphoma, 231
metastatic tumors in the stomach, 253
multiple and recurrent carcinoma, 208
myxofibroma, 249
neurilemomas, 248
neurofibromatosis, 248
neuromas, 248
paraganglioma, 248
plasmacytoma, 239
reticuloma, 248
rhabdomyoma, 229
rhabdomyosarcoma, 229
schwannomas, 248
syphilis, 102
teratoma, 251
tuberculosis, 102
xanthoma, 248
Stout, A. P., 19, 22, 23, 45, 47, 67, 68, 72, 75, 76, 78, 80, 82, 83, 101, 102, 153, 172, 174, 178, 199, 219, 223, 229, 245, 246, 248, 249, 252
Strassmann, G., 206, 207
Straus, R., 206, 207
Stricture, benign, see Benign stricture
Strong, E. W., 248, 249
Stukonis, M., 146
Sturdy, D. E., 74
Submucosa, stratified squamous epithelium and deep mucous glands, in normal esophagus, **13**
Subpyloric nodes, stomach, **85**
Suckow, E. E., 37, 43, 51, 52

Sugimura, T., 147, 151
Sunderland, D. A., 201, 202
Superficial carcinoma, 162–163
  diffuse glandular carcinoma in pyloric mucosa, **181**
  flat and atrophic mucosa, **163**
  irregular, superficial ulceration, **164**
  normal mucosa, extension into submucosa with superficial erosion and fibrosis, **179**
  poorly differentiated cells, **179**
  subgroups, 163
  ulcer, **163**
Superior gastric nodes, stomach, **85**
Superior pancreaticoduodenal artery, stomach, **85**
Sussman, H. M., 116, 119
Swarts, J. M., 103, 109
Sweet, R. H., 66
Syphilis
  diffusely infiltrative carcinoma, 174
  ulcer, 102
Szogi, S., 206, 207

Tager, I. L., 26, 28
Takayama, T., 200, 202
Talbert, J. L., 76, 80
Tallqvist, G., 229
Tanimura, H., 252
Tapp, E., 248, 249
Taylor, A. L., 90, 99
Teir, H., 86, 99, 157, 161
Telangiectatic fibromyoma, 65
Templeton, A. W., 229
Teratoma, 251
  benign, 251
  cystic, see Cystic teratoma
  distended abdomen, 251
  epithelial tissue surrounded by immature mesenchymal tissue containing cartilage, **251**
  gross characteristics, 251
  microscopic appearance, 251
  stomach, attached to posterior wall, **251**
  variegated appearance and cystic areas, **251**
Thorek, P., 72
Thorsteinsson, T., 146, 147
Thunold, S., 155, 157
Thyroid
  carcinoma, extension into esophagus, 63
  metastasis to, from carcinoma of esophagus, 56
Thyssen, J., 240, 246
Tissue, mixed, tumors, 251–252
Toker, C., 241, 246
Tomasulo, J., 142, 143
Toreson, W. E., 63
Totten, R. S., 17, 66, 68, 72
Trachea
  granular cell tumor, 73
  invaded by carcinoma, **55**
  metastasis to, from carcinoma of esophagus, 56
  position with esophagus, 12
  ulcerative carcinoma, 34
Tracheobronchial tree, carcinoma, incidence, 54
Tuazon, R., 229
Tuberculosis, stomach, incidence, 102
Tuchel, V., 102
Tumor of developmental origin, stomach, frequency of histologic diagnoses, 101
Turkington, R. W., 246, 248
Turnbull, A. D. M., 29, 30, 44, 47
Tylosis
  genetic factors with esophageal carcinoma, 24
  incidence of esophageal cancer, 27

Ulcer
  absence in early stages of experimental carcinogenesis, 148
  duodenal, see Duodenal ulcer
  gastric, see Gastric ulcer
  peptic, see Peptic ulcer
  syphilis, 102
Ulcerated infiltrative carcinoma, **170**
  at junction of antral and fundic mucosa, **172**
  fundic mucosa, **170**
  hemorrhagic and necrotic, **172**
  incidence, 167
  mucosal folds converging on ulcer margins, **168**
  mucosa with cobblestone appearance, **171**
  raised, indurated, puckered, and roughened mucosa, **169**
  ulcer, **167**
  white and light gray tumor tissue, involving mucosa, **171**
Ulcerated tumors, similarity to peptic ulcer, 101
Ulceration
  and hemorrhage, hyperplastic adenomatous polyp, 125–130
  focal, leiomyoma, 215
  with hemorrhage, lipoma, 246
Ulcerative carcinoma
  bronchus, 34
  definition, 34

Ulcerative carcinoma—continued
esophagopulmonary fistula and lung abscess, **55**
fungating carcinoma, differential diagnosis, 52
trachea, 34
Ulcer-cancer, 163
Ulcer-carcinoma, 155
experimental carcinogenesis, 156
Undifferentiated carcinoma, 40
cells with dark staining, irregular nuclei, and indistinct scanty cytoplasm, **41**
cytologic appearance, **192, 198**
histiocytic lymphoma, differentiation, 235
infiltration of muscularis by individual cells and small groups, **41**
no infiltration by individual cells, **191**
smooth cell membranes, no microvilli or mucin granules, **192**
Upton, A. C., 147, 151
Urban, A., 206, 207
Ureles, A. L., 103, 104, 109
Urinary bladder, carcinoma metastases, incidence, 202
Ushigome, S., 37, 43, 51, 52
Uterus
carcinoma metastases, incidence, 201
primary carcinoma with metastatic tumor, 253

Vagus nerves, see Nerves, vagus
Valdes-Dapena, A., 111, 113
Valtonen, E. J., 58, 60
Vaněk, J., 103, 109
Vascular tissue tumors, 72–73, 240–246
stomach
age of patient, 100
incidence, 82, 100
location, 100
size, 100
Viedenheimer, M. C., 203–206
Vein, azygous, papillary adenocarcinoma, **44**
Venous hemangioma, 72
Vilardell, F., 203, 204
Villous adenoma, 125, 131–137
Vinson, P. P., 72, 73
Virchow node, carcinoma invasion, incidence, 201
Voutilainen, A., 29, 30

Walk, L., 131, 143
Wangensteen, O. H., 204, 206
Warren, K. W., 248, 249
Watson, R. R., 66
Watson-Williams, E., 73
Wattenberg, L. W., 161
Weisburger, J. H., 28, 29
Weitzner, S., 22, 23, 241, 246
Welborn, J. K., 203, 204
Welsh, R. A., 216, 229
Whale, H. L., 22
Wilken, B. J., 205, 206
Williams, A. W., 141, 143
Williams, E. R., 75
Williams, J. L., 27, 28
Williams, R. C., Jr., 203, 204
Willis, R. A., 161, 178
Wilson, T. S., 203, 204
Winawer, S. J., 90, 99
Witte, S., 203, 204
Wolf, J. S., 219, 229
Wolfel, D. A., 67, 68
Wood, D. A., 206, 207
Woolf, C. M., 146, 147
Wright, J. T., 58, 60
Wu, Y. K., 43, 60–62
Wynder, E. L., 25–28, 144, 146, 147

Xanthoma, 248

Yaffee, H. S., 138, 143
Yates, D. R., 51, 52
Yonemoto, R. H., 138, 143

Zacho, A., 47, 51
Zollinger, R. M., 117, 119
Zollinger-Ellison syndrome
glandular hyperplasia, **118**
malignant islet cell tumor of pancreas metastasized to gastric mucosa, **119**
tumors of islets of Langerhans, 117

PRINTED BY THE ARMED FORCES INSTITUTE OF PATHOLOGY

DATE DUE

[redacted] LIB DEC 8 1975 5			
[redacted] DEC			
19 1976			
JAN 19 1976			
MAR 5 1980			
GAYLORD			PRINTED IN U.S.A.

LIBRARY
NIH
Amazing Research.
Amazing Help.

http://nihlibrary.nih.gov

10 Center Drive
Bethesda, MD 20892-1150
301-496-1080

NIH LIBRARY
4 0087 8673

NIH LIBRARY
3 1496 00195 0842
FEB 17 1991
JAN 15 1997